

Clinical Article

Postoperative Clinical Outcome and Risk Factors for Poor Outcome of Foraminal and Extraforaminal Lumbar Disc Herniation

Jung Sik Bae, M.D.,¹ Kyung Hee Kang, M.D.,² Jeong Hyun Park, M.D.,¹ Jae Hyeon Lim, M.D.,¹ Il Tae Jang, M.D.¹

Departments of Neurosurgery,¹ Radiology,² Nanoori Hospital, Seoul, Korea

Objective : We evaluated postoperative outcomes in patients who have lumbar foraminal or extraforaminal disc herniation (FELDH) and suggested the risk factors for poor outcomes.

Methods : A total of 234 patients were selected for this study. Pre- and post-operative Visual Analogue Scale (VAS) and Korean version Oswestry Disability Index (KODI) were evaluated and the changes of both score were calculated. Outcome was defined as excellent, good, fair, and poor based on Mcnab classification. The percentage of superior facetectomy was calculated by using the Maro-view 5.4 Picture Archiving Communication System (PACS).

Results : Paramedian lumbar discectomy was performed in 180 patients and combined lumbar discectomy was performed in 54 patients. Paramedian lumbar discectomy group showed better outcome compared with combined discectomy group. *p* value of VAS change was 0.009 and KODI was 0.013. The average percentage of superior facetectomy was 33% (range, 0–79%) and it showed negative correlation with VAS and KODI changes (Pearson coefficient : -0.446 and -0.498, respectively). Excellent or good outcome cases (Group I) were 136 (58.1%) and fair or poor outcome cases (Group II) were 98 (41.9%). The percentage of superior facetectomy was 26.5% at Group I and 42.5% at Group II. There was significant difference in superior facetectomy percentage between Group I and II (*p*=0.000).

Conclusion : This study demonstrated that paramedian lumbar discectomy with preservation of facet joints is an effective and good procedure for FELDH. At least 60% of facet should be preserved for excellent or good outcomes.

Key Words : Far-lateral disc herniation · Paraspinal approach · Double herniation.

INTRODUCTION

There are several types of lumbar disc herniation. The most common type is that protrudes mediolaterally into the spinal canal (intra canalicular type), and others are types of foraminal and extraforaminal disc herniation. Some patients present with combined type of lumbar disc herniation, intra canalicular with foraminal or extraforaminal disc herniation. Foraminal or extraforaminal lumbar disc herniations (FELDH) were first described by Abdullah et al.¹⁾ in 1974. The overall incidence rates of FELDH ranges from 3% to 11%^{7,9)}. The studies about intra canalicular lumbar disc herniation have been performed by many authors, but a few studies about FELDH have been reported. In addition there have been some studies about postoperative outcome for FELDH. Ryang et al.¹⁸⁾ found excellent or

good outcomes in 57% of 48 patients, Donaldson et al.⁶⁾ documented 72%, and Marquardt et al.¹³⁾ presented 94.3% excellent or good outcomes. Until now, many surgical approaches have been introduced for FELDH, they can be classified as total facetectomy with or without fusion, and facet preserving microdiscectomy⁴⁾. Especially, a paramedian microdiscectomy technique permits the direct access to far lateral lesions, minimizing violation of the facet joint²⁰⁾, so paramedian microdiscectomy has been accepted as the most useful technique for FELDH, in case of no preoperative instability. But, even though this technique is minimally invasive approach for far lateral lesions, mostly it requires partial removal of facet which can affect postoperative outcomes. The purpose of this study was to evaluate the postoperative outcomes of FELDH following surgery and identify the radiologic and operative risk factors related with poor outcomes.

• Received : May 12, 2015 • Revised : October 14, 2015 • Accepted : October 14, 2015

• Address for reprints : Il Tae Jang, M.D.

Department of Neurosurgery, Nanoori Hospital, 731 Eonju-ro, Gangnam-gu, Seoul 06048, Korea
Tel : +82-2-3446-9797, Fax : +82-2-3448-0213, E-mail : medmaxx@naver.com

• This is an Open Access article distributed under the terms of the Creative Commons Attribution Non-Commercial License (<http://creativecommons.org/licenses/by-nc/3.0>) which permits unrestricted non-commercial use, distribution, and reproduction in any medium, provided the original work is properly cited.

MATERIALS AND METHODS

The clinical data of patients who underwent operation for FELDH between January 2009 and June 2012 were retrospectively reviewed. The indications for surgery was intractable leg pain resistant to conservative treatment which was confirmed by computed tomogram (CT) and magnetic resonance imaging (MRI) as FELDH. Revision operation, multilevel surgeries, fusion operation, greater than grade I spondylolisthesis, spinal infection, and systemic diseases affecting bone and joint were excluded.

Preoperative evaluations

Based on the chart review, we checked preoperative symptoms, neurologic examination, Visual Analogue Scale (VAS), and Korean version Oswestry Disability Index (K-ODI)¹⁰. Preoperative X-ray image, CT and MRI were obtained from all the patients. To determine the presence/absence of spondylolisthesis and wedging of index level, anterior-posterior and flexion-extension lumbar radiographs were checked.

Postoperative evaluations

Postoperative VAS and KODI were checked. We calculated postoperative change of VAS and KODI which were used to evaluate the risk factors associated with poor outcomes. Subjective satisfaction with the result of operation was classified as excellent, good, fair, and poor based on Macnab classification¹². We reviewed surgical records to assess the type of surgeries (paramedian only or intracanalicular and paraisthmic combined approach) and the occurrence of intraoperative complications. The radiologist hired in our institute reviewed post-operative radiologic images including X-ray and MRI in order to evaluate whether the nerve root had been decompressed completely or not.

Surgical technique

Minimally invasive paramedian approach was used. Incision line was marked at the midpoint of lateral isthmus under fluoroscopic guidance before draping. Following a 3 cm paramedian vertical skin incision, fascia was incised longitudinally. After separation of multifidus and longissimus muscles, we confirmed lateral border of isthmus and self-retaining retractor was applied. Under the surgical microscope, we check lateral facet joint, isthmus and transverse process. To remove inter transverse ligament, superior lateral part of superior facet and upper border of the lower transverse process were drilled out. In the case of L5–S1 level, drilling the lateral border of isthmus was needed at L5 level to open the inter transverse and foraminal ligaments because the L5 isthmus was so wide that it covered intervertebral foramen entirely. But we tried to preserve isthmus more than 5 mm, not to cause post-surgical spondylolysis as mentioned by MacNab¹².

After removal of inter transverse and foraminal ligament, we checked the upper pedicle and confirmed the exiting nerve root lying just beneath the pedicle. Typically, the nerve root was dis-

placed cranially by the herniated disc. During the removal of herniated disc by pituitary forceps, we did not use nerve root retractor to avoid injury of the dorsal root ganglion. In the case of double disc herniation (combination of intracanalicular disc herniation at the same level), intracanalicular discectomy was performed simultaneously.

Revision surgeries

We investigated the causes of revision surgeries and duration between first operation and revision surgeries. Types of revision surgeries were classified through chart review and postoperative radiologic study. The disc herniation of contralateral side at the previous operation level was also included in the indication for revision surgery.

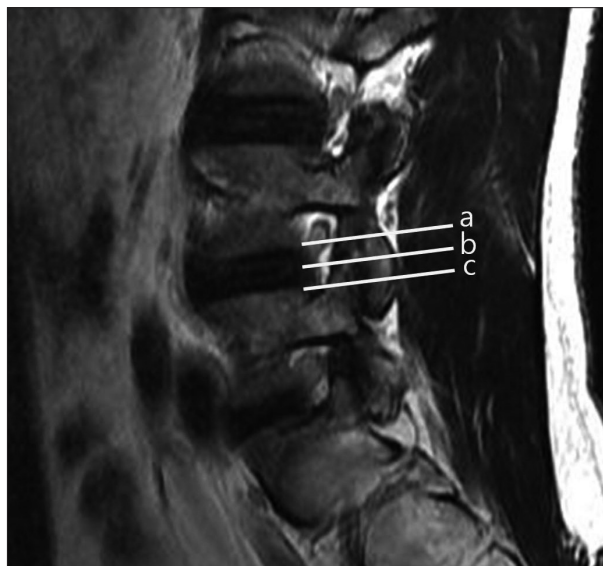


Fig. 1. Cross sectional areas of facet joint were check between three lines (a : upper endplate, b : disc space, c : lower endplate).

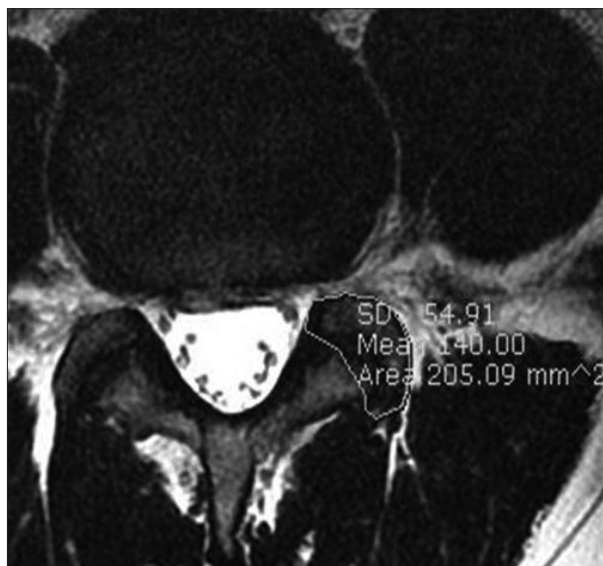


Fig. 2. The calculation tool of cross sectional area of the facet joint.

Facetectomy

To remove inter transverse ligament and open intervertebral foramen, partial resection of superior lateral aspect of facet joint was needed, generally. But too large resection of facet joint can cause severe disc space narrowing and segmental instability resulting in poor outcome. We surveyed the percentage of facetectomy using Maro-view 5.4 Picture Archiving Communication System (PACS) and analyzed correlation between the amount of facetectomy and poor outcome. We measured cross sectional area of facet between 3 lines (lower endplate of upper vertebra body, disc space, and upper endplate of lower vertebra body) (Fig. 1, 2). The sum of three cross sectional area of facet was calculated and the differences between pre and post-operative total facet cross sectional area were defined as the percentage of facetectomy.

Statistical analysis

The statistical analyses were conducted using SPSS 12.0 for Windows (SPSS Inc., Chicago, IL, USA). Student's t-test and Pearson correlation coefficients values were calculated. Null hypotheses of no difference were rejected if *p*-value were less than 0.05.

RESULTS

A total of 234 patients were included in this study. The patients' group was composed of 96 (41%) males and 138 (59%) females. The mean age of patients was 61.8 (range, 18–92 year) years old. The number of patients at each level were 4 (1.7%) at L2–3, 23 (9.8%) at L3–4, 86 (36.8%) at L4–5, and 121 (51.7%) at L5–S1. Preoperative total VAS and KODI were 7.5 (range, 2–10) and 30.2% (range, 11–54%). Postoperative VAS and KODI were 3.6 (range, 0–9) and 20.3% (range, 2–52%). The changes of VAS and KODI were 3.9 (-5–10) and 9.9% (-35–44%). Total follow-up period was 33.0 months (range, 11.1–70.0).

Wedging and spondylolisthesis

Fifty patients (21.4%) showed lateral wedging or less than

grade I spondylolisthesis on preoperative radiograph. The changes of VAS and KODI between pre and post operation were 3.6 (range, -3–10) and 7.9% (range, -20–36%) in the lateral wedging or spondylolisthesis group. The rest of them (184 patients, 78.6%) showed no lateral wedging and spondylolisthesis, the changes of VAS and KODI were 4.0 (range, -5–10) and 10.4% (range, -35–44%). There were no significant differences of VAS and KODI postoperative changes between two groups (*p*=0.308 and 0.201, respectively).

Paramedian versus combined discectomy

180 (76.9%) patients were given paramedian discectomy and combined discectomy was performed in 54 (23.1%) patients. It revealed that the changes of VAS and KODI between pre and post-operative surgeries were 4.2 (range, -3–10) and 11.0% (range, -35–40%) respectively in paramedian discectomy group. The combined discectomy group showed that the changes of VAS and KODI were 3.1 (range, -5–10) and 6.3% (-13–44%). There were significant differences of VAS and KODI changes between paramedian and combined discectomy groups (*p*=0.009 and 0.013, respectively). In the paramedian discectomy group, there were 113 (62.8%) patients showing excellent or good outcome and 67 (37.2%) patients showing fair or poor outcome. Among the combined discectomy group, 23 (42.6%) patients showed excellent or good outcome and 31 (57.4%) patients showed fair or poor outcome.

Revision surgeries

Thirteen (5.6%) patients required revision surgeries due to recurrent leg pain. The mean interval between primary and revision surgery was 7.4 months (range, 1–36 months). Revision surgeries were performed at L5–S1 level in 10 (77%) cases and L4–5 level in 3 (23%) cases respectively. The reasons of revision surgeries were recurrent foraminal disc herniation at 6 patients, contralateral disc herniation at 1 patient, foraminal stenosis at 2 patients, and extraforaminal stenosis at 4 patients. The summary of revision cases was described at Table 1.

Table 1. Revision cases

No.	Age/Sex	Level	Reason of revision surgery	Interval for revision (months)	Type of revision surgery
1	50/F	L5–S1	Extraforaminal stenosis	6	Revision decompression
2	62/F	L5–S1	Recurred disc herniation	36	Revision discectomy
3	65/M	L4–5	Recurred disc herniation	2	Revision discectomy
4	72/F	L5–S1	Recurred disc herniation	5	Revision discectomy
5	60/M	L5–S1	Recurred disc herniation	1	Revision discectomy
6	65/M	L5–S1	Extraforaminal stenosis	3	Revision decompression
7	73/F	L5–S1	Extraforaminal stenosis	2	Revision decompression
8	60/M	L5–S1	Recurred disc herniation at controlateral side	9	Discectomy
9	47/M	L5–S1	Extraforaminal stenosis	4	Revision decompression
10	51/F	L4–5	Foraminal stenosis	16	Fusion surgery
11	70/M	L5–S1	Foraminal stenosis	2	Revision decompression
12	59/M	L5–S1	Recurred disc herniation	9	Revision discectomy
13	51/F	L4–5	Recurred disc herniation	1	Revision discectomy

Facetectomy

The mean percentage of facetectomy was 33% (range, 0–79%). It showed negative correlation with VAS and KODI changes (Pearson coefficient with VAS change : -0.446, $p=0.000$ and KODI change : -0.498, $p=0.000$). The more facetectomy was done, the worse outcomes were presented.

Outcomes

The outcomes were measured by using Macnab criteria¹²⁾, which contains considerations of primarily back pain and radicular pain, activity as major variables, and neurologic deficits. Of the 234 patients, there were excellent outcomes in 22 (9.4%) patients, good in 114 (48.7%), fair in 46 (19.7%), and poor in 52 (22.2%) patients respectively in this study. According to the levels, there were excellent or good outcomes in 3 (75%) of 4 patients at L2–3 level, in 15 (65.2%) of 23 at L2–3 level, in 56 (65.1%) of 86 at L4–5 level, and in 64 (52.9%) of 121 at L5–S1 level respectively. Total 136 (58.1%) of 234 patients presented excellent or good postoperative outcomes. The group with excellent or good outcomes revealed that their mean percentage of facetectomy was 26.5%. Otherwise, the mean percentage of facetectomy was 42.5% in the group with fair or poor outcomes. There was significant difference in facetectomy percentage between the two groups ($p=0.000$).

DISCUSSION

FELDH is a rather uncommon pathology of nerve root entrapment in which the incidence ranges from 1 to 10%^{2,6,8,10,17)}. The radicular pain caused by FELDH is frightfully severe and sometimes even excruciating. More often than not, some patients should use wheelchairs for hospital visits. This striking feature is caused by a direct compression of dorsal root ganglion. Weinstein²²⁾ has described the dorsal root ganglion as the brain of the spinal motion segment. Important sensory synapse and many chemical mediators of pain lie within the ganglion. Many patients with FELDH can't bear weight on the affected limb, making you consider hip or pelvic fracture, otherwise coughing and sneezing do not often increase the pain because the lesion lies beyond the nerve root sheath⁵⁾. To further confuse the clinical presentation, patients often present inguinal pain. It is because that disc herniation lies close to the psoas, causing referred inguinal pain¹⁴⁾.

There are various surgical approaches to the excision of FELDH such as traditional interlaminar midline approaches with hemilaminectomy, the midline submuscular dissection expanded to go lateral to the pars interarticularis, the paraspinal/paraisthmic (paramedian) approach, the posterolateral approach, the retroperitoneal approach and endoscopic approach¹⁴⁾. The paramedian approach has been used in our patients. This approach is safer and more minimally invasive than other procedures. Although it is minimally invasive method, during the procedure partial facetectomy is needed especially at L4–5, L5–S1 levels. Exces-

sive facetectomy can cause segmental instability and asymmetrical disc space collapse, leading to postoperative foraminal stenosis and recurrent disc herniation. Lots of authors mentioned that 50% of the facet joint had to remain as a minimum requirement for segmental stabilization^{4,7)}. Our data showed that negative correlation between the amount of facetectomy and clinical outcomes. In addition, the mean percentage of facetectomy was 42.5% in the group with fair and poor outcomes. These results mean that at least 60% of facet joint should be preserved during the operation for FELDH. To the best of our knowledge, it is the first paper to propose the acceptable percentage of facetectomy by method for calculating cross sectional area of facet joint.

Intracanalicular approach combined with paraisthmic approach was effective for double disc herniation and bony foraminal stenosis^{3,9,11)}. The incidence of double disc herniation was 23% in this study. It was slightly higher rate than that of other studies^{2,4)}. There would be high possibility of excessive facetectomy which can cause poor outcomes in the combined approach. Chang et al.⁴⁾ presented that the patients with double disc herniation were almost three times more likely to have remaining or recurrent leg pain. In our cases, intracanalicular approach combined with paraisthmic approach showed poor outcome, also. The reason for poor outcome was that combined discectomy made greater facet and annular removal which could cause segmental instability and disc space collapse, even we tried to preserve the isthmus at least 5 mm, not to cause post-surgical spondylolysis as mentioned by MacNab¹²⁾. And the things which we included less than grade I spondylolisthesis and lateral wedging cases could be the another reason for the poor outcome, even these conditions didn't show statistical significance.

In our several combined disc herniation patients who were not included in present study, we performed posterolateral side approach to preserve facet and lateral isthmus as much as possible. This approach started with skin incision which was about

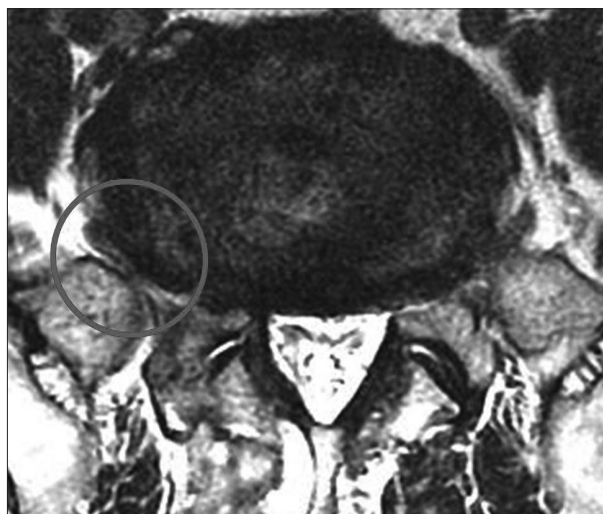


Fig. 3. Right L5 nerve root was impinged between alar transverse process and laterally bulged disc.

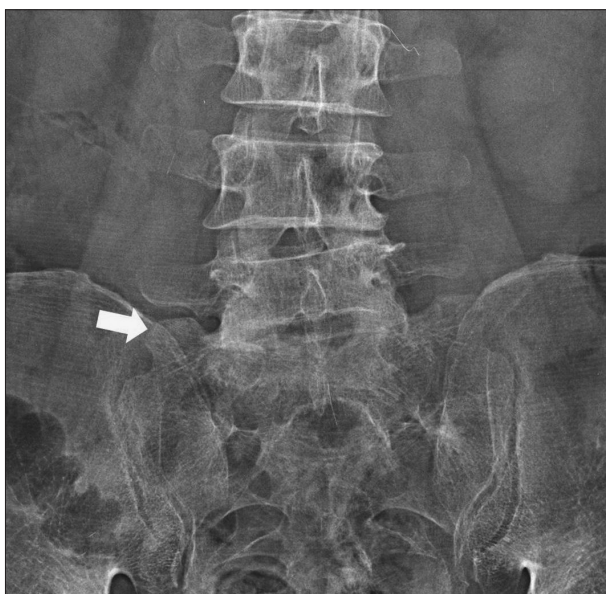

Fig. 4. Highly-lying ala transverse process (arrow).

7 cm off the midline and we approached the foraminal area with about 30 degree inclination to see foramen directly without removal of facet and lateral isthmus, especially in L4-5 and L5-S1 levels. Through this approach, we have gotten good results in current several cases. Of course we have to stipulate the usefulness and validity of posterolateral approach, we just suggest this approach can be one of ways to preserve facet and lateral isthmus.

In our series, there were thirteen (5.6%) revision surgeries at L4-5 (23%) and L5-S1 (76%) levels. These results were comparable to those of other studies^{5,13,16}. Among the L5-S1 group, 4 (36%) cases showed extraforaminal stenosis. The cause of extraforaminal stenosis at L5-S1 level was L5 nerve root impingement between ala transverse process and extraforaminal bulged disc (Fig. 3). After the discectomy of foraminal lesion, disc height collapsed and lateral side disc bulged simultaneously. And the ala transverse process, especially superior lateral part, in these patients was found to be larger than those of other levels, so L5 nerve root was compressed easily (Fig. 4). This means that enough partial removal of alar transverse process is needed when we perform the operation for FELDH at L5-S1 level in order to prevent the postoperative extraforaminal stenosis. So we recommend that foraminal or coronal view MRI of L5-S1 level should be checked preoperatively to predict the possibility of L5 nerve root impingement between bulged disc and alar transverse process (Fig. 5).

Our series showed excellent or good outcomes in 58.1% patients. Otherwise, previous studies presented higher rates of excellent or good outcomes compared to our series^{4,6,13,16,18,19,21}. This reason was assumed that in our patients' group, there was higher rate of combined discectomy (23%) causing poor outcome and the mean age of the patients in this study was relatively older than those of the patients in previous studies.

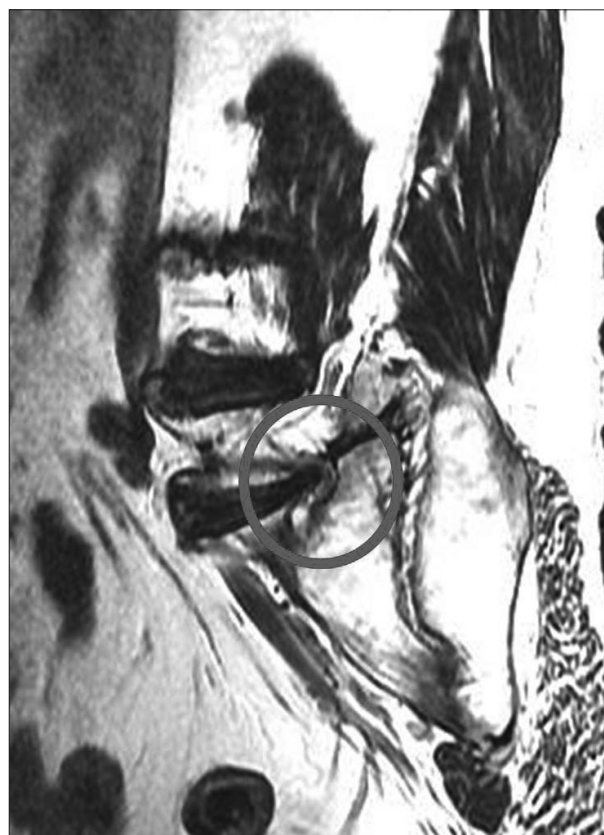

Fig. 5. Foraminal view MRI of L5-S1 right side.

There were some limitations. This was a retrospective study, so the level of evidence was low. And other factors, such as body mass index, occupations, smoking and alcoholic histories, affecting the outcomes were not evaluated. These factors should have been controlled for more statistically meaningful results. In the aspect of facetectomy percentage, we used cross sectional areas. But this method was not based on volumetric calculation. So, there could be a slight differences between our calculation results and real values.

CONCLUSION

Facet preserving minimally paramedian lumbar discectomy is an effective and good procedure for FELDH. At least 60% of facet should be preserved for excellent or good outcomes. Especially in the cases of combined lumbar discectomy, minimal facetectomy is needed. In the future, well controlled prospective randomized studies will be required.

References

1. Abdullah AF, Ditto EW 3rd, Byrd EB, Williams R : Extreme-lateral lumbar disc herniations. Clinical syndrome and special problems of diagnosis. *J Neurosurg* 41 : 229-234, 1974
2. Abdullah AF, Wolber PG, Warfield JR, Gunadi IK : Surgical management of extreme lateral lumbar disc herniations : review of 138 cases. *Neurosurgery* 22 : 648-653, 1988

3. Baba H, Uchida K, Maezawa Y, Furusawa N, Okumura Y, Imura S : Microsurgical nerve root canal widening without fusion for lumbosacral intervertebral foraminal stenosis : technical notes and early results. *Spinal Cord* 34 : 644-650, 1996
4. Chang SB, Lee SH, Ahn Y, Kim JM : Risk factor for unsatisfactory outcome after lumbar foraminal and far lateral microdecompression. *Spine (Phila Pa 1976)* 31 : 1163-1167, 2006
5. Cheng TM, Link MJ, Onofrio BM : Pneumatic nerve root compression : epidural gas in association with lateral disc herniation. Report of two cases. *J Neurosurg* 81 : 453-458, 1994
6. Donaldson WF 3rd, Star MJ, Thorne RP : Surgical treatment for the far lateral herniated lumbar disc. *Spine (Phila Pa 1976)* 18 : 1263-1267, 1993
7. Epstein NE, Epstein JA, Carras R, Hyman RA : Far lateral lumbar disc herniations and associated structural abnormalities. An evaluation in 60 patients of the comparative value of CT, MRI, and myelo-CT in diagnosis and management. *Spine (Phila Pa 1976)* 15 : 534-539, 1990
8. Epstein NE, Epstein JA, Carras R, Hyman RA, Murthy Vish-Nubakat S : Far lateral lumbar disc herniation : diagnosis and surgical management. *Neuroorthopedics* 1 : 37-44, 1986
9. Jenis LG, An HS, Gordin R : Foraminal stenosis of the lumbar spine : a review of 65 surgical cases. *Am J Orthop (Belle Mead NJ)* 30 : 205-211, 2001
10. Kim DY, Lee SH, Lee HY, Lee HJ, Chang SB, Chung SK, et al. : Validation of the Korean version of the Oswestry disability index. *Spine (Phila Pa 1976)* 30 : E123-E127, 2005
11. Kwon YJ : Minimally invasive combined interlaminar and paraisthmic approach for symptomatic lumbar foraminal stenosis : surgical technique and preliminary results. *J Korean Neurosurg Soc* 42 : 11-15, 2007
12. Macnab I : Negative disc exploration. An analysis of the causes of nerve-root involvement in sixty-eight patients. *J Bone Joint Surg Am* 53 : 891-903, 1971
13. Marquardt G, Bruder M, Theuss S, Setzer M, Seifert V : Ultra-long-term outcome of surgically treated far-lateral, extraforaminal lumbar disc herniations : a single-center series. *Eur Spine J* 21 : 660-665, 2012
14. McCulloch JA : *Essentials of spinal microsurgery*. Philadelphia : Lippincott-Raven Publishers, 1998, pp395
15. Novetsky GJ, Berlin L, Epstein AJ, Lobo N, Miller SH : The extraforaminal herniated disk : detection by computed tomography. *AJNR Am J Neuroradiol* 3 : 653-655, 1982
16. Porchet F, Chollet-Bornand A, de Tribolet N : Long-term follow up of patients surgically treated by the far-lateral approach for foraminal and extraforaminal lumbar disc herniations. *J Neurosurg* 90 (1 Suppl) : 59-66, 1999
17. Postacchini F, Montanaro A : Extreme lateral herniations of lumbar disks. *Clin Orthop Relat Res* (138) : 222-227, 1979
18. Ryang YM, Rohde I, Ince A, Oertel MF, Gilsbach JM, Rohde V : Lateral transmuscular or combined interlaminar/paraisthmic approach to lateral lumbar disc herniation? A comparative clinical series of 48 patients. *J Neurol Neurosurg Psychiatry* 76 : 971-976, 2005
19. Siebner HR, Faulhauer K : Frequency and specific surgical management of far lateral lumbar disc herniations. *Acta Neurochir (Wien)* 105 : 124-131, 1990
20. Viswanathan R, Swamy NK, Tobler WD, Greiner AL, Keller JT, Dunksker SB : Extraforaminal lumbar disc herniations : microsurgical anatomy and surgical approach. *J Neurosurg* 96 (2 Suppl) : 206-211, 2002
21. Vogelsang JP, Maier H : Clinical results and surgical technique for the treatment of extreme lateral lumbar disc herniations : the minimally invasive microscopically assisted percutaneous approach. *Zentralbl Neurochir* 69 : 35-39, 2008
22. Weinstein J : Report of the 1985 ISSLS Traveling Fellowship. Mechanisms of spinal pain. The dorsal root ganglion and its role as a mediator of low-back pain. *Spine (Phila Pa 1976)* 11 : 999-1001, 1986