

Three-dimensional assessment of condylar surface changes and remodeling after orthognathic surgery

Jung-Hye Lee¹, Woo-Jin Lee², Jae-Myung Shin³, Kyung-Hoe Huh¹, Won-Jin Yi¹, Min-Suk Heo¹, Sam-Sun Lee¹, Soon-Chul Choi^{1,*}

¹Department of Oral and Maxillofacial Radiology and Dental Research Institute, School of Dentistry, Seoul National University, Seoul, Korea

²Interdisciplinary Program in Radiation, Applied Life Science Major, College of Medicine, and Dental Research Institute, Seoul National University, Seoul, Korea

³Department of Oral and Maxillofacial Surgery, Ilsan Paik Hospital, Inje University College of Medicine, Goyang, Korea

ABSTRACT

Purpose: This study was performed to evaluate condylar surface changes and remodeling after orthognathic surgery using three-dimensional computed tomography (3D CT) imaging, including comparisons between the right and left sides and between the sexes.

Materials and Methods: Forty patients (20 males and 20 females) who underwent multi-detector CT examinations before and after surgery were selected. Three-dimensional images comprising thousands of points on the condylar surface were obtained before and after surgery. For the quantitative assessment of condylar surface changes, point-to-point (preoperative-to-postoperative) distances were calculated using 3D processing software. These point-to-point distances were converted to a color map. In order to evaluate the types of condylar remodeling, the condylar head was divided into six areas (anteromedial, anteromiddle, anterolateral, posteromedial, posteromiddle, and posterolateral areas) and each area was classified into three types of condylar remodeling (bone formation, no change, and bone resorption) based on the color map. Additionally, comparative analyses were performed between the right and left sides and according to sex.

Results: The mean of the average point-to-point distances on condylar surface was 0.11 ± 0.03 mm. Bone resorption occurred more frequently than other types of condylar remodeling, especially in the lateral areas. However, bone formation in the anteromedial area was particularly prominent. No significant difference was found between the right and left condyles, but condylar surface changes in males were significantly larger than in females.

Conclusion: This study revealed that condylar remodeling exhibited a tendency towards bone resorption, especially in the lateral areas. Condylar surface changes occurred, but were small. (*Imaging Sci Dent 2016; 46: 25-31*)

KEY WORDS: Mandibular Condyle; Bone Remodeling; Multidetector Computed Tomography; Imaging, Three-Dimensional

Introduction

Condylar remodeling is a physiological process in which the structure of the temporomandibular joint (TMJ) is adapted to meet functional demands. It is based on an in-

teraction between the mechanical forces sustained by the TMJ and the adaptive capacities of the condyle.^{1,2}

For patients with skeletal Class III deformities, corrective orthognathic surgery improves both oral function and related esthetics.³ The effect of orthognathic surgery on condylar remodeling is a poorly understood and controversial issue.¹ However, orthognathic surgery inevitably results in condylar positional changes.² These positional changes can induce functional stresses in TMJ structures, thereby causing condylar remodeling, and are considered

*This study was supported by grant no. 04-2015-0081 from the SNUDH Research Fund. Received October 12, 2015; Revised November 10, 2015; Accepted November 18, 2015

*Correspondence to : Prof. Soon-Chul Choi
Department of Oral and Maxillofacial Radiology, School of Dentistry, Seoul National University, Daehak-ro 101, Jongno-gu, Seoul 03080, Korea
Tel) 82-2-2072-2622, Fax) 82-2-744-3919, E-mail) raychoi@snu.ac.kr

to be a possible etiology of skeletal relapse following orthognathic surgery.¹

Three-dimensional (3D) imaging has been shown to be effective in examinations and treatment relating to the oral and maxillofacial region.⁴ Several studies have used 3D images to assess condylar remodeling and positional changes after orthognathic surgery.^{2,5,6} Carvalho et al.⁶ used a superimposition technique on 3D imaging and suggested that the condyles tended to move, on average, ≤ 2 mm superoposteriorly after surgery, and this small positional displacement was maintained one year after surgery. An et al.³ also used a 3D image superimposition technique and colored scales to evaluate condylar head deviation before and after orthognathic surgery. They found that condylar surface changes after surgery were significant.

However, few studies have evaluated condylar remodeling according to the area of the condylar head and quantified condylar surface changes. Moreover, no studies have assessed the differences between the right and left condyles and between the sexes.

The purpose of this study was to assess the frequency of remodeling types in each area of the condyles and to analyze condylar surface changes quantitatively using 3D images based on multi-detector computed tomography (MDCT) data. Furthermore, this study compared condylar surface changes and condylar remodeling types between the right and left side and between the sexes.

Materials and Methods

Selection of patients

The present study was approved by the Institutional Ethics Review Board of Seoul National University Dental Hospital (IRB No.CRI15014). This study was a retrospective analysis of patients with skeletal Class III malocclusion who underwent mandibular setback sagittal split ramus osteotomy with Le Fort I osteotomy at Seoul National University Dental Hospital from 2012 to 2015. Patients who had any underlying diseases, facial trauma, or temporomandibular joint disorders were excluded. Ultimately, forty patients (20 males, with a mean age of 21.6 years, and 20 females, with a mean age of 21.0 years) who had undergone 3D MDCT (SOMATOM Sensation 10[®], Siemens, Erlangen, Germany) examinations pre and post-orthognathic surgery were selected. The images were obtained an average of 1.3 months (range, 0.6-2.0 months) prior to surgery and 6.7 months (range, 5.4-13.5 months) after surgery.

Three-dimensional image analysis

Three-dimensional images of mandibular condyles were reconstructed and reformatted into the WRL data format (the file name extension of a Virtual Reality Modeling Language [VRML] file) using 3D imaging software (Vworks[™], version 4.0, Cybermed Inc., Seoul, South Korea). The images were then imported into a 3D data processing program (Geomagic Studio[®] 12, 3D Systems Inc.,

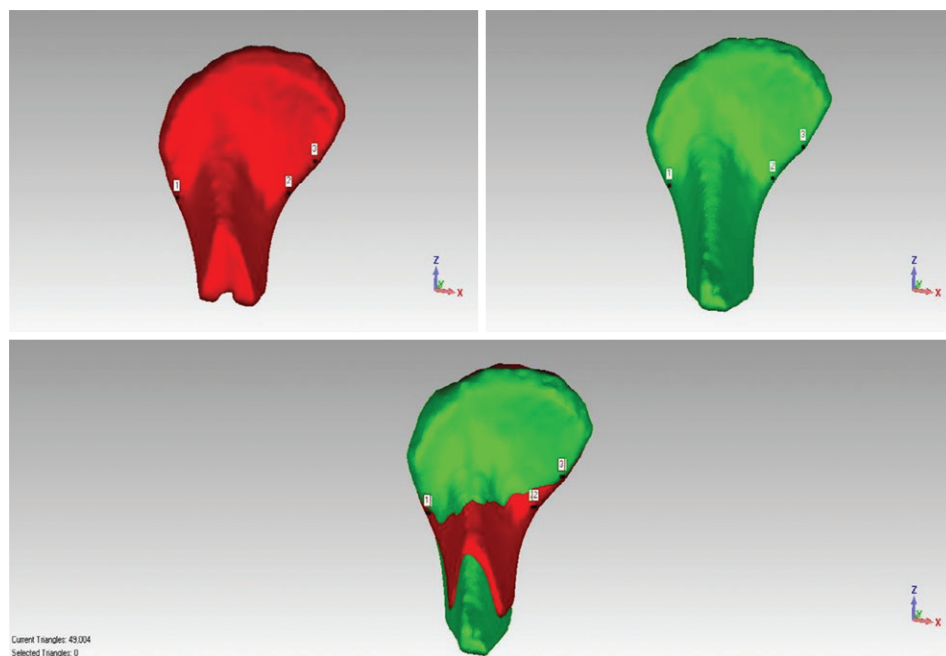


Fig. 1. Superimposition of pre- (upper left) and postoperative segmented images (upper right). These images were superimposed over three prominent registration points around the condylar neck (numbers 1, 2, 3). The registered image (lower part) was generated automatically.

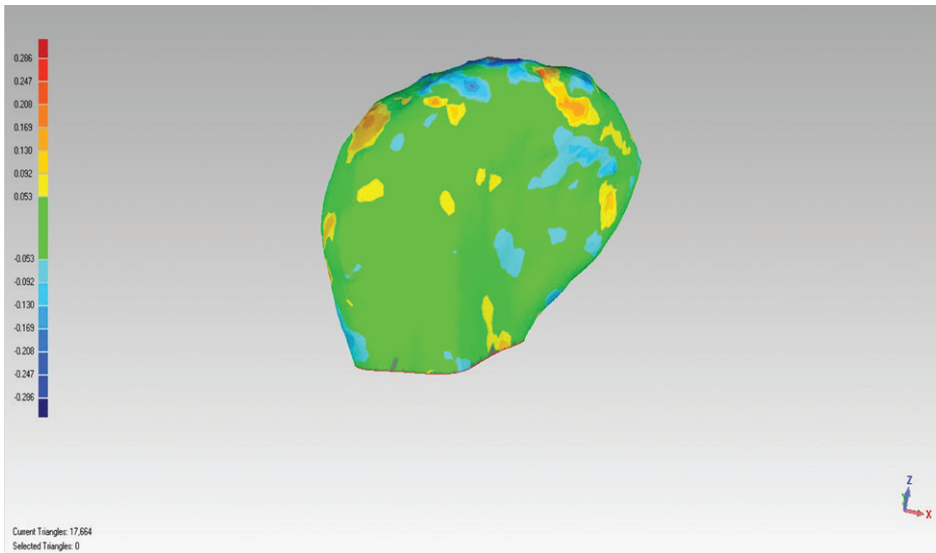


Fig. 2. A color map of condylar remodeling after orthognathic surgery. Red coloration shows bone formation, blue coloration shows bone resorption, and green coloration shows no change.

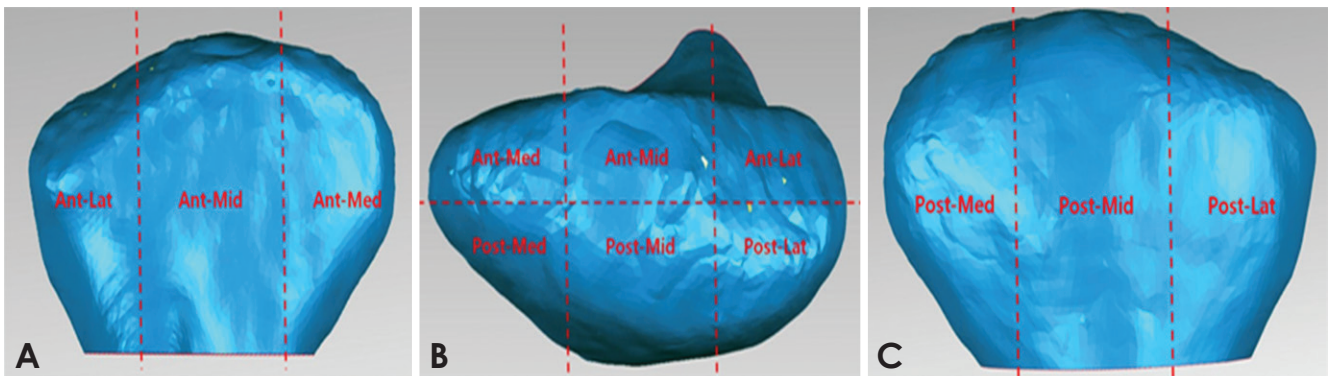


Fig. 3. The six areas of the condylar head. A, anterior surface; B, superior surface; C, posterior surface; Ant-Lat, anterolateral; Ant-Mid, anteromiddle; Ant-Med, anteromedial; Post-Lat, posterolateral; Post-Mid, posteromiddle; Post-Med, posteromedial.

Morrisville, NC, USA).

In order to quantitatively evaluate condylar surface changes, pre- and post-operative segmented condylar images were superimposed over three prominent registration points around the condylar neck using the manual registration function in Geomagic Studio[®] 12 (Fig. 1). After the manual registration, the global registration function provided by Geomagic Studio[®] 12 was used, and the reconstructed images were fitted automatically. Observer bias was eliminated since the procedures were automatically conducted. Using the Geomagic Studio[®] 12 tool, we calculated thousands of distances automatically (in millimeters) between the pre- and postoperative points on the registered image, such that the differences between two surfaces at any location could be quantified. These point-to-point distances were defined as condylar surface

Table 1. Quantitative assessment of condylar surface changes using point-to-point distances on the registered three-dimensional condylar images.

		n	Mean ± SD (mm)
Total	Maximum distance	80	0.41 ± 0.06
	Average distance	80	0.11 ± 0.03
	Standard deviation	80	0.09 ± 0.02

SD, standard deviation.

changes. The maximum distance, average distance, and standard deviation of these thousands of point-to-point distances were automatically calculated by Geomagic Studio[®] 12 for each condyle. Using these numeric values, we could identify how much the condylar surfaces changed after surgery.

A tool in Geomagic Studio[®] 12 converted the surface

Table 2. Frequencies of condylar remodeling types using color maps on the registered three-dimensional condylar images (n = 80).

Remodeling type	Area						Total
	Anteromedial	Anteromiddle	Anterolateral	Posteromedial	Posteromiddle	Posterolateral	
Bone resorption	13 (16.3%)	24 (30.0%)	44 (55.0%)	29 (36.3%)	32 (40.0%)	42 (52.5%)	184 (38.3%)
Bone formation	44 (55.0%)	26 (32.5%)	10 (12.5%)	22 (27.5%)	13 (16.3%)	18 (22.5%)	133 (27.7%)
No change	23 (28.8%)	30 (37.5%)	26 (36.3%)	29 (36.3%)	35 (43.8%)	20 (25.0%)	163 (34.0%)

distances into a color map for each registered 3D condylar image. Relative to the preoperative model, the positive (+) values of surface distances were expressed as red coloration (bone formation), the negative (-) values of surface distances were expressed as blue (bone resorption) and values close to zero were expressed as green (no change) (Fig. 2).

The color maps were used to evaluate the condylar remodeling types. The registered 3D images were cut through one plane, which was located around the condylar neck, and the area below that plane was erased. The plane used in this study was drawn over the thinnest portion of the condylar neck and parallel to a plane having the largest area among a number of areas for cross sections. The cross sections included the condylar long axis, which intersected the medial and lateral pole of the condylar head. An adjusted version of the method of An et al.³ was used to classify remodeling types on the remaining condylar head. The cutting plane used by An et al.³ intersected the medial and lateral pole areas of the condyle, but the location of the plane in this study was adjusted down to near the condylar neck area. The condylar head was divided into six areas (anteromedial, anteromiddle, anterolateral, posteromedial, posteromiddle, and posterolateral areas; Fig. 3) and each area was classified into three types of condylar remodeling (bone formation, no change, and bone resorption). The process of classifying the remodeling types of each condylar area was carried out twice (two weeks apart), and the degree of agreement of the classifications was evaluated to ensure intraobserver reliability.

All of the above procedures were performed to compare the condyle surface changes and remodeling types between the right and left condyles and between the sexes. All procedures were conducted by a single oral and maxillofacial radiologist.

Statistical analysis

All statistical analyses were performed using the Sta-

Table 3. Quantitative assessment of condylar surface changes using point-to-point distances on the registered three-dimensional condylar images between the right and left condyles.

	Right (n = 40, mm)	Left (n = 40, mm)	P-value
Maximum distance	0.40 ± 0.06	0.42 ± 0.05	>0.05
Average distance	0.10 ± 0.02	0.11 ± 0.03	>0.05
Standard deviation	0.09 ± 0.01	0.09 ± 0.01	>0.05

tistical Package for Social Sciences for Windows version 21.0 (IBM Corp., Armonk, NY, USA). Differences were considered to be significant at $p < 0.05$. The mean values of the maximum distances, average distances, and standard deviations of each condyle were calculated, reflecting condylar surface changes.

The condylar remodeling types were evaluated by frequency.

The Wilcoxon signed-rank test was performed to compare the condylar surface changes between the right and left condyles. The marginal homogeneity test, which evaluated the uniformity of the distribution of two related variables, was performed to compare the frequencies of condylar remodeling types between the right and left condyles.

Additionally, the t-test and Mann-Whitney test were conducted to compare the condylar surface changes between the sexes. In order to compare the frequency of condylar remodeling types between the sexes, the chi-square test and Fisher’s exact test were performed. Intraobserver reliability was evaluated using Cohen’s kappa index.

Results

The mean values of the maximum distances, average

Table 4. Frequencies of condylar remodeling types using color maps on the registered three-dimensional condylar images between the right and left condyles (n = 40).

Remodeling type	Anteromedial		Anteromiddle		Anterolateral		Posteromedial		Posteromiddle		Posterolateral	
	Right	Left	Right	Left	Right	Left	Right	Left	Right	Left	Right	Left
Bone resorption	8 (20.0%)	5 (12.5%)	10 (25.0%)	14 (35.0%)	19 (47.5%)	25 (62.5%)	17 (42.5%)	12 (30.0%)	14 (35.0%)	18 (45.0%)	21 (52.5%)	21 (52.5%)
Bone formation	23 (57.5%)	21 (52.5%)	13 (32.5%)	13 (32.5%)	5 (12.5%)	5 (12.5%)	8 (20.0%)	14 (35.0%)	8 (20.0%)	5 (12.5%)	10 (25.0%)	8 (20.0%)
No change	9 (22.5%)	14 (35.0%)	17 (42.5%)	13 (32.5%)	16 (40.0%)	10 (25.0%)	15 (37.5%)	14 (35.0%)	18 (45.0%)	17 (42.5%)	9 (22.5%)	11 (27.5%)
P-value	>0.05		>0.05		>0.05		>0.05		>0.05		>0.05	

distances, and standard deviations of condylar surface changes after orthognathic surgery were 0.41 ± 0.06 mm, 0.11 ± 0.03 mm, and 0.09 ± 0.02 mm, respectively (Table 1).

The intraobserver reliability for the classification of condylar remodeling types on the condylar head showed almost perfect agreement (Cohen's kappa index; average, 0.895). Bone resorption occurred more frequently (38.3%) than other types of condylar remodeling. However, bone formation in the anteromedial area and bone resorption in the anterolateral and posterolateral areas were observed to a much greater extent (>50%) than other remodeling types (Table 2).

No statistically significant differences were found in condylar surface changes or the frequency of condylar remodeling types between the right and left condyles (Table 3, Table 4). However, condylar surface changes in males were significantly larger than in females ($p < 0.05$; Table 5). No significant differences were found in the frequencies of condylar remodeling types between the sexes (Table 6).

Discussion

The evaluation of condylar morphology after orthognathic surgery is critical for predicting the clinical prognosis. Progressive condylar resorption has been found to be an irreversible complication and a factor in the development of late skeletal relapse after bilateral sagittal split, Le Fort I, or bimaxillary osteotomy.⁷ Recently, 3D images have been widely used to assess this condylar morphology. Xi et al.⁸ presented a reproducible tool for the 3D rendering of the condyle, which enabled the longitudinal follow-up and quantitative analysis of condylar changes. Schilling et al.⁹ showed that condylar registration was reliable and could be used to quantify subtle bony differ-

Table 5. Quantitative assessment of condylar surface changes using point-to-point distances on the registered three-dimensional condylar images according to sex.

	Male (n = 20, mm)	Female (n = 20, mm)	P-value
Maximum distance	0.43 ± 0.05	0.39 ± 0.03	$p < 0.05$
Average distance	0.11 ± 0.03	0.10 ± 0.03	$p < 0.05$
Standard deviation	0.10 ± 0.01	0.09 ± 0.01	$p < 0.05$

ences in 3D condylar morphology.

For these reasons, this study used 3D condylar images to assess condylar surface changes and remodeling types. Moreover, to the best of our knowledge, this was the first study to compare the right and left condyles and to compare these parameters according to sex.

In this study, three registration points on the pre- and postoperative 3D condylar images were used for superimposition. These points were selected from around the condylar neck area, since the condylar neck area exhibited relatively less change than other areas. Moreover, the registration points were needed to align the images, because the pre- and postoperative reconstructed 3D images from one patient were not exactly the same size. After this manual registration, an automatic global registration was then conducted once more in order to increase the accuracy.

In this study, the method proposed by An et al.³ was used to evaluate the frequency of condylar remodeling types, but the location of the cutting plane on the registered 3D condylar images was adjusted down to near the condylar neck area. The cutting plane in the study of An et al.³ intersected the medial and lateral pole areas of the condyle. However, it was hypothesized that the medial

Table 6. Frequencies of condylar remodeling types using color maps on the registered three-dimensional condylar images according to sex (male, n=20 [40 sides]; female, n=20 [40 sides]).

Remodeling type	Anteromedial		Anteromiddle		Anterolateral		Posteromedial		Posteromiddle		Posterolateral	
	Male	Female	Male	Female	Male	Female	Male	Female	Male	Female	Male	Female
Bone resorption	8 (20.0%)	5 (12.5%)	10 (25.0%)	14 (35.0%)	20 (50.0%)	24 (60.0%)	13 (32.5%)	16 (40.0%)	15 (37.5%)	17 (42.5%)	21 (52.5%)	21 (52.5%)
Bone formation	20 (50.0%)	24 (60.0%)	14 (35.0%)	12 (30.0%)	4 (10.0%)	6 (15.0%)	11 (27.5%)	7 (17.5%)	7 (17.5%)	6 (15.0%)	7 (17.5%)	11 (27.5%)
No change	12 (30.0%)	11 (27.5%)	16 (40.0%)	14 (35.0%)	16 (40.0%)	10 (25.0%)	16 (40.0%)	13 (32.5%)	18 (45.0%)	17 (42.5%)	12 (30.0%)	8 (20.0%)
P-value	>0.05		>0.05		>0.05		>0.05		>0.05		>0.05	

and lateral pole areas could change after surgery, and indeed, this change was confirmed by the color map, which presented the condylar remodeling types of the registered 3D condylar images.

Table 1 shows that the extent of condylar surface change after surgery, expressed as the mean of the average point-to-point distance, was 0.11 ± 0.03 mm in this study, which was larger than the mean and standard deviation (0.01 ± 0.09 mm) reported by An et al.³ and smaller than the average displacement of all surfaces reported by Cevidanes et al.¹⁰ (0.77 ± 0.17 mm).

We found that bone resorption occurred more frequently (38.3%) than other types of condylar remodeling (bone formation, 27.7%; no change, 34.0%). However, it cannot be suggested that bone resorption after surgery was the predominant pattern because the frequencies of these three remodeling types were similar. However, bone formation was the predominant pattern in the anteromedial area (55.0%), while bone resorption predominated in the anterolateral (55.0%) and posterolateral (52.5%) areas (Table 2). In other words, condylar remodeling after surgery was most commonly achieved through bone resorption. These results were similar to those of the previous studies by An et al.³ and Park et al.²

Comparisons between the right and left condyles and between the sexes have not been explored in previous studies. In this study, no significant differences were found in the frequency of condylar remodeling types in each area between the sexes or between the right and left condyles (Tables 4 and 6). However, males exhibited significantly greater condylar surface changes than females (Table 5).

Some researchers have proposed that forced condylar positioning in orthognathic surgery could lead to condylar remodeling.^{11,12} Hwang et al.¹³ suggested that a posteriorly inclined condylar neck should be considered a relevant

nonsurgical risk factor in condylar resorption following orthognathic surgery. An et al.³ found that inward condylar rotation after orthognathic surgery was closely related to condylar surface change. Nonetheless, the exact cause of condylar surface change remains controversial.

However, these changes on the condylar surface could, in turn, induce post-operative TMJ symptoms and early or late postoperative skeletal relapse.^{2,14,15} We found that bone resorption in the lateral area and bone formation in the anteromedial area were especially prominent. Additionally, condylar surface changes after orthognathic surgery occurred; in particular, the condylar surface change in males was greater than in females.

However, this study had some limitations. In particular, each group consisted of a small sample (20 males, 20 females). Additionally, the clinical significance of the values in this study is a potential limitation, since all quantitative values were smaller than the slice thickness (0.75 mm). For these reasons, further studies are needed.

References

1. Bouletreau P, Frey R, Breton P, Freidel M. Focus on the effect of orthognathic surgery on condylar remodeling. *Rev Stomatol Chir Maxillofac* 2004; 105: 283-8.
2. Park SB, Yang YM, Kim YI, Cho BH, Jung YH, Hwang DS. Effect of bimaxillary surgery on adaptive condylar head remodeling: metric analysis and image interpretation using cone-beam computed tomography volume superimposition. *J Oral Maxillofac Surg* 2012; 70: 1951-9.
3. An SB, Park SB, Kim YI, Son WS. Effect of post-orthognathic surgery condylar axis changes on condylar morphology as determined by 3-dimensional surface reconstruction. *Angle Orthod* 2014; 84: 316-21.
4. Kau CH, Richmond S, Incrapera A, English J, Xia JJ. Three-dimensional surface acquisition systems for the study of facial morphology and their application to maxillofacial surgery. *Int J Med Robot* 2007; 3: 97-110.

5. Motta AT, de Assis Ribeiro Carvalho F, Cevidanes LH, de Oliveira Almeida MA. Assessment of mandibular advancement surgery with 3D CBCT models superimposition. *Dental Press J Orthod* 2010; 15: 45e1-12.
6. Carvalho Fde A, Cevidanes LH, da Motta AT, Almeida MA, Phillips C. Three-dimensional assessment of mandibular advancement 1 year after surgery. *Am J Orthod Dentofacial Orthop* 2010; 137(4 Suppl): S53.e1-12.
7. Kobayashi T, Izumi N, Kojima T, Sakagami N, Saito I, Saito C. Progressive condylar resorption after mandibular advancement. *Br J Oral Maxillofac Surg* 2012; 50: 176-80.
8. Xi T, van Loon B, Fudalej P, Berge S, Swennen G, Maal T. Validation of a novel semi-automated method for three-dimensional surface rendering of condyles using cone beam computed tomography data. *Int J Oral Maxillofac Surg* 2013; 42: 1023-9.
9. Schilling J, Gomes LC, Benavides E, Nguyen T, Paniagua B, Styner M, et al. Regional 3D superimposition to assess temporomandibular joint condylar morphology. *Dentomaxillofac Radiol* 2014; 43: 20130273.
10. Cevidanes LH, Bailey LJ, Tucker GR Jr, Styner MA, Mol A, Phillips CL, et al. Superimposition of 3D cone-beam CT models of orthognathic surgery patients. *Dentomaxillofac Radiol* 2005; 34: 369-75.
11. Arnett GW. A redefinition of bilateral sagittal osteotomy (BSO) advancement relapse. *Am J Orthod Dentofacial Orthop* 1993; 104: 506-15.
12. Papadopoulou AK, Papachristou DJ, Chatzopoulos SA, Pirttiniemi P, Papavassiliou AG, Basdra EK. Load application induces changes in the expression levels of Sox-9, FGFR-3 and VEGF in condylar chondrocytes. *FEBS Lett* 2007; 581: 2041-6.
13. Hwang SJ, Haers PE, Seifert B, Sailer HF. Non-surgical risk factors for condylar resorption after orthognathic surgery. *J Craniomaxillofac Surg* 2004; 32: 103-11.
14. Komori E, Aigase K, Sugisaki M, Tanabe H. Cause of early skeletal relapse after mandibular setback. *Am J Orthod Dentofacial Orthop* 1989; 95: 29-36.
15. Van Sickels JE, Larsen AJ, Thrash WJ. Relapse after rigid fixation of mandibular advancement. *J Oral Maxillofac Surg* 1986; 44: 698-702.