

# Correction of Tooth-to-tooth Contact and Class IV Mesiodistocclusion by Orthodontic Tooth Movement in Three Dogs

Se-Eun Kim, Kyung-Mi Shim\* and Seong-Soo Kang<sup>1</sup>

College of Veterinary Medicine, Chonnam National University, Gwangju 500-757, Korea

\*College of Veterinary Medicine and Institute of Veterinary Science, Chonnam National University, Gwangju 500-757, Korea

(Accepted: October 28, 2015)

**Abstract :** Three Maltese dogs, 5 to 7 months old, were admitted to the Veterinary Medical Teaching Hospital, Chonnam National University with malocclusion including Class IV mesiodistocclusion. In the first case, the treatment was performed by moving the mandibular canine teeth caudally with orthodontic buttons and Masele chains. The second patient was treated for rostrverted mandibular canines using buttons and chains. When distal movement of the mandibular canine teeth was completed, a maxillary arch wire with finger springs was applied to push the incisor teeth forward. In the third case, the treatment began by moving the mandibular canine teeth caudally with buttons and chains. An arch wire with finger springs was applied at maxilla to move the maxillary incisor teeth labially. Additionally, the mandibular incisor teeth were moved lingually by an elastic band attached to the buttons cemented to mandibular canine teeth. As a result, all patients successfully regained a normal occlusion.

**Key words :** malocclusion, mesiodistocclusion, wry bite, orthodontics, dog.

## Introduction

Malocclusion in dogs is often encountered, and hence, is a common problem in veterinary dentistry (5,8). There are many oral problems associated with by untreated malocclusions including soft tissue trauma, traumatic dental fractures, dental attrition, loosening of the periodontal apparatus, periodontal disease, incorrect jaw growth, incorrect tooth positioning, and sometimes difficulty in eating (8,10). If there is the possibility that malocclusion may result in problems, corrective procedures for malocclusion should be initiated as soon as possible. Malocclusion should only be treated to help correct and relieve problems related to malocclusion, and not for cosmetic purposes. Therefore, the aim of orthodontic treatment is a comfortable and functional occlusion rather than a perfect occlusion (2,10).

Class IV mesiodistocclusion is a special classification of wry bite. Wry bite exists when one side of the mouth grows more than the other. In other words, the sides of the skull do not grow at the same rate. As a result, the midline of the maxilla does not line up with the midline of the mandible (4, 6,7). During the oral examination, it was observed that the mandible is out of alignment with the maxilla (2,7). Wry bite can cause the problems including the displacement of one or both of the mandibular canine teeth. Such a displacement will result in the mandibular canine teeth impinging the maxillary teeth or soft tissue. Wry bite is considered genetic in origin. Therefore, neutering should be performed prior to a

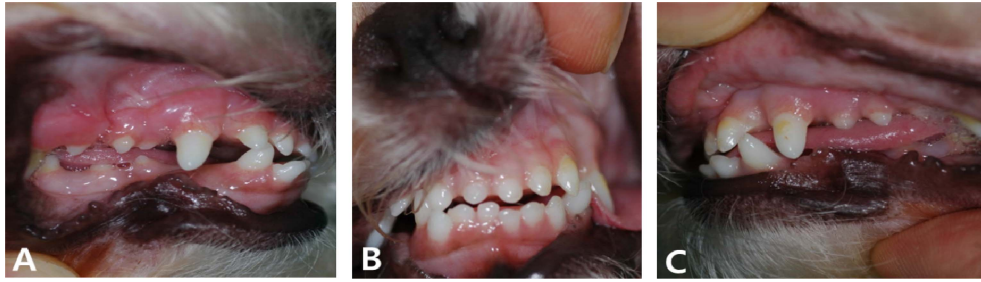corrective treatment (8). The treatment options for wry bite include coronal amputation and vital pulp therapy of one or both of the mandibular canine teeth, orthodontic therapy, and extraction of the tooth or teeth causing occlusal trauma. Among the treatment options, selective extraction of the mandibular canine teeth causing trouble is usually not recommended because the mandibular canine teeth are important in tongue retention, esthetics and oral functions. Instead, crown reduction and vital pulp therapy are performed to reduce length of the mandibular canine teeth. As a result, occlusal trauma can be relieved (2,4,7). If the patient is young and has a mild malocclusion, it can be treated successfully by orthodontic tooth movement among these treatment options (7). Young animals are better adapted to orthodontic appliances than older animals. Moreover, tooth movement is easier in younger animals (4).

Based on the author's experience, wry bite is especially common in small breed dogs, including Maltese and Yorkshire terriers. In this case report, we demonstrate three cases of orthodontic treatment with simple appliances for wry bite in young Maltese dogs.

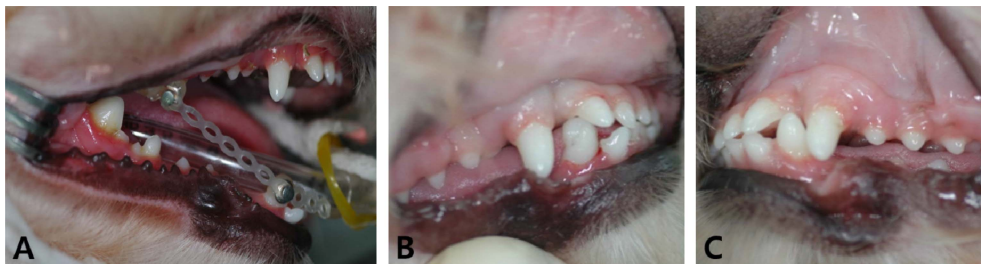
## Case 1

A 7-month-old, male, Maltese dog was admitted to the Veterinary Medical Teaching Hospital, Chonnam National University with malocclusion. During oral examination, the patient exhibited orthodontic problems including Class IV mesiodistocclusion (wry bite). Moreover, tooth-to-tooth contacts secondary to rostrverted mandibular canine teeth were observed (Fig 1). It was decided to move the mandibular canine teeth into a normal position between the maxillary

<sup>1</sup>Corresponding author.  
E-mail : vetkang@chonnam.ac.kr



**Fig 1.** Photographs of the first patient before treatment. (A) Right lateral view. Tooth-to-tooth contact due to rostrverted mandibular canine teeth was observed. (B) Frontal view. Wry bite was observed. (C) Left lateral view. As in the right lateral view, there was tooth-to-tooth contact between the mandibular canine and the maxillary incisor teeth.



**Fig 2.** Photographs of the first patient after treatment. (A) Orthodontic buttons and Masel chains were applied to the maxillary fourth premolar and mandibular canine teeth. (B) Right lateral view of the patient after 4 weeks treatment, (C) Left lateral view of the patient after 4 weeks treatment. Compared to Fig 1, the mandibular canine teeth had moved caudally and almost normal occlusion was achieved.

canine and third incisor teeth. The patient was premedicated with cimetidine (5 mg/kg IV, H-2<sup>®</sup>AMP; JW Pharmaceutical, Korea) and cefazolin (20 mg/kg IV, Cefazolin CKD INJ<sup>®</sup>; Chong Kun Dang Pharm, Korea). Anaesthesia was induced with intramuscular injection of a combination of medetomidine (48 µg/kg IM, Domitor<sup>®</sup>; Pfizer Animal Health, Korea), tiletamine/zolazepam (3 mg/kg IM, Zoletil<sup>®</sup>; Virbackorea, Korea) and tramadol hydrochloride (5.4 mg/kg IM, Tramadol HCl<sup>®</sup>; Huons Inj.; Huons, Korea). After the patient was intubated, anaesthesia was maintained with isoflurane (IFRAN LIQ<sup>®</sup>; Hana Pharm Co., Ltd, Korea) and oxygen.

Dental impressions and stone models of the patient's dentition were obtained under general anesthesia. A proper impression tray fitted in the patient's mouth was selected. Next, alginate powder and water were mixed together in the ratio of one to one with a mixing device (TORNADO<sup>®</sup>, SHM-ALM00, Shinhung Co., Ltd, Korea) for dental impression materials following the manufacturer's instructions. The mixture was then loaded onto the impression tray. The impression tray was placed into the patient's mouth until the alginate was firm and removed. After the patient was extubated, a wax bite registration was obtained and the patient was intubated again.

Boxing wax wrapped the alginate impressions and was attached around the impressions. The impressions were filled with the stone mix. After 2 hours, the alginate was removed from the stone models using a laboratory knife. The obtained stone models and the bite registration were used to evaluate malocclusion and formulate the treatment plan. Then, we selected and fabricated the appropriate orthodontic appliances including buttons and Masel chains. The maxillary fourth premolar teeth were used as anchor teeth to move ros-

trally deviated mandibular canine teeth caudally. The maxillary fourth premolar teeth and the mandibular canine teeth were polished, dried and etched. After etching, orthodontic buttons were applied on the teeth surface by bonding resins. Length of Masel chain between the buttons was measured to allow for stretching with moderate tension under 50 g. Then, Masel chains were cut to the measured length and were placed on the buttons. (Fig 2).

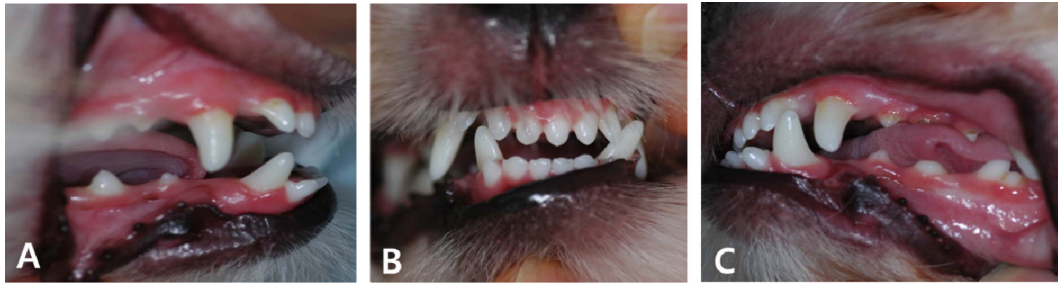The patient was rechecked one week later. As the mandibular canine teeth were found to have begun to move caudally, the Masel chains were tightened one notch and retained for two weeks, after which the Masel chains were tightened one more notch in the same manner.

The mandibular canine teeth had moved caudally and to functional occlusion after two weeks (Fig 2). During oral examination, it was evident that the midline of the arches lined up and the wry bite was corrected. Therefore, the orthodontic appliances including buttons and chains were removed from the teeth.

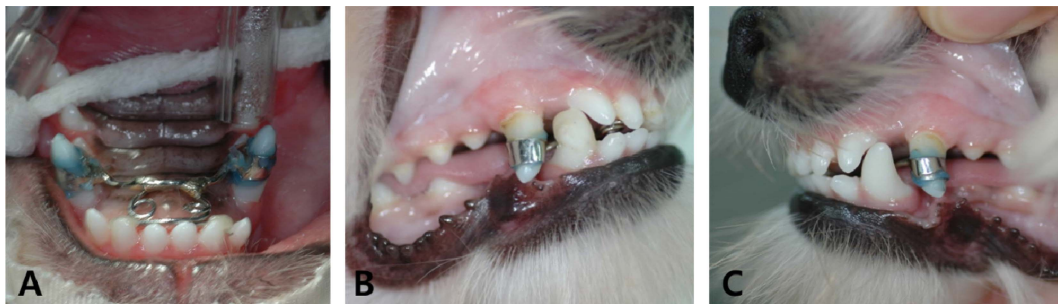## Case 2

A 7-month-old, male, Maltese dog was admitted to the Veterinary Medical Teaching Hospital, Chonnam National University with malocclusion. During oral examination, it was evident that the patient had Class IV mesiodistocclusion (wry bite). When the mouth was closed, the maxillary and mandibular incisor teeth did not occlude and there was larger space between the incisor teeth (open bite). In addition, tooth-to-tooth contact was observed (Fig 3).

Premedication and anesthesia were performed as in case 1. Dental models were obtained and used to prepare the treat-



**Fig 3.** Photographs of the second patient before treatment. (A) Right lateral view. The mandibular canine was rostrally deviated. (B) Frontal view. Excessive “freeway space” and wry bite were observed. (C) Left lateral view. There was tooth-to-tooth contact between the mandibular canine and the maxillary incisor teeth.



**Fig 4.** Photographs of the second patient after treatment. (A) Application of maxillary arch wire with finger spring in the second patient. (B) Right lateral view of the patient after 8 weeks treatment, (C) Left lateral view of the patient after 8 weeks treatment. Compared to Fig 3, the patient had obtained a normal occlusion and could close the mouth. Moreover, the mandibular canine teeth were positioned into proper occlusion.

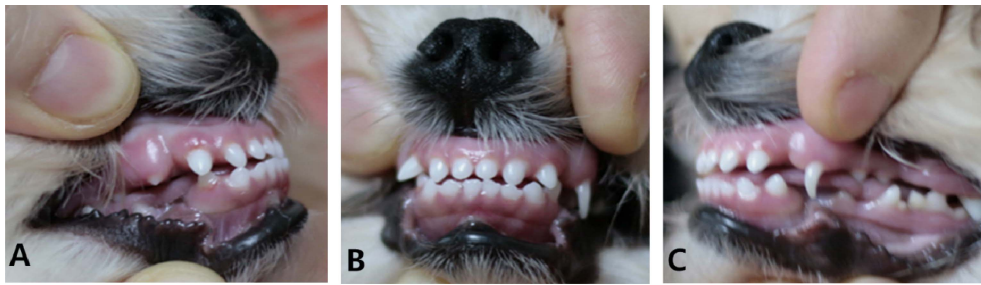ment plan and fabricate the orthodontic appliance. First, the rostrverted right mandibular canine tooth was treated by using buttons and chains. Additionally, after 4 weeks, a maxillary arch wire with finger springs was applied to move the maxillary incisor teeth into a more functional position that is closer to the lips (Fig 4A). Self-etching bonding agent (One-Up Bond F Plus<sup>®</sup>, Tokuyama Dental Corporation, Japan) was used for cementation of the arch wire on the surface of teeth. Bonding agents A and B were mixed thoroughly until the mixture turned pink. The mixture was applied to the surface of the maxillary canine teeth, and was rubbed for 10 seconds. Next, after light-curing for 10 seconds, the resin composite was placed on the bonded surface. Bands linked with the arch wire were placed around the canine teeth. To keep the wire from slipping over the incisal edge or forward, a small amount of composite resin was placed on the lingual surface of the right and left maxillary second incisor teeth. The appliance was then fixed into the patient’s mouth. Within 8 weeks, distal movement of the mandibular canine tooth was completed and the maxillary incisor teeth were successfully positioned into a functional occlusion (Fig 4). Finally, the patient had proper occlusion that the lines between the first incisor teeth on the maxilla and the mandible did match and the normal scissors bite pattern was observed. All orthodontic appliances were removed. All remaining cement was then removed using a hand scaler and polishing was performed.

### Case 3

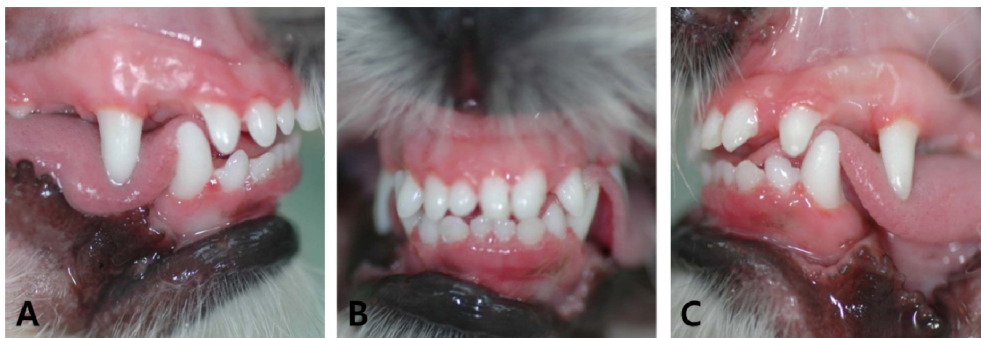A 5-month-old, male, Maltese dog was admitted to the

Veterinary Medical Teaching Hospital, Chonnam National University with malocclusion. When the mouth was in resting occlusion, the maxillary and mandibular incisor teeth met each other edge to edge as with a level bite. Moreover, wry bite was also observed and the pointed crowns of the right mandibular canine teeth hit the maxillary third incisor teeth (Fig 5).

Premedication and anesthesia were performed, as in case 1. Dental models were made and used to prepare the treatment plan and to fabricate the orthodontic appliance. First, it was corrected that the right mandibular canine teeth met the maxillary third incisor teeth. As in case 1, the mandibular canine tooth was moved to the normal position in about 4 weeks by using orthodontic buttons and a Masel chain. Next, as mentioned in case 2, an arch wire with finger springs was applied at maxilla to move the maxillary incisors labially. In a follow-up evaluation at 2 weeks, the left maxillary incisor teeth excessively moved forward. Therefore, the appliance was re-adjusted under general anesthesia. The left finger spring was removed using wire cutters, whereas the right finger spring was maintained for more movement of the right maxillary incisor teeth. Additionally, an elastic band was attached to buttons cemented to the mandibular canine teeth to move the mandibular incisor teeth lingually. As a result, a proper occlusion was achieved in the third patient after a total of 8 weeks. The right mandibular canine tooth was moved into the correct position between the maxillary third incisor and the canine teeth and the midline of the maxillary incisor teeth was nearly even with the midline of the mandibular incisor teeth (Fig 6).



**Fig 5.** Photographs of the third patient before treatment. (A) Right lateral view. The right mandibular canine tooth was in contact with the right maxillary third incisor tooth. (B) Frontal view. A level bite was seen. The incisor teeth met edge on edge. (C) Left lateral view.



**Fig 6.** Photographs of the third patient after 8 weeks. (A) Right lateral view, (B) Frontal view, (C) Left lateral view. Compared Fig 5, the mandibular canine teeth were placed into a proper position and the maxillary incisor teeth overlap with the mandibular incisor teeth (scissors' bite).

## Discussion

Wry bite is an unusual form and a special classified malocclusion, Class IV mesiodistocclusion (1,2,10). This is a condition where one side of the maxilla or the mandible grows forward more than the other side resulting in a jaw length discrepancy (7,8). In the present cases, three Maltese dogs were admitted with malocclusion and basic oral examination revealed that the three dogs had orthodontic problems associated with wry bite.

In most cases of wry bite, there will be a deviation of the midline of the head and an asymmetry between the teeth of each side (8). Also, there may be a triangular defect between the maxillary and mandibular incisors (2). Shipp and Fahrenkrug stated that there is 'a sloping open bite' of the incisor teeth from one side to the other (8). All three cases exhibited that the maxillary and mandibular midlines did not match. Especially in the second case, the patient presented a triangular defect, namely a sloping open bite in frontal view.

Eventually, this malocclusion will lead to the mandibular canine teeth striking the maxillary structures including palate, gingiva, teeth or lip. As a result, the patients feel a severe pain and become infected because of the trauma (7). In this case report, three patients had a rostral displacement of the mandibular canine teeth caused by wry bite. Thus, there were tooth-to-tooth contacts between the mandibular canine teeth and the maxillary incisor teeth secondary to the displacement. The abnormal tooth-to-tooth contacts will result in abnormal tooth wear. Therefore, we decided to correct the problems associated with the malocclusion. In addition, we advised the owners to neutering the dogs prior to the treat-

ment because wry bite is a genetic malocclusion.

Corrective procedures for wry bite include coronal amputation and vital pulp therapy of the mandibular canines, orthodontic procedures, extraction of the teeth causing the problems (7). It was considered that orthodontic movement would be fast and easy because three patients were young, 5 to 7 months old. To prepare the treatment plan and to fabricate orthodontic appliances, dental models and impressions were made by materials including alginate and dental stone following the manufacturer's instructions.

In the first case, tooth-to-tooth contacts secondary to rostroverted mandibular canine teeth were the most important problems. Therefore, the displacement of the mandibular canine teeth was corrected by orthodontic buttons and a Masel chain. Masel chains were stretched and remained with moderate tension under 50 g. The patient was rechecked on a weekly basis. Adjustment of chain tension was performed depending on a follow-up examination. After 4 weeks, the mandibular canine teeth had moved into the normal position between the maxillary canine teeth and the third incisor teeth without making contact with the teeth (3). In the second case, the rostroverted right mandibular canine tooth became a problem and was treated by using buttons and chains as in the first case. Also, a maxillary arch wire with finger springs was used to move the maxillary incisors rostrally, because the second patient had prognathism, and malocclusion was more severe than in the first patient. As a result, the mandibular canine and the maxillary incisor teeth were positioned into a functional occlusion state.

In the third case, the treatment plan was similar to the treatment of the second patient. However, 2 weeks later, the

left maxillary incisor teeth had moved excessively forward. Therefore, the maxillary arch wire with finger springs was readjusted under general anesthesia. The left maxillary incisor teeth were stationary and the right maxillary incisor teeth had moved more labially. Additionally, the mandibular incisor teeth had been moved lingually by an elastic band attached to the buttons cemented to mandibular canine teeth. Consequently, the maxillary incisor teeth overlapped with the mandibular incisor teeth (scissors' bite) after 2 weeks.

Finally, in all 3 small breed dogs a normal occlusion was obtained. In conclusion, the present cases suggest that it is important to diagnose the orthodontic problems and determine the appropriate orthodontic appliances for teeth movement.

### Acknowledgement

This work was supported by a grant from the Next-Generation BioGreen 21 Program (No.: PJ01135201), Rural Development Administration, Republic of Korea.

### References

- Bannon K, Baker L. Cast metal bilateral telescoping inclined plane for malocclusion in a dog. *J Vet Dent* 2008; 25: 250-258.
- Bellows J. Orthodontic equipment, materials, and techniques. In: *Small animal dental equipment, materials and techniques: A primer*, 1st ed. Ames: Wiley-Blackwell. 2008: 263-296.
- Goldstein G. The diagnosis and treatment of orthodontic problems. *Probl Vet Med* 1990; 2: 195-219.
- Harvey CE, Emily P. Occlusion, occlusive abnormalities, and orthodontic treatment. In: *Small animal dentistry*, 1st ed. St. Louis: Mosby. 1993: 266-311.
- Hobson P. Normal occlusion in the dog. *J Vet Dent* 2005; 22: 196-198.
- Kesel ML. Assisting with orthodontics, prosthodontics, and restorative dentistry. In: *Veterinary dentistry for the small animal technician*, 1st ed. Ames: Iowa State University Press. 2000: 183-212.
- Niemiec BA. Pathology in the pediatric patient. In: *Small animal dental, oral and maxillofacial disease*, 1st ed. Oxford: Manson Publishing. 2010: 90-127.
- Shipp AD, Fahrenkrug P. Orthodontics. In: *Practitioners' guide to veterinary dentistry*, 1st ed. Glendale: Griffin Printing. 1992: 117-147.
- Ulbricht RD, Marretta SM. Orthodontic treatment using a direct acrylic inclined plane. *J Vet Dent* 2005; 22: 60-65.
- Wiggs RB, Lobprise HB. Basics of orthodontics. In: *Veterinary dentistry: principles and practice*, 1st ed. Philadelphia: Lippincott-Raven Publishers. 1997: 435-481.

## 세 마리 개에서 교정적 치아이동에 의한 치아-치아 접촉 및 IV급 근원심교합의 교정

김세은 · 심경미\* · 강성수<sup>1</sup>

전남대학교 수의과대학, \*전남대학교 동물의학연구소

**요약** : 5-7개월령의 세 마리 말티즈가 전남대학교 동물병원에 IV급 근원심교합으로 내원하였다. 첫 번째 증례는 부정교합은 교정 버튼과 Masel chain을 사용하여 하악 견치를 뒤쪽으로 이동시켜 교정하였다. 두 번째 증례는 교정 버튼과 체인을 이용하여 전방전위된 견치를 교정하였다. 하악 견치가 후방으로 이동이 완료된 후 상악에 finger spring과 함께 arch wire를 적용하여 전치를 앞쪽으로 이동시켰다. 세 번째 증례는 버튼과 체인을 이용하여 하악 견치를 후방으로 이동시킨 후 상악에 finger spring과 함께 arch wire를 적용하여 전치를 앞쪽으로 이동시켰다. 또한 하악 견치에 부착시킨 버튼에 elastic band를 장착하여 하악 견치를 후방으로 이동시켰다. 결과적으로 모든 환자에서 성공적으로 정상적 교합을 재건할 수 있었다.

**주요어** : 부정교합, 근원심교합, 비틀림교합, 교정, 개