



Contour of lingual surface in lower complete denture formed by polished surface impression

Yu-Ri Heo, Hee-Jung Kim, Mee-Kyoung Son, Chae-Heon Chung*

Department of Prosthodontics, School of Dentistry, Chosun University, Gwangju, Republic of Korea

PURPOSE. The aim of this study was to analyze the shapes of lingual polished surfaces in lower complete dentures formed by polished surface impressions and to provide reference data for use when manufacturing edentulous trays and lower complete dentures. **MATERIALS AND METHODS.** Twenty-six patients with mandibular edentulism were studied. After lower wax dentures were fabricated, wax was removed from the lingual side of the wax denture and a lingual polished surface impression was obtained with tissue conditioner. The definitive denture was scanned with a three-dimensional scanner, and scanned images were obtained. At the cross-sections of the lingual frenum, lateral incisors, first premolars, first molars, and anterior border of the retromolar pads, three points were marked and eight measurements were taken. The Kruskal-Wallis test and a post hoc analysis with the Mann-Whitney test were performed. **RESULTS.** Each patient showed similar values for the same areas on the left and right sides without a statistically significant difference. The height of the contour of the lingual polished surface at the lingual frenum was halfway between the occlusal plane and lingual border, it moved gradually in a downward direction. The angle from the occlusal plane to the height of the contour of the lingual polished surface was increased as it progressed from the lingual frenum towards the retromolar pads. **CONCLUSION.** The shape of the mandibular lingual polished surface was convex at the lingual frenum, lateral incisors and gradually flattened towards the first molars and retromolar pads. [*J Adv Prosthodont 2016;8:472-8*]

KEYWORDS. Contour; Lower complete denture; Lower polished surface; Polished surface impression; Shape

INTRODUCTION

Three factors—stability, retention, and support—are crucial for fabricating successful complete dentures that satisfy both the dentist and patient.¹ Complete dentures comprise three surfaces: the impression surface, which refers to the surface that is formed via the impression and is in contact with the tissue, the occlusal surface, which is the surface where the artificial teeth are arranged, and the polished surface, which

is the surface not comprised of the aforementioned two surfaces. All of these surfaces should be taken into consideration to fabricate successful complete dentures.

When all teeth are lost, a potential denture space exists within the oral cavity. The neutral zone refers to the space in which lateral forces exerted by the tongue and inward forces exerted by the cheek and lips are in equilibrium. Muscular contractions that occur during various functions, such as chewing, talking, and swallowing, vary in strength and direction for each individual. A complete denture must be positioned properly within the neutral zone for it to acquire stability and increased retention during such functions.² In particular, for an edentulous patient who has severe resorption of the residual alveolar ridge, the buccinator muscle and tongue can help to enhance the stability of the denture. Tongue position may be an important factor in denture stability.³⁻⁵ The polished surface of the denture minimizes food accumulation and helps the cheeks push the food onto the occlusal surface, easing the chewing process.⁶ For this reason, fabrication of the polished surface is important. However, dentists have relatively lower awareness of the importance of the polished surface compared

Corresponding author:
Chae-Heon Chung
Department of Prosthodontics, School of Dentistry, Chosun University,
309 Philmun-daero, Dong-gu, Gwangju 61452, Republic of Korea
Tel. +82622203826; e-mail, jhjung@chosun.ac.kr
Received May 9, 2016 / Last Revision August 7, 2016 / Accepted October
11, 2016

© 2016 The Korean Academy of Prosthodontics
This is an Open Access article distributed under the terms of the Creative
Commons Attribution Non-Commercial License (<http://creativecommons.org/licenses/by-nc/3.0>) which permits unrestricted non-commercial use,
distribution, and reproduction in any medium, provided the original
work is properly cited.

This study was supported by research fund from Chosun University Dental Hospital, 2015.

with those of the impression surface and occlusal surface. Because of the inconvenience caused by taking additional impressions and the complicated laboratory process, most dentists allow the fabrication of the polished surface to be performed by dental technicians.

Many materials and techniques have been introduced for the fabrication of the polished surface. In 1993, Fish⁷ began to realize the importance of the polished surface and assumed that the lips, cheeks, and tongue muscle are important for the stability of the denture, and that the stability could be further enhanced by making the buccal and lingual surfaces concave to accommodate the muscles.⁸ Since Fish, many clinicians have reported neutral zone impression techniques. There is a large amount of literature on polished surface impression techniques. However, only a few studies have surveyed the shape of the polished surface, and most of them only briefly commented on the shape. In 1963, Raybin⁹ took a polished surface impression using wax and examined the shapes. He found that most lingual polished surfaces in the lower posterior region were flat, not concave. Tuckfield¹⁰ and Tillman¹¹ suggested that the lingual polished surface in the molar area should not be concave, but the anterior region should be slightly concave to position the tongue. In contrast, another study asserted that lingual surfaces should be concave to provide space for tongue function and rest, and except at the border, should be as thin as possible.¹² Sussman¹³ stated that the anterior region of the lingual polished surface should be flat, but other regions should be concave. Block¹⁴ also argued that polished surfaces should be concave in consideration of the position of the tongue.¹⁵ In 2009, Canna *et al.*¹⁶ published an article comparing a denture with a polished surface fabricated via an impression by a dentist with one fabricated arbitrarily by a dental technician. In the article, they stated that the lower buccal surface fabricated by a dental technician was concave, but the actual impression of the polished surface showed a convex shape. In 2012, Srivastava *et al.*⁶ suggested that the anterior region of the lower lingual polished surface had a large shelf shape with a lingual inclination. This shelf shape is created by the movement of the tongue muscles, and the tongue is placed on this shelf to help retain the denture. As shown in previous studies, there are many views regarding the polished surfaces of dentures. Furthermore, the shapes have not been elaborated on with accurate measurements, but only in words such as convex, concave, or flat, so it is difficult to understand the exact shapes of the polished surface.

The shape of the polished surface varies in every patient, but the shapes and contours are predicted to be similar in general.⁶ The objective of the present study was to accurately present the contour of the lingual surface in lower complete dentures formed by polished surface impressions. Such findings would provide standards for lingual shapes when manufacturing edentulous trays for preliminary impressions, as well as when fabricating dentures for patients.

MATERIALS AND METHODS

We studied 26 edentulous patients who required lower complete dentures. The mean age of the patients was 73.2 years, and six men and twenty women were included.

A wax denture was fabricated via the conventional method. First, we took a preliminary impression and made a diagnostic cast. Then, the individual tray was fabricated, after which the final impression was taken. The final impression was taken by border-molding using a modeling compound and taking a functional impression using a polysulfide. We fabricated an occlusal record on the master cast and adjusted it within the oral cavity. Then, the vertical dimension was determined and interocclusal record was taken. The anterior teeth arrangement was made in consideration of esthetic factors and the position of the residual alveolar ridge, and the posterior teeth were arranged such that the lingual cusp was positioned within Pound's triangle, which is formed by the buccal and lingual surfaces of the retromolar pad and the mesial surface of the lower canine. Tooth positions were standardized in this arrangement. We took an impression of the polished surface within the patient's oral cavities using a wax denture. The lingual wax was carefully removed from the wax denture and tissue conditioner (Tempo, Lang dental manufacturing Co., Wheeling, WV, USA) was applied. After trying it within the patient's oral cavity, we instructed the patients to perform some movements. The patients swallowed water, stretched out their tongues, moved them to the left and right, and licked their upper and lower lips with their tongues. The shapes of the lingual tissues and muscle movement were taken during these exercises (Fig. 1A).¹⁶ The definitive denture was fabricated via the conventional method (Fig. 1B). The definitive denture was scanned using a model scanner (Scanner S6000 ARTI, Zirkozahn, Gais, Italy) to acquire images (Fig. 2). The scan files were then divided into different regions in the program (Rhinoceros 5.0, McNeel, Seattle, WA, USA) to analyze the cross-sections.

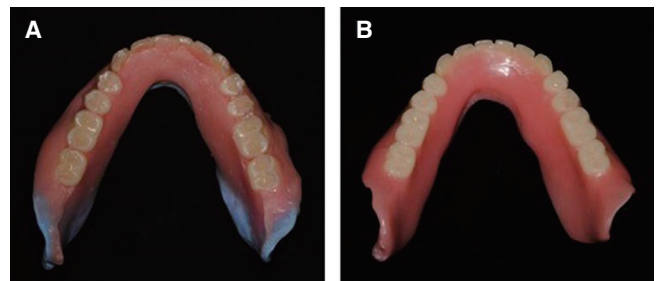


Fig. 1. (A) Lower wax denture formed by polished surface impression using a tissue conditioner, (B) Definitive lower complete denture.

The cross-sections were divided into 10 sections. First, we formed an occlusal plane by connecting the mesial incisal edge of the central incisor and distobuccal cusps of the right and left second molars and cut perpendicular to the occlusal plane. The 10 sections were the lingual frenum, both lateral incisors, both first premolars, both first molars, and both anterior borders of the retromolar pads, and we took measurements in each region (Fig. 3).

We marked three points: at (a) the lingual gingival margin of the artificial teeth; (b) the height of the contour at

the lingual polished surface; and (c) the most inferior lingual border at the cross-section and measured the following eight values: (A) the perpendicular distance between the a-c line and b; (B) the vertical distance from the occlusal plane to b; (C) the vertical distance between b and c; (D) the vertical distance from the occlusal plane to c; (E) the ratio of C to D; (F) the angle formed by the a-b line and the occlusal plane; (G) the angle formed by the b-c line and the occlusal plane; and (H) the angle formed by the a-b line and the b-c line (Fig. 4).

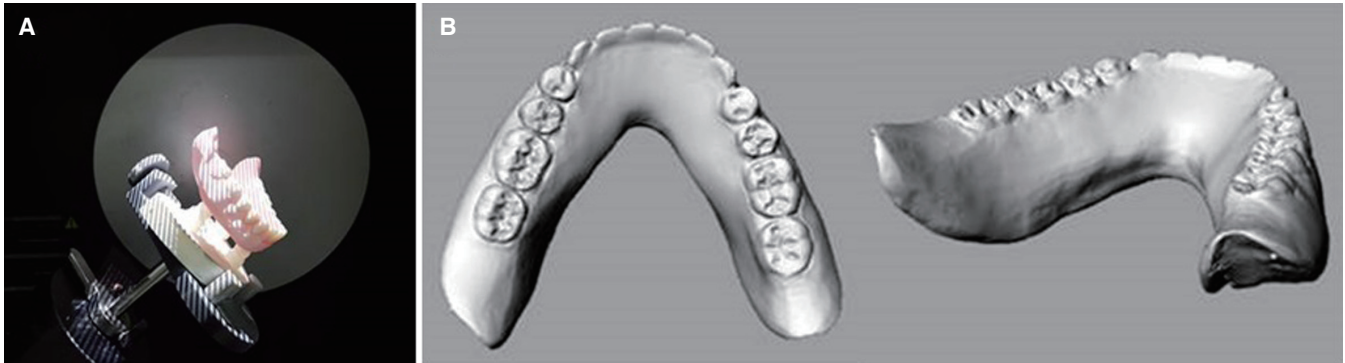


Fig. 2. (A) Scanning of the definitive denture, (B) Scanned images of definitive denture.

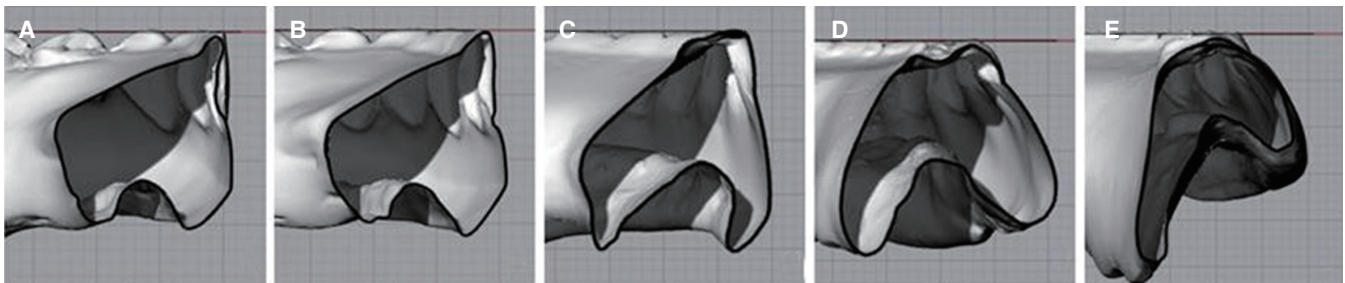


Fig. 3. Cross sections of each region. (A) lingual frenum, (B) lateral incisor, (C) first premolar, (D) first molar, (E) anterior border of retromolar pad.

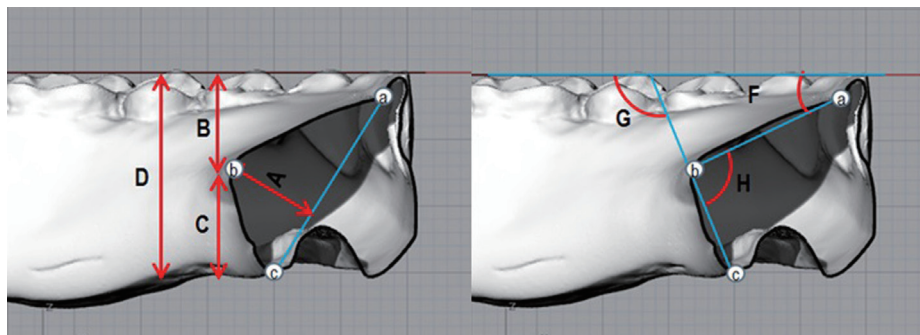


Fig. 4. Reference points and measurements at the sectioned lingual polished surface. (a) the lingual margin of the artificial teeth, (b) the height of the contour at the lingual polished surface, (c) the most inferior lingual border, (A) the perpendicular distance between the a-c line and b, (B) the vertical distance from the occlusal plane to b, (C) the vertical distance between b and c, (D) the vertical distance from the occlusal plane to c, (E) the ratio of C to D, (F) the angle formed by the a-b line and the occlusal plane, (G) the angle formed by the b-c line and the occlusal plane, (H) the angle formed by the a-b line and the b-c line.

The data were statistically analyzed using SPSS software (IBM SPSS Statistics 23.0, SPSS Inc., Chicago, IL, USA). Paired t test were performed to compare the significances of right and left measurements from the same region in each patient. The measurement values were recorded for each cross-section and were tested for significance via the Kruskal-Wallis test. For a post hoc test, the Mann-Whitney test was performed, and the significance level was set to 1% based on Bonferroni's method ($P < .01$). In all other tests except for the Mann-Whitney test, the significance level was set to 5% ($P < .05$).

RESULTS

In the paired t tests performed to examine whether the shapes of the right and left lingual polished surfaces were similar in each patient, the results showed P values of .785 between the left and right lateral incisors, .906 between the

first premolars, .991 between the first molars, and .644 between the anterior borders of the retromolar pads; all of which were greater than .05. This finding signifies that there was no significant difference between the right and left shapes in each patient (Table 1).

For all 26 patients, we took measurements from A to H for each cross-section of the lingual frenum, lateral incisor, first premolar, first molar, and anterior border of retromolar pad. We used the mean value of the right and left measurements for each region (Table 2, Table 3).

The cross-section of the polished surface at the lingual frenum was convex (Fig. 5A). The height of contour of the lingual polished surface was positioned halfway (E) between the occlusal plane and lingual border, and this point was about 4.72 mm (A) lingual to the line connecting the lingual gingival line of the artificial teeth and the lingual border. The angle between the plane in which the gingival margin occurred to the lingual height of the contour and occlusal

Table 1. The results of the paired t test between right and left measurements in each region

	Paired Differences				t	df	P value
	Mean (SD)	Std. Error	95% CI				
			Lower	Upper			
I (L) - I (R)	.09567 (5.05131)	.35025	-.78618	.59483	-.273	207	.785
P (L) - P (R)	.05394 (6.60526)	.45799	-.95687	.84899	-.118	207	.906
M (L) - M (R)	.00615 (7.59196)	.52641	-1.04396	1.03165	-.012	207	.991
R (L) - R (R)	.15938 (4.97200)	.34475	-.83904	.52029	-.462	207	.644

*; significant difference ($P < .05$)

I, lateral incisor; P, first premolar; M, first molar; R, anterior border or retromolar pad; (L), left side; (R), right side

Table 2. Mean values and standard deviations of 5 distance measurements at each region (unit: A - D mm, E ratio)

	Lingual frenum	Lateral incisor	First premolar	First molar	Ant. border of retromolar pad
A	4.72 ± 1.51	5.44 ± 1.27	4.80 ± 0.85	3.44 ± 1.04	2.79 ± 0.78
B	7.78 ± 2.1	8.45 ± 2.44	9.91 ± 2.17	13.87 ± 2.63	15.07 ± 2.48
C	7.74 ± 2.91	7.80 ± 2.98	8.17 ± 2.56	6.60 ± 2.55	3.96 ± 1.83
D	15.52 ± 2.43	16.25 ± 2.31	18.08 ± 2.41	20.47 ± 2.38	19.03 ± 3.00
E	0.49 ± 0.15	0.47 ± 0.15	0.45 ± 0.12	0.32 ± 0.12	0.20 ± 0.80

Table 3. Mean values and standard deviations of 3 angle measurements at each region (unit: degree)

	Lingual frenum	Lateral incisor	First premolar	First molar	Ant. border of retromolar pad
F	29.87 ± 8.22	31.46 ± 10.70	43.50 ± 9.74	64.08 ± 9.34	73.96 ± 5.28
G	96.04 ± 18.05	102.51 ± 16.26	105.83 ± 12.06	110.68 ± 15.17	117.75 ± 7.98
H	113.83 ± 14.86	107.90 ± 11.38	117.05 ± 10.26	131.49 ± 10.10	136.25 ± 9.44

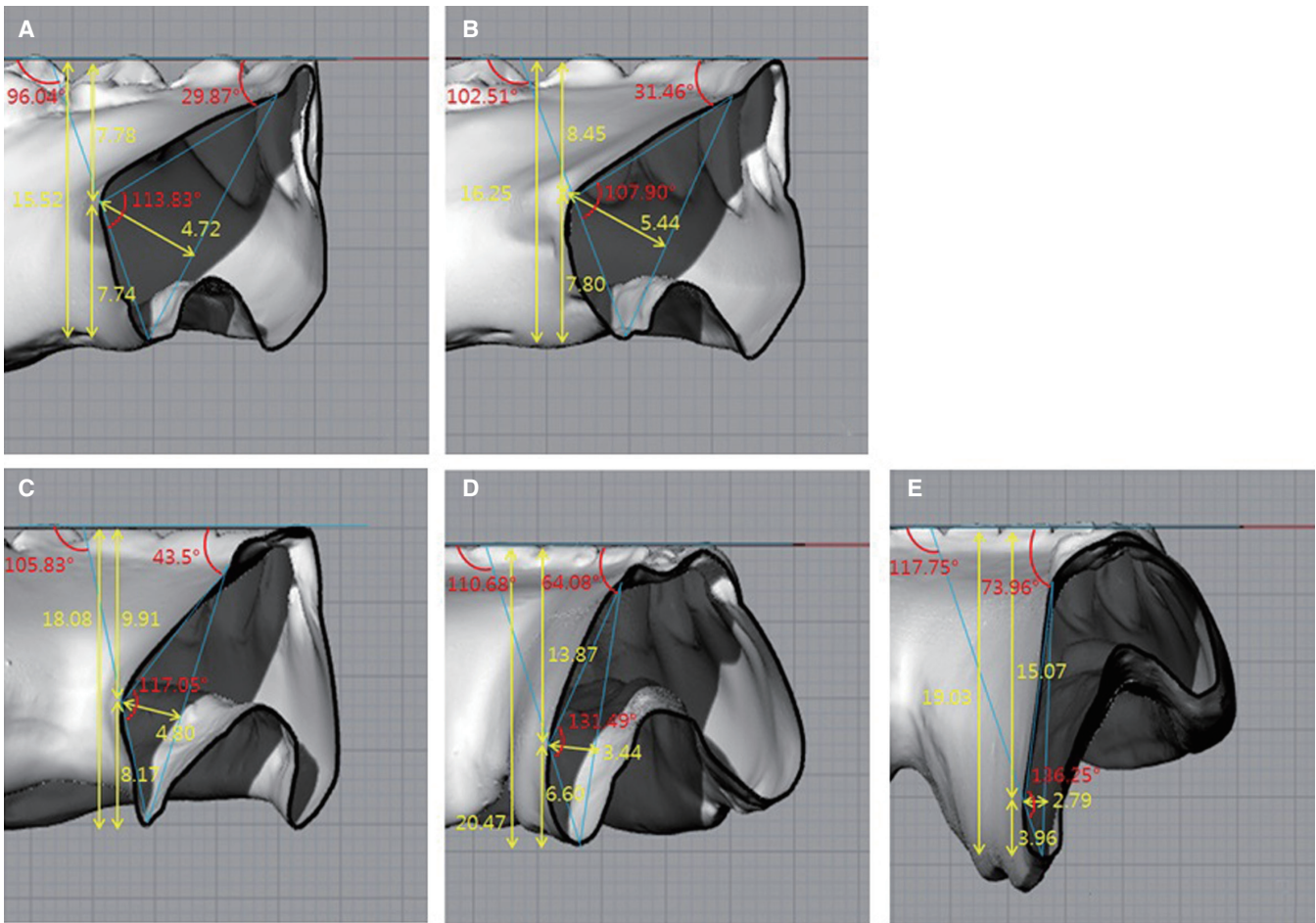


Fig. 5. Contour and mean values of each region. (A) lingual frenum, (B) lateral incisor, (C) first premolar, (D) first molar, (E) anterior border of retromolar pad.

plane was 29.87° (F). The angle was smaller than that in any other region, and was a horizontal form upon which the tongue can rest. The angle from the height of the contour, where the movement of the base of the tongue occurs to the lingual border was 96.04° (G), and this inclination formed a 113.83° (H) with the medial inclination.

The polished surface of the lateral incisors also was convex, and similar to the lingual frenum area (Fig. 5B). The lingual height of the contour was positioned at 0.47 ratio (E) in the distance from the occlusal surface to the lingual border. The A value was longer than that in any other region. The F value was 31.46°, which was horizontal and similar to that of the lingual frenum. The H value (107.90°) was the smallest among the H values in all regions.

The cross-section of the first premolar was slightly convex (Fig. 5C). The E value was 0.45 ratio, which was not significantly different from that of the lingual frenum or lateral incisor. The F value was 43.5°, which was significantly greater than that of the lateral incisor ($P < .01$). Compared with the anterior regions, the horizontal shape was not as

prominent. The H value was 117.05°, which was significantly greater than that of the lateral incisor ($P < .01$). The distance from the occlusal plane to the lingual border was 18.08 mm, which was significantly greater than those of the lingual frenum and lateral incisor ($P < .01$).

The cross-section of the first molar region was flat (Fig. 5D). The E value was 0.32 ratio, and gradually moved toward the inferior region. The F value was 64.08°, and showed a significant increase and a straighter line. The H value (131.49°) was also significantly increased ($P < .01$), with the angle becoming more linear. The D value (20.47 mm) was the longest among the D values in all regions.

The anterior border of the retromolar pad was the flattest among those in all regions (Fig. 5E). The E value was 0.2 ratio, and was positioned at the most inferior point. The A value (2.79 mm) was the smallest among the A values in all region. The F value (73.96°) was significantly the greatest ($P < .01$), and the H angle (136.25°) was closest to a straight line.

DISCUSSION

The A value represents how medial the height of the contour is. There was no statistically significant difference in the A value for the lingual frenum, lateral incisor, or first premolar, but the values of A significantly decreased for the first molar and the anterior border of the retromolar pad ($P < .01$). This means that the height of the contour was more medially positioned and more convex in the anterior regions, and became more flat in the posterior regions. The values of D for the lingual frenum and lateral incisor were shorter than other region. The D value gradually increased to reach the greatest at the first molar, and slightly decreased at the anterior border of the retromolar pad. This is because the lingual frenum and sublingual fold may move upward in the anterior regions, and the vestibule is deeper in the posterior regions than in the anterior regions. It also means that tongue movement has a lesser effect on the inferior length of the polished surface in the posterior regions. The values of E for the lingual frenum, lateral incisor, and first premolar were 0.49, 0.47 and 0.45 ratio, respectively, and were reduced toward the first molar and anterior border of the retromolar pad 0.32 and 0.20 ratio, respectively. This shows that the height of the contour of the polished surface was at the halfway point between the occlusal plane and lingual border at the lingual frenum, lateral incisor, and first premolar, but moved in a more inferior direction and reached the one-fifth point at the anterior border of the retromolar pad. The F value was the smallest at the lingual frenum (29.87°) and the largest at the retromolar pad (73.96°). This means that the lingual inclination from the occlusal plane to the lingual height of the contour was horizontal at the lingual frenum and lateral incisor, but gradually became vertical. This is presumed to be due to the fact that the tongue is minimally attached and has a wide range of movement in the anterior region, and the inferior space that is created during tongue movement is taken into account in the impression of the polished surface. In addition, the wider attachment of the tongue in the posterior region makes the lateral side of the tongue thicker, which would make the lateral force stronger, resulting in a vertical shape. The values for G were all greater than 90° , and increased as it moved posteriorly. The H values were significantly larger at the first molar and anterior border of the retromolar pad than at the lingual frenum, lateral incisor, and first premolar ($P < .01$). This shows that the lingual polished surface approached 180° in the more posterior regions, and became nearly flat.

The lingual polished surface had different shapes in each region. In the anterior regions, the lingual height of the contour was at about the halfway point between the occlusal surface and the lingual border, and F values (29.87° and 31.46°) were more horizontal than in the posterior regions. This differed from the arguments of Tuckfield¹⁰ and Tillman¹¹ that it should be slightly concave for the tongue to rest, and was similar to the shelf shape reported by Srivastava *et al.*⁶ Such a shape is predicted to help maintain and stabilize the denture by enabling the tongue to be positioned in

the anterior region. The H values (113.83° and 107.90°) were smaller in the anterior regions than in the posterior region. This is presumed to have resulted from the base of the tongue moving the sublingual fold toward the anterior regions, which signifies that the tongue's base movement is larger in the anterior regions than in the posterior regions. The height of the contour at the first premolar, where the premylohyoid fossa is located, was at a point slightly inferior to the halfway point. The values of F and G were 43.50° and 105.83° , respectively, which were slightly larger than those in the anterior regions. The anterior and premolar regions were both close to a convex shape. The height of the contour in the first molar region, where the mylohyoid muscle is located, was in the inferior region (about the one-third point). The F value was significantly increased ($P < .01$). And the H value was significantly larger than those at the lingual frenum, lateral incisor, and first premolar ($P < .01$). This shows that the polished surface was less convex and more flat than in the anterior regions. The height of the contour at the anterior border of the retromolar pad, where the retromylohyoid fossa is located, was at the most inferior point (about the one-fifth point). The F value was largest at the retromolar pad, which was closest to a vertical shape. The H value was also the largest. The D value was more slightly decreased than at the first molar, but there was no significant difference. The polished surface in the posterior regions became flat as it moved from the first molar to the anterior border of the retromolar pad. This is presumed to be due to the fact that the lateral and basal sides of the tongue are in contact with the polished surface, limiting its thickness.¹⁷ The shape of the polished surface in the posterior regions acquired in the present study was similar to the flat shape described by Raybin,⁹ Tuckfield,¹⁰ and Tillman,¹¹ but different from the concave shape reported by Sussman¹³ and Block.¹⁴

The shapes of polished surfaces as suggested by this study could be utilized for designing lingual shapes for edentulous trays needed for taking a preliminary impression for lower complete dentures. Furthermore, these findings could be used as a reference when taking impressions of patients' polished surfaces.

The curvature of the polished surface varies in different regions. Even the right and left curvatures within the same patient are not identical. A limitation of this study was the linearization and expression of irregular curves as numbers. Additional studies on the expression of curves are needed.

The present study surveyed the lingual polished surface, which is larger and has more effects on the retention and stability of dentures compared to the buccal surface. In the future, researchers should examine not only lower buccal polished surfaces, but also upper polished surfaces. Furthermore, more studies should examine whether there are differences in shapes depending on impression techniques. In addition, reproducible polished surface impression techniques should be developed through research on whether impressions are taken differently in accordance with the impression material, amount of impression material, and the use of pronuncia-

tion and swallowing movements.

CONCLUSION

In the anterior regions, the height of the contour was at the midpoint and had a convex, shelf-like shape. The first premolar region was slightly convex. In the posterior regions, the height of the contour gradually moved downward to take on a flat shape.

ORCID

Yu-Ri Heo <http://orcid.org/0000-0002-1806-3822>

Hee-Jung Kim <http://orcid.org/0000-0002-2015-1530>

Mee-Kyoung Son <http://orcid.org/0000-0001-9225-1744>

Chae-Heon Chung <http://orcid.org/0000-0003-1089-2885>

REFERENCES

1. Jacobson TE, Krol AJ. A contemporary review of the factors involved in complete denture retention, stability, and support. Part I: retention. *J Prosthet Dent* 1983;49:5-15.
2. Beresin VE, Schiesser FJ. The neutral zone in complete dentures. *J Prosthet Dent* 1976;36:356-67.
3. Bohnenkamp DM, Garcia LT. Phonetics and tongue position to improve mandibular denture retention: a clinical report. *J Prosthet Dent* 2007;98:344-7.
4. Brill N, Tryde G, Cantor R. The dynamic nature of the lower denture space. *J Prosthet Dent* 1965;15:401-18.
5. Shanahan TEJ. Stabilizing lower dentures on unfavorable ridges. *J Prosthet Dent* 1962;12:420-4.
6. Srivastava V, Gupta NK, Tandan A, Kaira LS, Chopra D. The neutral zone: Concept and technique. *J Orofac Res* 2012;2:42-7.
7. Fish EW. Principles of full denture prosthesis. London; John Bale, Sons&Danielsson, Ltd ; 1933. p. 1-8.
8. Neill DJ, Glaysheer JK. Identifying the denture space. *J Oral Rehabil* 1982;9:259-77.
9. Raybin NH. The polished surface of complete dentures. *J Prosthet Dent* 1963;13:236-9.
10. Tuckfield WJ. The problem of the mandibular denture. *Dent J Aust* 1951;23:331-54.
11. Tillman EJ. Removable partial upper and complete lower dentures. *J Prosthet Dent* 1961;11:1098-104.
12. Kwon KR, Kim YS, Kim CH, Kim HJ, Moon HS, Park SW, Park CJ, Song KY, Lee JS, Lee CH, Lim YJ, Jung MK, Chung CH, Jung CM, Cho IH, Cho HW, Choi DK, Han JH. Prosthodontic treatment for edentulous patient. Seoul; Shinhung International, Inc; 2007. p. 323.
13. Sussman BA. Procedures in complete denture prosthesis. *J Prosthet Dent* 1960;10:1011-21.
14. Block LS. Common factors in complete denture prosthetics. *J Prosthet Dent* 1953;3:736-46.
15. Starcke EN Jr. The contours of polished surfaces of complete dentures: a review of the literature. *J Am Dent Assoc* 1970;81:155-60.
16. Cagna DR, Massad JJ, Schiesser FJ. The neutral zone revisited: from historical concepts to modern application. *J Prosthet Dent* 2009;101:405-12.
17. Kolb HR. Variable denture-limiting structures of the edentulous mouth. II. Mandibular border areas. *J Prosthet Dent* 1966;16:202-12.