

## Diaphragm Translocation as Surgical Treatment for Agenesis of the Right Lung and Secondary Tracheal Compression

Dong Hee Kim, M.D., Se Hoon Choi, M.D.

A 12-month-old boy was diagnosed with agenesis of the right lung. Mediastinal deviation progressed to the diseased side as the patient matured; therefore, tracheal distortion developed. As a result, tracheal compression developed between the vertebral body and aorta. The patient was repeatedly admitted to the hospital because of recurrent pulmonary infection and combined severe respiratory distress. Diaphragm translocation was performed to treat the patient. The postoperative course was favorable, and computed tomography scan findings and symptoms had improved at 1 year after surgery.

Key words: 1. Diaphragm translocation  
2. Lung agenesis  
3. Lung anomaly

### CASE REPORT

A 12-month-old boy was admitted to the hospital because of recurrent pulmonary infection and combined severe respiratory distress. The patient had already been diagnosed with congenital pulmonary agenesis on the right side based on prenatal ultrasonography and a postnatal computed tomography (CT) scan. After admission, a follow-up CT scan and bronchoscopy were performed to evaluate the condition of the lung and trachea and their relationship with surrounding structures. Bronchoscopy found tracheal narrowing at the level of the aortic arch, and chest CT confirmed that the trachea was compressed between the aortic arch and the spine. We thought that the patient's respiratory distress was caused by extrinsic tracheal compression. The cause of tracheal stenosis was mediastinal deviation that developed due to congenital lung agenesis (Fig. 1). To relieve mediastinal deviation, dia-

phragm translocation was performed.

The operation was performed under general anesthesia, with the patient in the left lateral decubitus position. Posterolateral thoracotomy was performed at the level of the sixth intercostal space (ICS), and an additional mini-thoracotomy incision was made at the level of the ninth ICS to facilitate identification of the margin of the diaphragm. We approached the thorax through the extrapleural space. Upon evaluation of the pleural space, the parietal pleura and mediastinal pleura were found to be intact, although no structure was associated with the lung and bronchus in the pleural space. The diaphragm was detached along the costal margin, from the sternum to the spine. The peritoneum was preserved in the costal area; however, around the tendinous portion of the diaphragm, the peritoneum needed to be dissected for sufficient mobilization of the diaphragm. Several interrupted Prolene sutures reinforced with pledgets were applied to an-

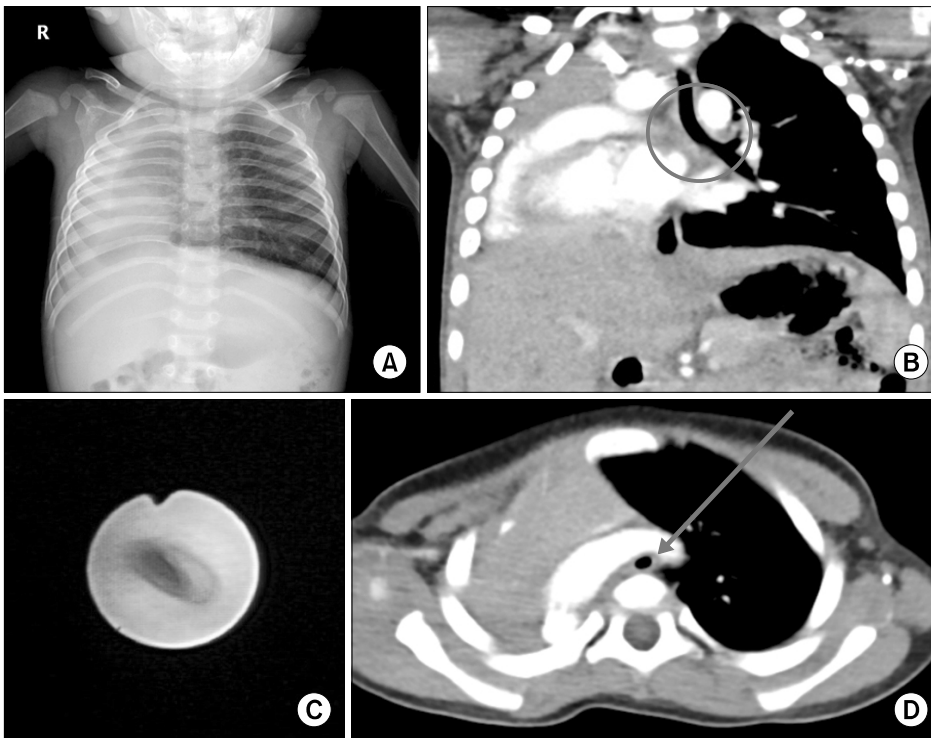
Department of Thoracic and Cardiovascular Surgery, Asan Medical Center, University of Ulsan College of Medicine

Received: April 6, 2015, Revised: June 19, 2015, Accepted: June 23, 2015, Published online: February 5, 2016

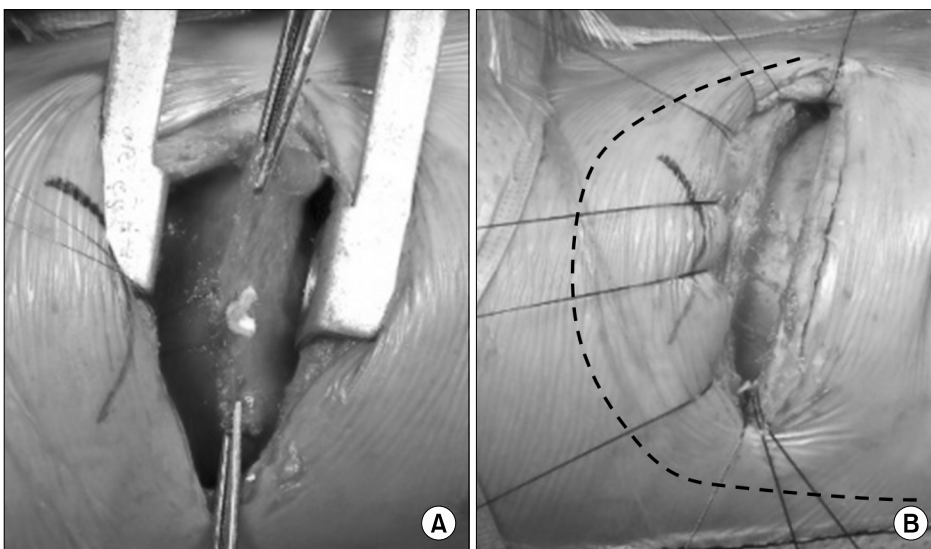
Corresponding author: Se Hoon Choi, Department of Thoracic and Cardiovascular Surgery, Asan Medical Center, University of Ulsan College of Medicine, 88 Olympic-ro 43-gil, Songpa-gu, Seoul 05505, Korea  
(Tel) 82-2-3010-3904 (Fax) 82-2-3010-6966 (E-mail) [choishn@gmail.com](mailto:choishn@gmail.com)

© The Korean Society for Thoracic and Cardiovascular Surgery. 2016. All right reserved.

© This is an open access article distributed under the terms of the Creative Commons Attribution Non-Commercial License (<http://creativecommons.org/licenses/by-nc/4.0>) which permits unrestricted non-commercial use, distribution, and reproduction in any medium, provided the original work is properly cited.



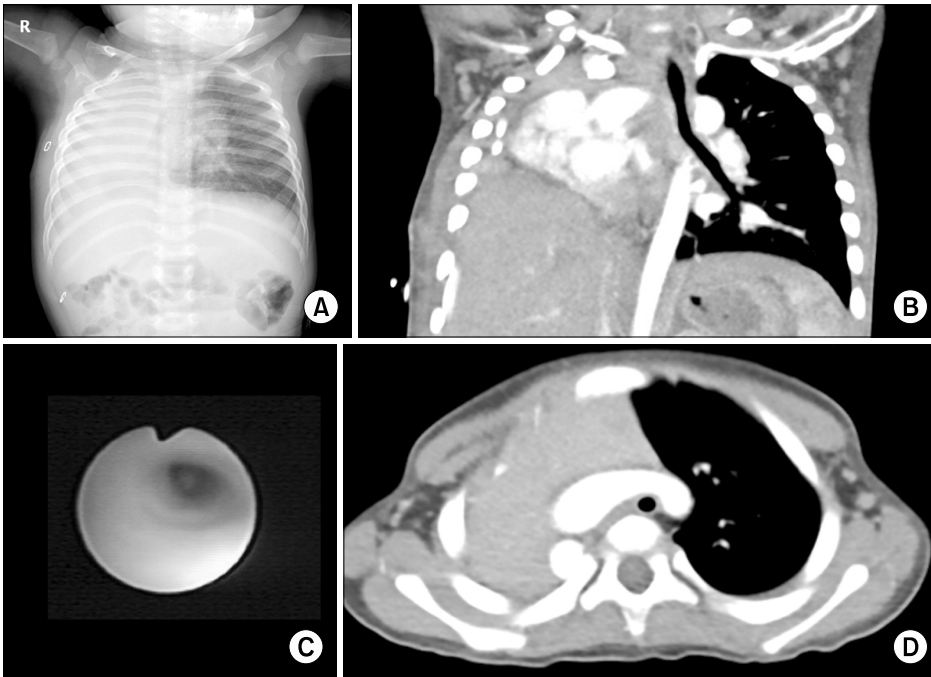
**Fig. 1.** (A) Chest radiography before the operation. (B) Right lung agenesis (circle). Note that the left bronchial stump was missing. (C, D) Combined tracheal compression between the vertebral body and aortic arch was found on a computed tomography scan and by bronchoscopy (arrow).



**Fig. 2.** (A) The resected diaphragmatic margin and anchoring sutures are shown. (B) After anchoring the harvested diaphragm to the chest wall, the diaphragm was fixed at the third rib level laterally, at the fourth rib level anteriorly, and to the adjacent ribs posteriorly (the dotted line shows the site of fixation).

chor the harvested diaphragm to the chest wall. The diaphragm was fixed at the level of the third rib laterally, at the level of the fourth rib anteriorly, and to the adjacent ribs posteriorly to achieve tension-free attachment of the diaphragm (Fig. 2). Finally, two separate soft drains were inserted into the pleural cavity and peritoneal cavity. No unexpected events occurred during the operation.

The patient was transferred to an intensive care unit (ICU) with mechanical ventilation because he had suffered severe preoperative respiratory distress due to a large volume of secretions. The following day, the patient was extubated and the drains were removed at postoperative day 12. The postoperative course was favorable; however, bronchitis developed and the patient suffered from a large amount of sputum and



**Fig. 3.** (A) Chest radiography at discharge. (B–D) A computed tomography scan and bronchoscopy showed that the mediastinal structure was moved to the cranial position and tracheal narrowing had improved after the operation.

mild dyspnea. The patient received conservative care at the ICU and was transferred to a general ward at postoperative day 7. A follow-up CT scan performed on postoperative day 14 revealed improved mediastinal and tracheal deviation. Furthermore, because of the rearrangement of the mediastinal structure, tracheal narrowing seemed to have improved. The patient was discharged on postoperative day 17 without any complications. The patient underwent follow-up at the outpatient department until 1 year after surgery. A follow-up CT scan and bronchoscopy revealed improvement of the tracheal narrowing (Fig. 3), and the patient's symptoms were much improved.

## DISCUSSION

Congenital lung agenesis is defined as the absence of the lung and pulmonary vasculature on the affected side with preservation of the carina and main-stem bronchus. In this condition, mediastinal deviation can progress to the diseased side, which can cause kinking of the great vessels and trachea. Possible symptoms include tachypnea, dyspnea, and cyanosis. Furthermore, as mediastinal deviation develops, air trapping in the contralateral lung and severe respiratory dis-

tress can occur due to the tracheal abnormality [1,2]. Moreover, recurrent infections such as pneumonia or bronchitis may cause retention of bronchial secretions, and as a result, respiratory distress worsens and may lead to mortality.

There is no specific treatment for this condition. Numerous medical treatments for repeated respiratory infections and distress have been applied, such as ventilator management, extracorporeal membrane oxygenation, and appropriate antibiotic management, all of which control respiratory infection. In 1995, Becmeur et al. [3] attempted to reduce mediastinal deviation surgically for the first time. An inflatable prosthesis was inserted into the diseased pleural cavity. However, the patient suffered severe scoliosis until the prosthesis was removed. Another surgical attempt was made to reduce secondary problems arising from mediastinal shifting, such as extrinsic tracheal compression or kinking. Dohlemann et al. [4] performed aortopexy and its result was favorable. However, in patients with this condition, such as those with pulmonary agenesis, pulmonary aplasia, or postpneumectomy syndrome, the left main bronchus is compressed between the right main pulmonary artery, vertebral column, and aorta. Aortopexy only relieves compression by the aorta and cannot change the underlying condition of mediastinal shift-

ing; therefore, relapse is a considerable problem as patients mature. Moreover, hyperinflation, which is a result of mediastinal deviation and air trapping distal to the compressed bronchus that cannot be repaired by aortopexy, is another problem that compromises functional status. Diaphragm translocation was first attempted by Krivchenya et al. [5] in 1995, and the results of this operation were published in 2000. The diaphragm was translocated in the cephalad direction to reduce the empty hemithorax cavity, and the result seemed favorable. This operation was first used to reduce the dead space after pulmonary resection. We also considered aortopexy and prosthesis implantation; however, we decided to perform diaphragm translocation because the patient was only 1 year old, and the growth potential of the patient might be an important factor in ensuring good long-term results. The outcome appeared to be satisfactory as of the last follow-up. To our knowledge, this is the first case of diaphragm translocation in Korea.

In conclusion, we report a case of pulmonary agenesis, which was successfully treated by diaphragm translocation. To further verify the feasibility and reproducibility of diaphragm translocation, reports of a larger number of patients with long-term follow-up will be required.

## CONFLICT OF INTEREST

No potential conflict of interest relevant to this article was reported.

## REFERENCES

1. Valle AR. *Agenesis of the lung*. Am J Surg 1955;89:90-100.
2. Othersen B. *Lung and bronchial abnormalities*. In: Ashkraft KU, Holder TM, editors. *Pediatric surgery*. Harford: St-Petersberg; 1996. p. 209.
3. Becmeur F, Horta P, Christmann D, et al. *Mediastinal stabilization by an expansion prosthesis in postoperative congenital diaphragmatic hernia with severe pulmonary hypoplasia*. Eur J Pediatr Surg 1995;5:295-8.
4. Dohlemann C, Mantel K, Schneider K, Guntner M, Kreuzer E, Hecker WC. *Deviated trachea in hypoplasia and aplasia of the right lung: airway obstruction and its release by aortopexy*. J Pediatr Surg 1990;25:290-3.
5. Krivchenya DU, Dubrovin AG, Krivchenya TD, Khursin VN, Lysak CV. *Aplasia of the right lung in a 4-year-old child: surgical stabilization of the mediastinum by diaphragm translocation leading to complete recovery from respiratory distress syndrome*. J Pediatr Surg 2000;35:1499-502.