

잠행 고관절 골절의 진단 지연의 결과

인제대학교 의과대학 상계백병원 응급의학과

제상봉, 김혜진, 류석용, 조석진, 오성찬, 강태경, 최승운

- Abstract -

The Consequence of Delayed Diagnosis of an Occult Hip Fracture

Sangbong Je, M.D., Hyejin Kim, M.D., Seokyong Ryu, M.D., Ph.D., Sukjin Cho, M.D.,
Sungchan Oh, M.D., Taekyung Kang, M.D., Seungwoon Choi, M.D.

Department of Emergency Medicine, Inje University Sanggye Paik Hospital, Seoul, Korea

Purpose: Occult hip fracture is not evident on radiographs and the diagnosis is often missed or delayed. This study was undertaken in order to identify the clinical characteristics and complications of patients with a delayed diagnosis of an occult hip fracture.

Methods: We retrospectively reviewed patients with occult hip fracture who had normal findings on initial radiographs, the diagnosis was made on additional studies between August 2006 and February 2012. Patients who were diagnosed as having occult hip fractures at the first visit were categorized as non-delayed group and those who were not diagnosed at the first visit were categorized as delayed group.

Results: Non-delayed group included 43 patients (86%). In the remaining 7 patients (delayed group), the diagnosis was delayed by a mean of 9.6 days (range 3 ~ 19 days). Patients who were diagnosed with an occult fracture on the initial visit presented later than those with a delayed diagnosis (41/43 .vs. 3/7, $p=0.002$). Other clinical features were no difference between the two groups. Patients in the delayed diagnosis group were more likely to have fracture displacement (4/7 .vs. 0/43) 15 patients in non-delayed group (34.9%) needed operative treatment, whereas all delayed patients (100%) needed operative treatment.

Conclusion: A delayed diagnosis of occult hip fractures was associated with increased rate of displacement and operation. In patients suspected of having occult hip fractures, additional studies should be recommended. [J Trauma Inj 2015; 28: 91-97]

Key Words: Complications, Emergency room, Hip fractures

* Address for Correspondence : **Hyejin Kim, M.D.**

Department of Emergency Medicine, Inje University Sanggye Paik Hospital,
1342 Dongil-ro, Nowon-gu, Seoul, Korea

Tel : 82-2-950-1119, Fax : 82-2-950-1932, E-mail : veauvoir@paik.ac.kr

Submitted : April 12, 2015 Revised : May 17, 2015 Accepted : October 4, 2015

I. Introduction

Hip fracture in elderly patients are quite commonly seen in emergency department. There are reports that the patients with hip fractures contribute about 20% of patients who are admitted to the orthopedic surgery department which accumulate to substantial medical costs in result.(1,2) It is also known that hip fractures are correlated with high morbidity rate and high mortality among elderly patients.(3)

Because the integrity of hip joint is inevitable to daily activities, it is important to detect hip fractures accurately when suspected.

In which cases where there are hip fractures with displacements, proper history taking, physical examination and simple x-ray tests will suffice in about 90% of cases. But the x-ray tests of elderly patients with osteoporosis or x-ray tests of patients with non-displaced hip fractures might appear normal in its initial presentation and it could lead to delay in detecting hip fractures.(4-6) It is reported that about 2% of all the hip fractures are not diagnosed by simple x-rays.(7-9)

Also the experience of the emergency physician might vary and the stressful environment of emergency department might also add to difficulty in detecting hip fractures briskly. When hip fractures are not found in initial x-ray but detected later by follow up x-ray or computed tomography (CT), bone scanning, magnetic resonance imaging (MRI) or when it is detected during the operation it is named occult hip fractures.(10)

Discharging patients with potential occult hip fractures could lead to increased risk of hip displacement and resultant elevated probability of avascular necrosis of femoral head and its complication might contribute to the higher risk in future operations. Furthermore this delay could lead to unwanted pain, higher mortality, mal-union, rise of pulmonary thromboembolism and higher mortality. And as more time is delayed the higher the morbidity and mortality becomes. There is a report that a delay of 2 days in an operable case could lead to two fold increase in mortality rate.(11)

Despite the advances in modern medical science and technology, the 1 year mortality of a hip fracture

patient is reported about 15~35% and in 25~50% of the patients who survive after the first year do not recoup their pre-trauma activeness.(12-14)

Our goal was to compare the clinical characteristics of patients with an occult hip fracture diagnosed on the initial visit compared to those with a delayed diagnosis.

II. Materials and methods

We enrolled patients who were hospitalized for the management of femoral neck fracture, intertrochanteric fracture, trochanteric fracture or acetabular fracture at our medical institution through a retrospective analysis of the medical records between August 2006 and February 2012.

Patients who visited an emergency care center with a chief complaint of hip joint pain at the initial visit were screened.

Patients who were diagnosed as having occult hip fractures at the first visit were categorized as non-delayed group. Those who were not diagnosed at the first visit were categorized as delayed group. They re-visited emergency department or outpatient clinic after a period of time. We excluded patients who were transferred to other hospitals and those who were diagnosed with pelvic bone fracture (Fig. 1).

We evaluated the age of patients, sex, accident mechanism, body mass index (BMI), previous fracture, pre-fracture mobility, late presentation, able to bear weight, pain on passive rotation, tenderness on groin area, diagnosis, displacement of fracture and treatment. We defined late presentation is presented next day after injury.

Imaging studies were interpreted by a board-certified specialist in radiology.

Causes of injury were classified into a high-energy injury and a low-energy injury. A high-energy injury was defined as an injury where there is a high possibility that multiple organs might be damaged due to such mechanisms as falling, traffic accident and direct blow. A low-energy injury was defined as an injury which patients would sustain while falling over slippery ground in a walking or sitting position.(15)

We compared the baseline characteristics, a past history, physical examination, the displacement of hip fracture and the treatment regimens.

All data was expressed as mean±SD (SD: standard deviation). Statistical analysis was performed using SAS Enterprise Guide (version 4.2, SAS Institute, Cary, NC). We compared the mean values between the different groups using the independent sample t-test. In addition, we analyzed the categorical variables using the Chi-square test or Fisher's exact test. A p-value of <0.05 was considered statistically significant.

III. Results

1. Baseline characteristics of the patients (Fig. 1)

The total number of patients with hip fracture

during the study period was 772. Of these, 50 patients were diagnosed with occult hip fracture. The Incidence of occult fracture was 6.5% in femoral neck and intertrochanteric areas.

In 43 patients, occult hip fracture was suspected at the first visit of patients and the diagnosis was made on CT.

In the remaining 7 patients, the diagnosis was delayed by mean of 9.6 days (range, 3~19 days).

5 patients of delayed group were diagnosed on a plain radiography at a follow-up, one did on bone scan and one did on CT. Five patients were not diagnosed with fracture although they underwent CT at the initial visit.

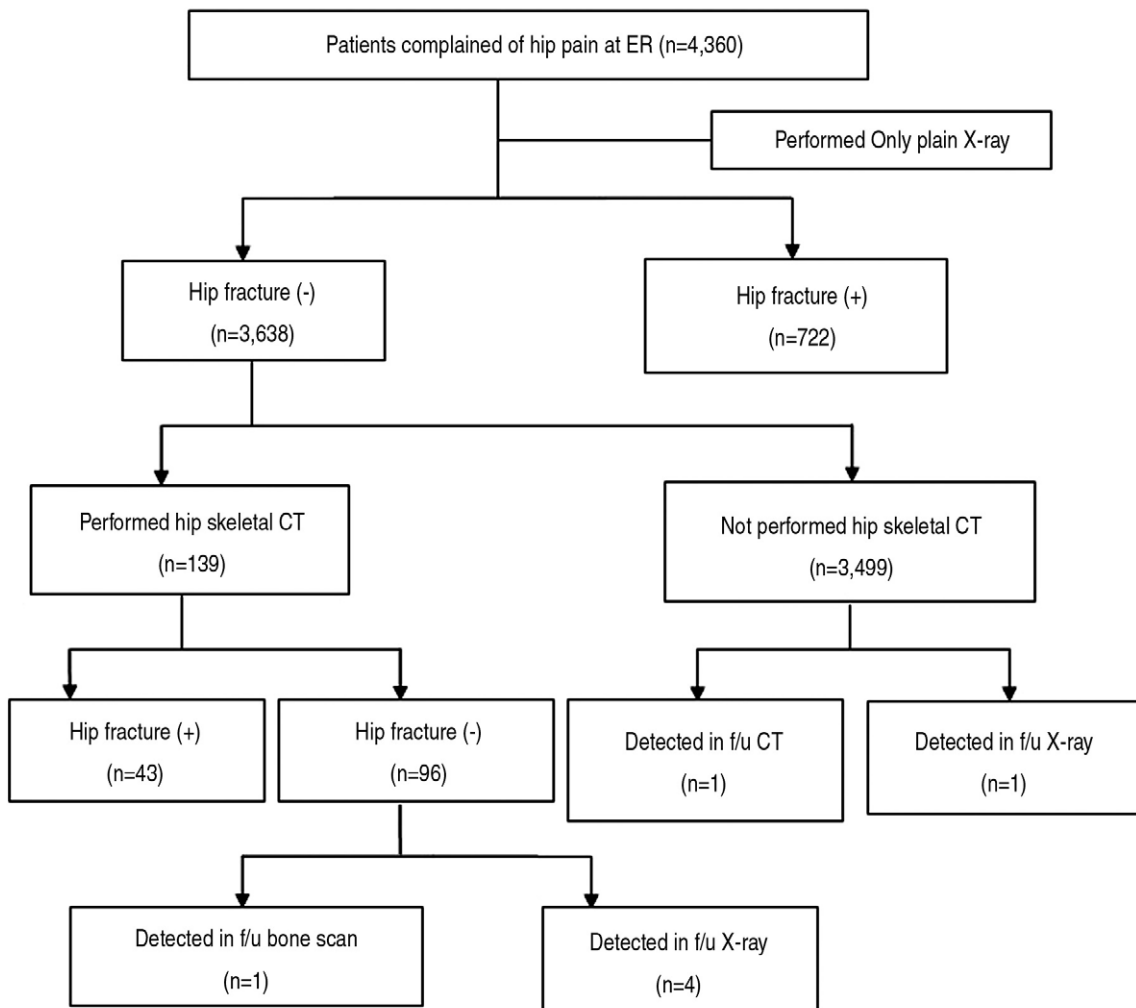


Fig. 1. Flow diagram of the study participants.

Hip fracture was included femur neck fracture, intertrochanter fracture, subtrochanter fracture, acetabular fracture.

Hip fracture (+): patients diagnosed with hip fracture

Hip fracture (-): patients were not diagnosed with hip fracture

f/u: follow up

2. Patient characteristics of the patients with occult hip fracture (Table 1)

In a total of 50 patients who were diagnosed with occult hip fracture, the mean age was 63.9 years. 20

Table 1. demographic characteristics of study subjects.

Variables	Frequency, n
Age* (years)	63.86 ± 20.30
Sex (female:male)	30:20
BMI* (kg/m ²)	24.18 ± 3.78
Accident mechanism	
high energy injury	14
low energy injury	36
Previous fracture	10
Pre-fracture independence	2
Late presentation	44
Ability to bear weight	1
Pain on passive rotation	47
Tenderness on groin area	39
Type of fracture	
Femoral neck	13
Intertrochanteric or trochanteric	22
acetabular	15
Treatment	
Conservative	28
operative	22
Displacement of fracture	4

* The result are expressed as mean ± standard deviation
 BMI: body mass index

patients (40%) were men. 14 patients sustained a high-energy injury. 10 patients had a past history of fracture.

There were 44 patients who did not visit our medical institution at the time of the onset of injury. There was one patient who had a weight-bearing ability and could perform a gait. There were 47 patients who complained of pain during the passive rotation of the hip joint. There were 39 patients who presented with inguinal tenderness. There were 22 patients who had intertrochanter fracture or trochanteric one. There were 13 patients with femoral neck fracture. There were 15 patients with acetabular fracture.

3. Comparison of the patient characteristics between the delayed group and the non-delayed group (Table 2)

There were no significant differences in the age, sex, accident mechanisms, BMI, previous fracture and pre-fracture mobility between the two groups. In addition, there were also no significant differences in the weight-bearing ability, pain on passive rotation and tenderness on groin area between the two groups. But late presentation after event were seen in 3 patients of the delayed group and 41 patients of the non-delayed group, which was a statistically significant difference ($p=0.002$).

Table 2. Baseline characteristics between the non-delayed group and delayed group.

	Non-delayed group (n=43)	Delayed group (n=7)	p value
Mean age (years)	64.4 ± 19.1	60.6 ± 28.2	0.740
Sex (female:male)	25:18	5:2	0.410
BMI (kg/m ²)	25.0 ± 3.8	22.0 ± 3.1	0.086
Accident mechanism			
low energy injury	29	7	0.084
high energy injury	14	0	
Previous fracture	9	1	0.571
Pre-fracture independence	2	0	0.737
Late presentation	41	3	0.002
Ability to bear weight	0	1	0.140
Pain on passive rotation	40	7	0.630
Tenderness on groin area	35	4	0.170
Type of fracture			
femoral neck	8	5	
inter- or trochanteric	21	1	
acetabular	14	1	

BMI: body mass index

4. Comparison of the morbidity and treatment between the delayed group and the non-delayed group (Table 3)

The displacement of the hip fracture was seen in 4 of seven patients of the delayed group and in no patients of the non-delayed group. 15 patients of the non-delayed group and all patients of the delayed group underwent surgical treatment, which was a statistically significant difference ($p=0.002$).

IV. Discussion

The occult hip fractures are sometimes missed initially and they are detected later on. Because the hip fractures might seem normal in their initial x-rays and some patients might be able to ambulate and at times the trauma vector can be minor to be noticed.(3) There was a report that occult hip fractures consist 2~10% of all hip fractures.(7) In the present study, the incidence of occult hip fracture was 6.5%.

To miss the diagnosis of an occult hip fracture may lead to displacement of the fracture and otherwise unnecessary surgery.(11,16) In a prospective study of 90 elderly patients with an acute hip fracture treated with internal fixation, Tidermark et al. found a major difference in outcome between undisplaced and displaced fractures.(11) The rate of fracture healing complications and reoperations in patients with displaced fractures was high, and even in patients with uneventfully healed fractures, there was a substantial decrease in the quality of life.(3)

Many have reported that there were serious complications resulting from delayed diagnosis of the occult hip fractures.(12-14) Non-union of bones and avascular necrosis might be induced and it could lead to extension of admission days and cause

unwanted complications or longer term of rehabilitation(12,17) and even undesirable operation due to secondary bony displacements.(14,18) And the patients with bone displacements are known to have worse outcome than those without displacements.

In our study, 7 patients of total 50 patients who were diagnosed with occult hip fracture were not diagnosed with fractures in their initial visits to emergency department. In above stated 7 patients with occult hip fractures 4 patients had displacements and all 7 patients required operation. The average length of stay for non-delayed group and for delayed group was 12 days and 24.6 days each. But, there were no serious complications in delayed occult hip fracture group.

In comparison between delayed occult hip fracture groups and non-delayed group, the time delayed in visiting emergency department (late presentation) was the only factor statistically different between two groups ($p<0.002$). This difference is likely due to bone remodeling which could have occurred during the time difference and it could have lowered the probability of being detected precisely.

The patient who was late presentation after the occurrence of event in emergency department was become bone remodeling, then they increased the probability of being detected fracture at the first visit.

Hence we should evaluate possible hip fracture patients with supplementary measures. There were several attempts to establish systematic approach and algorithm for potential hip fracture patients who had no definite fractures but complained of hip pains. There was a report that MRI (magnetic resonance imaging) examination is more accurate than any other imaging modalities.(4,6) But, in reality carrying on MRI test has its restrictions. Not all hospitals can afford costly MRI machines and even in those hospitals where they can, the radiologist

Table 3. Fracture displacement, treatment modality of the two groups.

	Non- delayed group (n=43)	Delayed group (n=7)	p value
Displacement of fracture	0	4	NA
Treatment			
Conservative	28	0	
operative	15	7	0.002

NA: not applicable

might not be available after regular working hours. Also there are absolute contraindications to MRI tests, such as patients with pacemakers or patients with metallic implants. A patient who is uncomfortable with closed space or is in harsh pain will have difficulties due to relatively long time absorbed in the test

CT could be a second option because modern CT technology has improved significantly and the CT imaging study is comparably readily executed in emergency room settings and almost all hospitals run CT test on 24 hour bases. The multidetector CT technology has also reduced the radiation exposures such that the exposure amount is relatively small for adults and old aged patients.(19,20) The CT images now have higher resolutions and are more readily available. In recent studies they have shown that it is almost equally accurate as an MRI test and they agree that fracture can be diagnosed with very high level of certainty.(21)

Gillet al. reported the use of multislice CT scanning and suggests it has a role to play in the investigation of occult hip fractures. CT scanning has wide spread availability out of hours and lower cost when compared to MRI scanning. They showed that the proportion of scans in each modality that showed a fracture was similar (38% of CT scans, 36% of MRI scans). No MRI or CT scan missed an occult fracture which was then found when the initial X-rays were.(19)

Cabarrus et al. compared CT with MRI for insufficiency fractures in the pelvis and reported 64 cases where MRI and CT could be compared side by side.(22) Cabarrus et al. found that MRI did miss a fracture due to partial volume effects and adjacent joint effusion along with motion artefacts. This fracture was picked up by CT.

Advances in technology, such as 64-slice scanners and sophisticated 3-dimensional reconstruction algorithms, may have made the reliability of CT comparable to that of MRI.

But, there are also reports that the CT test is prone to small impacted fractures or a fracture which is parallel with the axial plane of the CT image.(23) Kim et al stated that there was 1 patient whose hip fracture was missed initially even though they had carried out the CT test. In our study 5

patients had early CT test taken but was not diagnosed with hip fractures. This result may have come from the fact that there are disadvantages in CT test as well.

But, We guess it is because these papers were written before their widespread usage of multislice helical scanners were available.

In our study, five patients were not diagnosed with occult hip fracture although they underwent CT at the initial visit. They had severe osteoporosis or growth plate involvement.

There were several limitations in our study. First, our study was a retrospective one performed in a small cohort. Second, the accuracy of information presented is limited to the accuracy of admission details. An element of observer heterogeneity is also present as different physicians with different levels of experience recorded clinical findings over a 6 and half year period. Third, in our study, a protocol for referral to MRI or CT scans could not be applied in every patient with hip pain after trauma, who had normal or equivocal findings on conventional radiographs during the study period. Fourth, some neglected patients in whom pain was durable and fracture healed without displacement might not have been detected. Fifth, some patients could have gone to other hospitals and might have gotten diagnosed with occult hip fractures.

A prospective study for this occult hip fracture can be executed but because of the relatively small incidence rate of occult hip fractures and of the barriers a MRI protocol intrinsically has it will be challenging to apply.

In result, the patient group who were diagnosed later on as having occult hip fracture had higher rate of hip displacement and all patients in the group received operation.

V. Conclusion

Patient with a delayed diagnosis of occult hip fracture had a higher rate of fracture displacement and need for surgery than those diagnosed on the initial ED visit. Although CT scan detected the occult fracture in most cases, it missed five occult fractures during the initial visit.

REFERENCES

- 1) Thorgren KG. Hip fractures-an enormous public healthproblem. *Lakartidningen* 2006; 103: 2990-2.
- 2) Borgström F, Sobocki P, Ström O, Jönsson B. The societal-burden of osteoporosis in Sweden. *Bone* 2007; 40: 1602-9.
- 3) Kim KC, Ha YC, Kim TY, Choi JA, Koo KH. Initially missed occult fractures of the proximal femur in elderly patients: implications for need of operation and their morbidity. *Arch Orthop Trauma Surg* 2010; 130: 915-20.
- 4) Lubovsky O, Liebergall M, Mattan Y, Weil Y, Mosheiff R. Early diagnosis of occult hip fractures MRI versus CT scan. *Injury* 2005; 36: 788-92.
- 5) Helland EB, Tollefsen I, Reksten G. Radiographic diagnosis of the occult hip fracture: experience in 16 patients. *Acta Orthop Scand* 2000; 71: 639-41.
- 6) Verbeeten KM, Hermann KL, Hasselqvist M, Lausten GS, Joergensen P, Jensen CM et al. The advantages of MRI in the detection of occult hip fractures. *Eur Radiol* 2005; 15: 165-9.
- 7) Dominguez S, Liu P, Roberts C, Mandell M, Richman PB. Prevalence of traumatic hip and pelvic fractures in patients with suspected hip fracture and negative initial standard radiographs-a study of emergency department patients. *Acad Emerg Med* 2005; 12: 366-9.
- 8) Oka M, Monu JU. Prevalence and patterns of occult hip fractures and mimics revealed by MRI. *AJR Am J Roentgenol* 2004; 182: 283-8.
- 9) Perron AD, Miller MD, Brady WJ. Orthopedic pitfalls in the ED: radiographically occult hip fracture. *Am J Emerg Med* 2002; 20: 234-7.
- 10) Nachtrab O, Cassar-Pullicino VN, Lalam R, Tins B, Tyrrell PN, Singh J. Role of MRI in hip fractures, including stress fractures, occult fractures, avulsion fractures. *Eur J Radiol* 2012; 81: 3813-23.
- 11) Moore MN. Orthopedic pitfalls in emergency medicine. *South Med J* 1988; 81: 371-8.
- 12) Bentley G. Treatment of nondisplaced fractures of the femoral neck. *Clin Orthop Relat Res* 1980; 152: 93-101.
- 13) Tidermark J, Zethraeus N, Svensson O, Törnkvist H, Ponzer S. Quality of life related to fracture displacement among elderly patients with femoral neck fractures treated with internal fixation. 2002. *J Orthop Trauma* 2003; 17: S17-21.
- 14) Blickenstaff LD, Morris JM. Fatigue fracture of the femoral neck. *J Bone Joint Surg Am* 1966; 48: 1031-47.
- 15) Nodzo SR, Hohman DW, Galpin RD. Bilateral acetabular fractures in an adolescent after low-energy trauma. *Pediatr Emerg Care* 2012; 28: 568-9.
- 16) Frihagen F, Nordsletten L, Tariq R, Madsen JE. MRI diagnosis of occult hip fractures. *Acta Orthop* 2005; 76: 524-30.
- 17) Zuckerman JD, Skovron ML, Koval KJ, Aharonoff G, Frankel VH. Postoperative complications and mortality associated with operative delay in older patients who have a fracture of the hip. *J Bone Joint Surg Am* 1995; 77: 1551-6.
- 18) Sankey RA, Turner J, Lee J, Healy J, Gibbons CE. The use of MRI to detect occult fractures of the proximal femur: a study of 102 consecutive cases over a ten-year period. *J Bone Joint Surg Br* 2009; 91: 1064-8.
- 19) Gill SK, Smith J, Fox R, Chesser TJ. Investigation of Occult Hip Fractures: The Use of CT and MRI. *Scientific World Journal* 2013; 2013: 830319.
- 20) Memarsadeghi M, Breitensteiner MJ, Schaefer-Prokop C, Weber M, Aldrian S, Gäbler C et al. Occult scaphoid fractures: comparison of multidetector CT and MR imaging-initial experience. *Radiology* 2006; 240: 169-76.
- 21) Collin D, Dunker D, Göthlin JH, Geijer M. Observer variation for radiography, computed tomography, and magnetic resonance imaging of occult hip fractures. *Acta Radiol* 2011; 52: 871-4.
- 22) Cabarrus MC, Ambekar A, Lu Y, Link TM. MRI and CT of insufficiency fractures of the pelvis and the proximal femur. *AJR Am J Roentgenol* 2008; 191: 995-1001.
- 23) Hayes CW, Balkissoon AR. Current concepts in imaging of the pelvis and hip. *Orthop Clin North Am* 1997; 28: 617-42.