

of the breast: working towards a better classification using clinical and radiologic assessment. *Ann Plast Surg* 2006;57:248-51.

The Modified Trap Door Flap for Reconstruction of Posterior Pinna and Concha Defects

Cormac W Joyce¹, Shazarina Sharahan¹,
Padraic J Regan^{1,2}

¹Department of Plastic Surgery, University Hospital Galway, Galway; ²Department of Surgery, National University of Ireland, Galway, Ireland

Correspondence: Cormac W Joyce
Department of Plastic Surgery, Saint Vincent's University Hospital,
27 Rowanbyrn, Blackrock, County Dublin, Ireland
Tel: +353-876815514, Fax: +353-876815514, E-mail: cjoyce78@hotmail.com

No potential conflict of interest relevant to this article was reported.

Received: 17 Dec 2014 • Revised: 12 Jun 2015 • Accepted: 15 Jun 2015
pISSN: 2234-6163 • eISSN: 2234-6171
<http://dx.doi.org/10.5999/aps.2015.42.5.645> • *Arch Plast Surg* 2015;42:645-647

Copyright © 2015 The Korean Society of Plastic and Reconstructive Surgeons
This is an Open Access article distributed under the terms of the Creative Commons Attribution Non-Commercial License (<http://creativecommons.org/licenses/by-nc/3.0/>) which permits unrestricted non-commercial use, distribution, and reproduction in any medium, provided the original work is properly cited.

The trap door flap is an excellent option for reconstruction of anterior pinna and conchal defects. It was first described by the senior author of this paper and it has been carried with excellent results on more than 50 patients in our institution. The flap is a simple one-stage procedure with very little donor site morbidity. Long-term aesthetic outcome is excellent with high patient satisfaction. We report on a modification of this procedure in order reconstruct a defect following excision of a lesion on the posterior aspect of the pinna.

A 90-year-old man was referred to the plastic surgery service with a lesion on the posterior aspect of his left pinna. It had grown significantly since he first noticed it 12 months before. The ulcerated lesion measured 2 cm in diameter (Fig. 1). Clinically, it resembled a squamous cell carcinoma clinically and there was no cervical lymphadenopathy. Under local anaesthetic the lesion was excised with a 4 mm margin and reconstructed with a trap door flap. In this case, we used a modification of the trap door flap

to reconstruct the full thickness defect (Figs. 2–4). The lesion to be excised was marked out with a 4 mm margin. The post-auricular flap was drawn with a diameter equal to the lesion and its margin (Fig. 2). The posterior pinna lesion was excised with underlying cartilage along with skin from the anterior surface of the ear (Fig. 5). This left a full thickness circular defect of the pinna necessitating reconstruction. In the traditional trapdoor flap, the lesion is excised with underlying cartilage but the posterior pinna skin is preserved. A small circular posterior pinna incision is made to accommodate the flap. In our modified trapdoor, a uniform circular excision of cartilage and posterior and anterior pinna skin is made, thus creating a full-thickness defect of the pinna. The flap was subsequently raised and undermined leaving a centrally-based vascular pedicle (Fig. 3). The anterior portion of the flap was first inset to the most medial aspect of the defect so it was then possible to identify where the flap needed further mobilization. The posterior aspect of the flap was

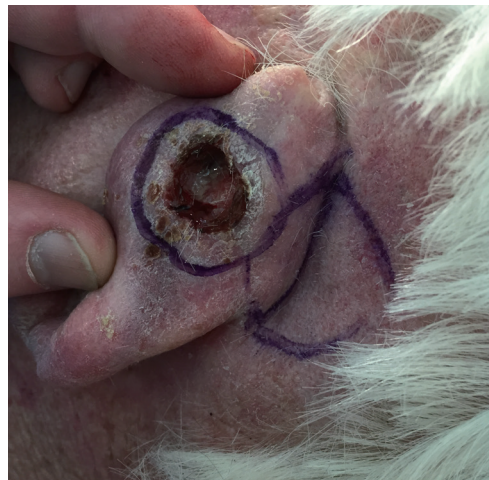

Fig. 1. The lesion on the posterior pinna with the post auricular trap door flap marked out.

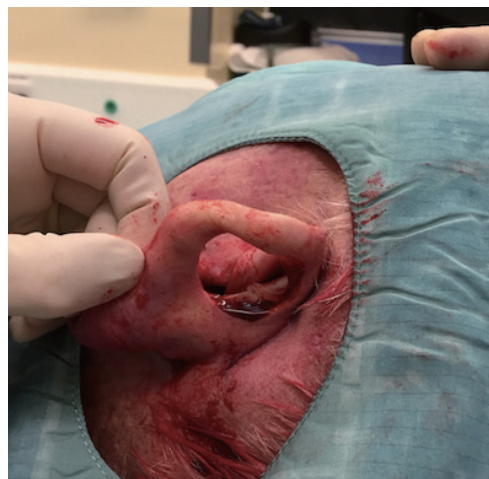


Fig. 2. The circular full-thickness uniform defect of the pinna.

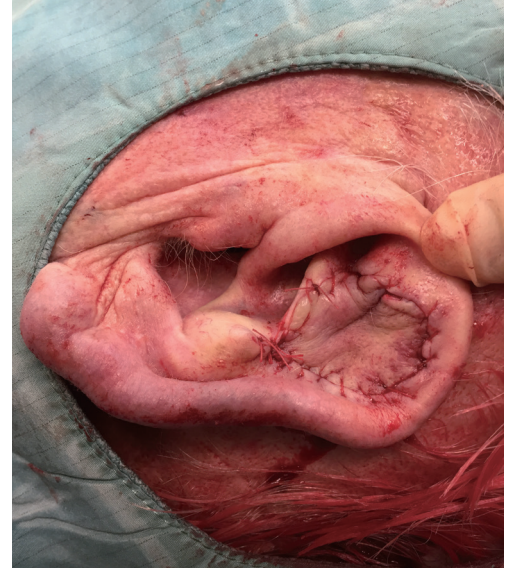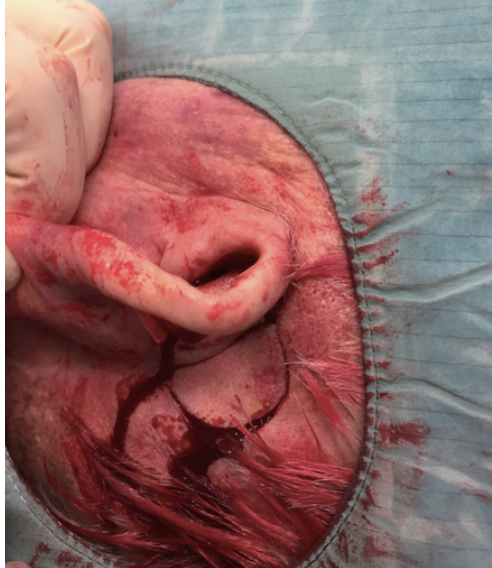


Fig. 3. The post auricular trap door flap raised and undermined leaving a small a central vascular pedicle.

Fig. 4. The trap door inset into the defect.

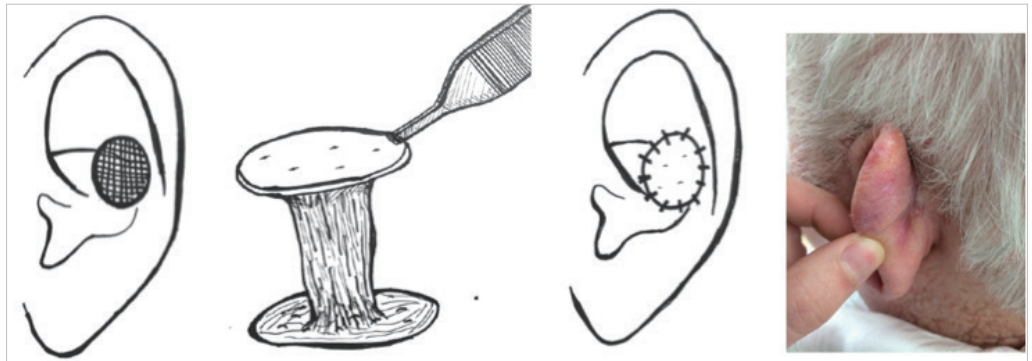


Fig. 5. The full thickness defect (shaded) is reconstructed with trapdoor flap based on a central pedicle. Photograph demonstrates the donor site three months postoperative.

then sutured into the lateral aspect of the defect. A running absorbable suture was used inset the remainder of the flap (Fig. 4). The anterior aspect of the donor site is not closed as it is inaccessible when the flap is inset. There is actually no need to close the anterior part as the edges become relatively opposed when the flap is inset to the defect. The posterior aspect of the donor site is closed with a running absorbable suture and it is the only visible portion of the donor site in the post auricular area. Because the posterior aspect of the full-thickness defect is not covered by the flap, this area is sutured to the donor site. This can lead to the ear being pulled in slightly to the side of the head. However, patients do not seem to mind this mild asymmetry. Dressings were simple and consisted of Steristrips (3M, Maplewood, MN, USA) and Micropore brown tape (3M [Maplewood] and Micropore). The wound was reviewed seven days

later at an outpatients clinic and the patient was also seen back at three months where the wound had settled down well (Fig. 5).

Skin malignancies of the outer ear are extremely common and reconstruction can often yield poor results [1]. The trap door flap is a quick one-stage procedure which protects the natural contour of the ear thereby producing an excellent aesthetic outcome. To our knowledge, this is the first time that this modified trap door flap has been described to reconstruct a posterior pinna defect. The trap door flap was designed to treat lesions on the anterior pinna and concha only. It was originally described by the senior author [2,3] and it has been used successfully on over 50 patients to date. Posterior pinna defects are usually reconstructed with transposition flaps or full thickness skin grafts. However, the underlying cartilage is frequently taken

when posterior pinna lesions are excised as the skin of the pinna is extremely thin. Reconstruction following cartilage excision can be difficult with contour deformities posing a potential problem. In this case, there was not enough redundant skin in the posterior auricular sulcus for a transposition flap.

Before now, the trap door flap has only been described for anterior pinna defects. It had to be modified slightly from the traditional trap door flap in order to reconstruct posterior pinna defects. The posterior auricular area blood supply has been well documented [4] and as a result flap loss is exceedingly rare [3].

McInerney et al. [3] reported on 45 patients with anterior pinna and conchal defects who had trap door reconstruction. They found the flap to be very reliable, producing a good cosmetic outcome. The flap provides a good colour match as it replicates the contour of the ear very well. We feel that the trap door flap should now be considered as a reconstructive option when excising skin malignancies on the posterior aspect of the pinna especially when there is a paucity of skin for a transposition flap. It is an extremely safe and effective flap with an excellent and predictable outcome.

References

1. Pless J. Carcinoma of the external ear. *Scand J Plast Reconstr Surg* 1976;10:147-51.
2. Lynch J, Mahajan AL, Regan P. The trap door flap for reconstructing defects of the concha. *Br J Plast Surg* 2003;56:709-11.
3. McInerney NM, Piggott RP, Regan PJ. The trap door flap: a reliable, reproducible method of anterior pinna reconstruction. *J Plast Reconstr Aesthet Surg* 2013;66:1360-4.
4. Hessam S, Georgas D, Bruns N, et al. A retroauricular flap for earlobe construction. *J Am Acad Dermatol* 2014;71:e129-30.

The Oblique Rectus Abdominis Musculocutaneous Flap for Reconstruction after Resection of a Spermatic Cord Liposarcoma

Jeremy Mingfa Sun¹, Jonah Ee-Hsiang Kua¹,
Lui Shiong Lee², Kah Woon Leo¹

Departments of ¹Plastic and ²Urology, Singapore General Hospital, Singapore, Singapore

Correspondence: Jeremy Mingfa Sun
Department of Plastic Reconstructive and Aesthetic Surgery, Singapore General Hospital, Outram Road, Singapore 169608, Singapore
Tel: +65-98768991, Fax: +65-98768991, E-mail: zatyricat@gmail.com

No potential conflict of interest relevant to this article was reported.

Received: 20 Apr 2015 • Revised: 2 Jul 2015 • Accepted: 14 Jul 2015
pISSN: 2234-6163 • eISSN: 2234-6171
<http://dx.doi.org/10.5999/aps.2015.42.5.647> • Arch Plast Surg 2015;42:647-650

Copyright © 2015 The Korean Society of Plastic and Reconstructive Surgeons
This is an Open Access article distributed under the terms of the Creative Commons Attribution Non-Commercial License (<http://creativecommons.org/licenses/by-nc/3.0/>) which permits unrestricted non-commercial use, distribution, and reproduction in any medium, provided the original work is properly cited.

A 62-year-old Chinese man presented with a painless swelling in the right inguinal region that had been increasing in size for over a year. After ultrasound imaging, a provisional diagnosis of a spermatic cord lipoma was made, and the inguinal mass was excised. The histological examination revealed a well

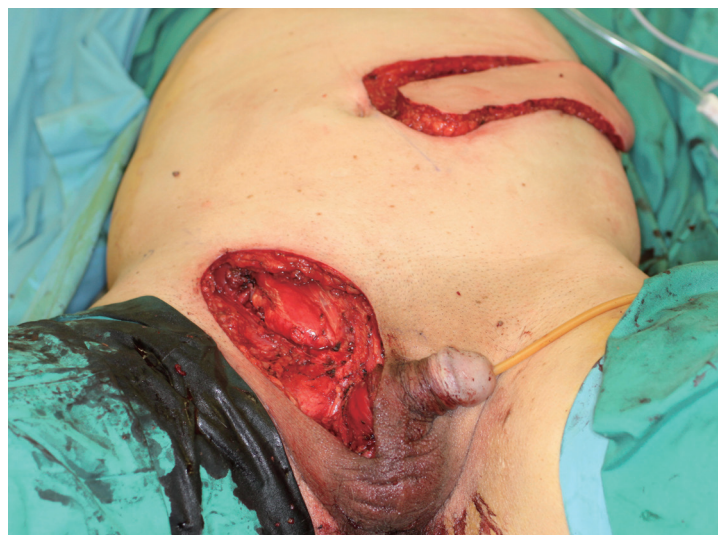

Fig. 1.

Surgical resection of the right inguinal region and the right hemiscrotum, together with right orchidectomy, resulted in a 15 × 7-cm skin defect and a 5 × 3-cm anterior abdominal wall defect involving the external oblique aponeurosis, internal oblique muscle, and conjoint tendon. The oblique rectus abdominis myocutaneous flap was raised based on the paraumbilical perforators of the rectus abdominis muscle.