



Clinical outcome of double crown-retained implant overdentures with zirconia primary crowns

Sven Rinke^{1,2*}, Ralf Buegers², Dirk Ziebolz³, Matthias Roediger²

¹Dental Practice, Hanau, Germany

²Department of Prosthetics, University Medical Center Göttingen, Göttingen, Germany

³Department of Cariology, Endodontology and Periodontology, University of Leipzig, Leipzig, Germany

PURPOSE. This retrospective study aims at the evaluation of implant-supported overdentures (IODs) supported by ceramo-galvanic double crowns (CGDCs: zirconia primary crowns + galvano-formed secondary crown).

MATERIALS AND METHODS. In a private practice, 14 patients were restored with 18 IODs (mandible: 11, maxilla: 7) retained by CGDCs on 4 - 8 implants and annually evaluated for technical and/or biological failures/complications. **RESULTS.** One of the 86 inserted implants failed during the healing period (cumulative survival rate (CSR) implants: 98.8%). During the prosthetic functional period (mean: 5.9 ± 2.2 years), 1 implant demonstrated an abutment fracture (CSR-abutments: 98.2%), and one case of peri-implantitis was detected. All IODs remained in function (CSR-denture: 100%). A total of 15 technical complications required interventions to maintain function (technical complication rate: 0.178 treatments/patients/year). **CONCLUSION.** Considering the small sample size, the use of CGDCs for the attachment of IODs is possible without an increased risk of technical complications. However, for a final evaluation, results from a larger cohort are required. [*J Adv Prosthodont 2015;7:329-37*]

KEY WORDS: Clinical trial; Telescopic crown; Overdenture; Zirconia; Survival; Success

INTRODUCTION

Double crowns have not only been used to retain implant-supported overdentures (IODs) in the mandible and the maxilla with positive long-term prognoses and high implant and denture survival rates, but they were also applied as attachments for residual natural teeth.¹⁻³

A number of modifications for the fabrication of implant-supported double-crowns have been described and used in clinical studies, including frictional parallel-sided

(telescopic) or conical crown designs mainly fabricated from cast noble alloys.⁴⁻⁸ Furthermore, telescopic crowns with a clearance fit fabricated from noble and non-precious alloys have been used as attachments for IODs⁹⁻¹² as well as prefabricated double-crown systems.¹³

The use of all-ceramic materials for the fabrication of double-crown attachments was first described in 2000.¹⁴ This so-called ceramo-galvanic double-crown (CGDC) is based on a conical crown design. It consists of a tapered all-ceramic primary crown and a secondary crown made from galvano-formed gold that are luted to a reinforcing cast denture framework (Fig. 1). It was assumed that replacing the cast metal by ceramics and electroplated gold would improve the wear resistance compared with conventional cast double crowns, thus leading to a more constant and predictable retentive force of the removable denture.¹⁴

The concept of the CGDC was clinically evaluated on a short-term basis with 32 patients wearing 33 dentures supported by natural teeth or implants. During this initial phase, the primary crowns were fabricated mainly from leucite-reinforced glass-ceramics (Empress 1, Ivoclar Vivadent, Schaan, Liechtenstein). This material exhibited increased

Corresponding author:
Sven Rinke
Geleitstr. 68, 63456 Hanau, Germany
Tel. 49 6181 189 0950; e-mail, rinke@ihr-laecheln.com
Received February 23, 2015 / Last Revision June 11, 2015 / Accepted July 17, 2015

© 2015 The Korean Academy of Prosthodontics
This is an Open Access article distributed under the terms of the Creative Commons Attribution Non-Commercial License (<http://creativecommons.org/licenses/by-nc/3.0>) which permits unrestricted non-commercial use, distribution, and reproduction in any medium, provided the original work is properly cited.

We thank Stephanie Zahn for her support of the clinical follow-up examinations.

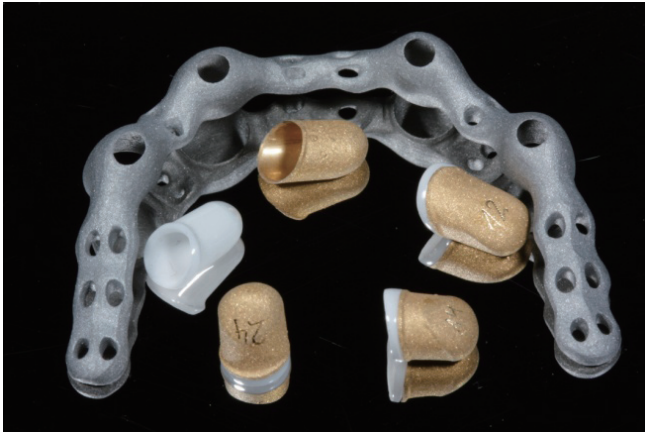

Fig. 1. Components of the CGDC restoration: milled and polished primary zirconia crowns, electroplated secondary crowns, and cast framework.

fracture rates and therefore was later replaced with yttria-stabilized zirconia polycrystals (Y-TZP or zirconia).¹⁵ Subsequently, conical crowns with zirconia primary crowns and electroplated copings as female parts have been evaluated in several *in vitro* studies.¹⁶⁻¹⁸ The CGDCs demonstrated clinically acceptable mean retentive forces and reduced excursive retentive force development compared with cast double crown systems.^{17,18} The retentive force was influenced by the abutment height and the taper. It was concluded that zirconia primary crowns with a sufficient height and 2° taper can serve as an alternative to gold alloy primary crowns.¹⁶

Y-TZP has been clinically evaluated as a framework material for crowns and fixed partial dentures (FPDs) in numerous clinical trials with promising results.^{19,20} Nevertheless, to the best of our knowledge, the treatment concept of CGDCs for the attachment of IODs has only been described in several case reports.²¹⁻²⁴ Long-term clinical evaluations are needed.

The present retrospective clinical study evaluates patients with solely implant-supported overdentures in the maxilla and the mandible. The patients were restored with double-crown-retained IODs with zirconia primary crowns and electro-formed secondary crowns (CGDCs) in a private dental practice. This investigation sought to determine the survival rates of implants/abutments/primary crowns and dentures as well as biological and technical complication rates over a mean observational time of >5 years.²⁵⁻²⁷

MATERIALS AND METHODS

This retrospective clinical evaluation was conducted in a private practice (Hanau, Germany). The study is based on the analysis of primary patient data as well as the evaluation of clinical results from IODs that were rigidly retained by double crowns with zirconia primary crowns and electro-

plated secondary crowns. The study was reviewed by the Ethics Committee of the Georg-August-University, Göttingen, Germany, and authorized by this board (application no. 4/7/13). Recommendations to strengthen the reporting of observational studies in epidemiology (STROBE) were followed.²⁸

Patients provided with double crown-retained IODs between July 2003, and July 2010 and who attended a maintenance program including supportive post-implant hygiene therapy (SIT) were identified. These patients were contacted during their respective annual maintenance appointments and were suggested to participate in the clinical study after having been briefed in writing about its aims and course. Patients who submitted written informed consent were included if they met the following inclusion criteria:

- surgical and prosthetic treatment was received in the study practice
- the same implant design (Ankylos, Dentsply Implants GmbH, Mannheim, Germany), and an identical prosthetic concept (ceramo-galvanic-double crowns according to P. Weigl) were used
- inclusion of a minimum of 4 and maximum of 8 implants per restoration
- regular supportive post-implant hygiene therapy (SIT) (at least annually)
- a functional period of >3 years with the final restorations in place
- full medical history available, which includes the identification of these potential risk factors: medication (immune suppression and bisphosphonate), cardiovascular disease, rheumatoid arthritis, diabetes, smoking habits

These exclusion criteria were applied:

- patients who did not completely fulfill the inclusion criteria
- non-compliance in supportive post-implant hygiene therapy (SIT) (minimum 1/year)
- other missing data
- use of other implant systems than the Ankylos system
- application of other attachments than ceramo-galvanic double crowns (CGDC)

Restorative planning aimed at a quadrangular support with a minimum of 4 and a maximum of 8 implants per IOD. Surgery was performed under local anesthesia according to the manufacturer's protocol. The same experienced clinician (SR) performed all clinical procedures. Antibiotics were administered 1 hour before and 1 week after surgery (amoxicillin 1000 3×1/d or clindamycin 300 3×1/d). Wound control occurred 7 days (suture removal) and 21-28 days after surgery. Implant uncovering was performed after 3 to 6 months. Prosthodontic treatment was performed according to the technique proposed by P. Weigl and encompasses the following steps:

1. Impressions were obtained on the implant level using screw-retained impression copings, a custom impres-

sion tray, and a polyether material (Impregum Soft, 3M Espe GmbH, Seefeld, Germany). During the same appointment, a preliminary bite registration was taken.

- Zirconia primary crowns were fabricated on titanium abutments (Ankylos Balance Posterior, Dentsply Implants GmbH, Mannheim, Germany) with various heights and angulations using a CAM system (Cercon smart ceramics, DeguDent GmbH, Hanau, Germany). The crowns were milled with a 2° taper, and the minimum thickness was 0.5 mm. Secondary electroplated copings were fabricated directly on the finished zirconia primary crowns. The ceramic surface was sprayed with a thin conductive silver layer, and the copings were placed in an electroplating device (Solaris, DeguDent GmbH, Hanau, Germany). Processing time as well as the current for electroplating was adjusted in order to guarantee a minimum thickness of 0.2 mm for the gold coping. A reinforcing denture framework was cast in one piece from a CoCr alloy, including complete coverage of the secondary crowns. Between the denture framework and the secondary coping, a luting space of 0.15 to 0.2 mm was generated (Fig. 1).

- After definitive placement of the titanium abutments (torque: 15 Ncm), the primary crowns were luted adhesively onto the abutments using an auto-curing composite cement (AGC Cem, Wieland Dental+ Technik GmbH, Pforzheim, Germany) (Fig. 2A). Afterwards, the secondary gold copings were placed on the ceramic primary crowns. The denture framework was then luted with the secondary crown intraorally using the same auto-curing composite (Fig. 2B).
- The passively fitting framework was then used as a basis for a definitive bite registration.
- A total impression encompassing the joint secondary crowns and the denture framework was obtained using a custom tray and a polyvinylsiloxane material (Aquasil Monophase, Dentsply DeTrey GmbH, Konstanz, Germany). A provisional denture that was fixed on the definitively placed primary crowns was inserted. The denture was completed on the new model. The framework was completely covered with denture base resin, and resin-based denture teeth were added (Fig. 2C).
- Insertion of the completed denture with occlusal adjustments (Fig. 2D).

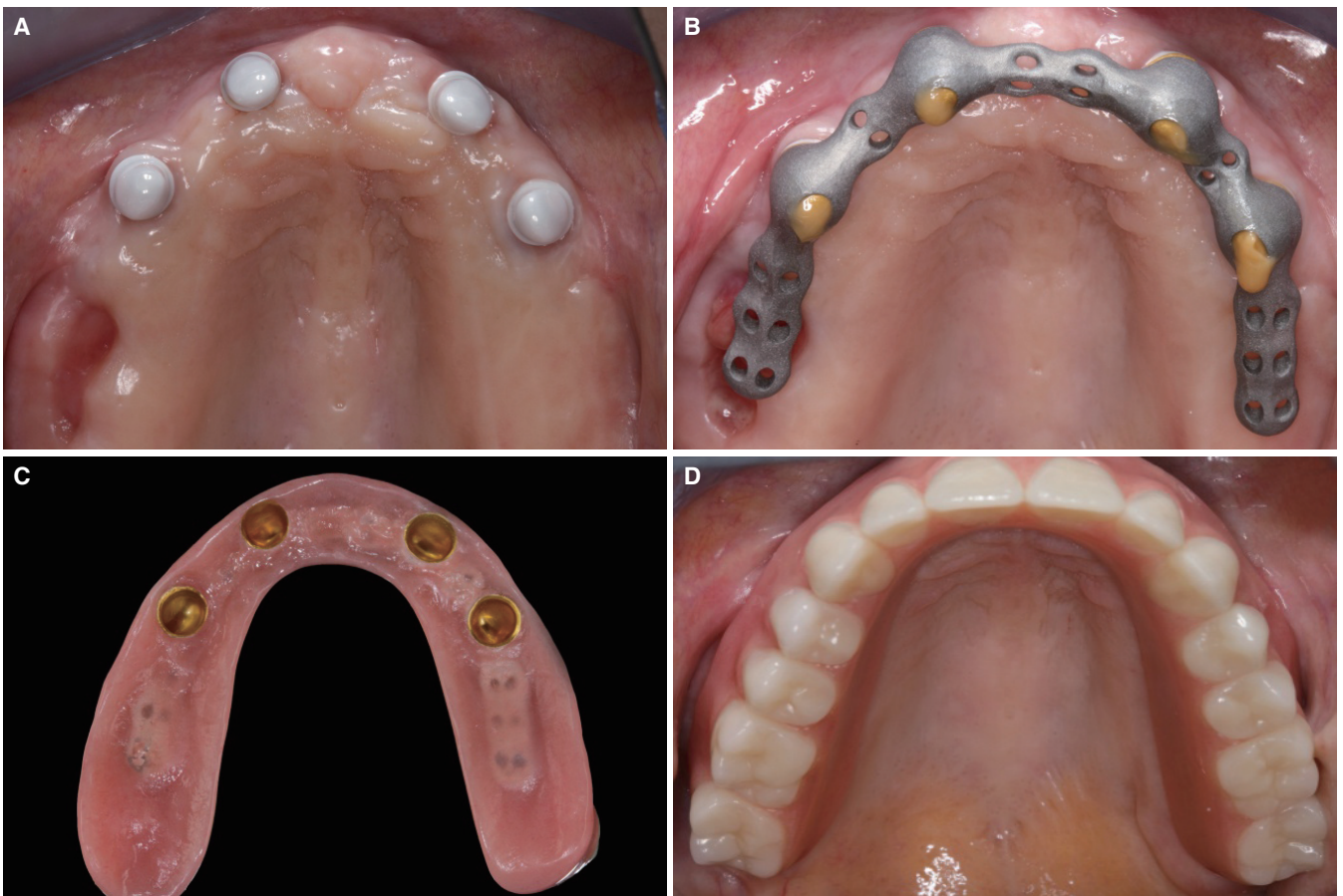


Fig. 2. (A) Adhesively luted zirconia primary crowns for a maxillary IOD retained by 4 implants, (B) Intraoral luting of the secondary crowns and the CoCr framework, (C) Basal view on the finalized removable denture, (D) Clinical situation with the CGDC-retained maxillary IOD on 4 implants.

After the delivery of the IODs, all patients received oral hygiene instructions. The patients were then scheduled for a supportive post-implant hygiene therapy visit (SIT). In at least one prophylaxis appointment per year, the patient compliance was assessed. During these sections, the following data were evaluated: The periodontal and peri-implant tissue status using the Quigley-Hein plaque index (QHI); measurement of peri-implant probing depths (PPDs) with a millimeter-scaled periodontal probe (PCP 15, Hu-Friedy Manufacturing Company, LLC, Chicago, IL, USA) at 4 sites per implant (mesio-buccal, disto-buccal, mesio-oral, and disto-oral), any bleeding on probing was documented (BOP; 30 seconds following probing); and radiographs for implants with positive BOP and a PPD ≥ 5 mm using the long-cone parallel technique). Patient motivation was reinforced during the follow-up sessions, and all subjects were repeatedly instructed on in-home plaque control. All implants as well as the teeth involved were then professionally cleaned with polishing paste and a rubber cup. If peri-implant mucositis was diagnosed, a special ultrasonic tip was used for scaling around the implants (KaVo SONICflex implant, KaVo Dental GmbH, Biberach, Germany). These areas were then instrumented manually prior to the subgingival application of chlorhexidine gel (Corsodyl 1% Dental Gel, GlaxoSmithKline GmbH, Hamburg, Germany).^{29,30}

The patients included in this retrospective clinical study were evaluated according to the following parameters by using patient records: age at the concluding examination, gender, smoking habits, medical history, anatomical implant position (FDI system), number of implants, implant loss until data acquisition, time of denture insertion, opposing dentition, and functional period. An experienced dentist who did not place the implants performed the clinical examination of the patients during the last SIT appointment. He evaluated these technical and biological complications of teeth/implants as well as the removable dentures: material fractures, screw loosening, retention loss and/or defects of the retention elements, relines, peri-implantitis. For all implants a periodontal examination, including PPD and BOP, was performed. Radiographs that measured the extent of peri-implant bone loss referenced to baseline radiographs (prosthetic delivery) were taken in order to confirm the diagnosis of peri-implantitis for implants with positive BOP and a PPD ≥ 5 mm. Intraoral radiographs were obtained using a parallel technique, they served to assess the peri-implant bone level and were evaluated by an experienced dentist (DZ).^{11,12} The clinical procedures for the SIT and the methods for data collection have been applied in previous studies by the same working group^{11,12,29,30}

The maintenance of either an implant or a prosthetic reconstruction in the mouth was defined as survival, independent of biological and/or technical complications.²⁷ The period between the time of placement and the last follow-up appointment or, for failures, the appointment scheduled to address the failure as documented in the patient's file, were defined as survival time.^{26,27} The criteria proposed by Albrektsson *et al.*²⁵ were the basis for the calculation of

cumulative implant success rates.

All technical complications that were related to either the overdenture or the implant abutment (e.g. abutment fracture, loosening of the abutment screw, fracture of the denture material (base/teeth), retention loss, attachment defects) were documented. Treatments occurring per restoration per year (T/R/Y) and treatments occurring per patient per year (T/P/Y)^{6,11,12,29} formed the basis for the calculation of incidence rates for technical complications

Peri-implant mucositis was recorded for implants with PPD >4 mm, and BOP. The following final points were used as diagnostic criteria for peri-implantitis: PPD ≥ 5 mm, positive BOP/suppuration, radiographic bone loss with a distance of at least 3.5 mm between implant shoulder and bone level.^{11,12,30} As the sample size is small, no significant statistical analysis of the potential factors that influence the treatment results was possible. For this reason, only descriptive statistics were applied.

RESULTS

In total, 17 patients were declared to meet the inclusion criteria. 14 of this lot (63.1 ± 6.8 years/range: 52.1-75.7) received a final clinical follow-up examination between September 2013 and June 2014. They qualified for inclusion in the present study. All patients attended one to four SIT appointments per year. The dropout rate was 17.6% (1 patient declined further participation due to severe illness, and 2 patients died). Of the included patients, 7 were female (50%), and 7 were male. Two patients were active smokers (14.3%). The medical histories revealed that 2 patients (14.3%) suffered from diabetes type 2, 5 (35.7%) patients were afflicted with a cardiovascular disease. The mean implant follow-up period was determined at 6.2 ± 2.3 years (minimum 3.5 years, maximum 10.5 years). The 14 patients included in the study received a total of 18 CGDC-retained prostheses (4 patients received restorations in both, the maxilla and mandible). Eleven CGDC-retained prosthesis were placed in the mandible, and 7 were placed in the maxilla. The mean prosthetic follow-up period was 5.9 ± 2.2 years (range: 3.2-9.9 years). Table 1 summarizes the pertinent patient data.

A total of 86 implants with a morse taper connection (Ankylos, Dentsply Implants, Mannheim, Germany) was inserted: 38 implants (44.2%) were placed in the maxilla, whereas 48 implants (55.8%) were inserted in the mandible (Table 2). The mean length was 12.2 ± 1.7 mm (range: 9.5-14 mm). Due to the absence of osseointegration, one implant (upper molar region) had to be removed at the time of second-stage surgery. None of the remaining implants failed after functional loading (cumulative implant survival rate: 98.8% after 6.2 ± 2.3 years).

A total of 85 implants were provided with CGDC according to the protocol proposed by P. Weigl. The number of implants included in one restoration ranged between 4 and 8 (mean: 4.7 ± 1.1). Peri-implant mucositis (positive BOP and PPD >4 mm) was observed in 40 implants

Table 1. Pertinent patient data (n=14)

Mean age (\pm SD)		63.1 \pm 6.8 (range: 52.1 - 75.7) years
Gender	Female	7 (50%)
	Male	7 (50%)
Smoking status	Non-smokers	12 (85.7%)
	Smokers	2 (14.3%)
Systemic conditions	Diabetes mellitus (type 2)	2 (14.3%)
	Coronary heart disease	5 (35.7%)
Mean implant follow-up		6.2 \pm 2.3 (range: 3.5 - 10.4) years
Mean denture follow-up		5.9 \pm 2.2 (range: 3.2 - 9.9) years
Mean implant length		12.2 \pm 1.7 (range: 9.5 - 14) mm
Mean implant number per denture		mean number of implants: 4.7 \pm 1.1 (range: 4 - 8)
Opposing dentition (n=14)	Total denture	3 (21.4%)
	RPD	2 (14.3%)
	Fixed	3 (21.4%)
	IOD-bar	2 (14.3%)
	IOD CGDC	4 (28.6%)

Table 2. Implant distribution (n=86) (FDI system)

Implants (n)	0	0	3	1	6	1	7	1	1	7	1	6	1	3	0	0	38
Implant position (FDI)	18	17	16	15	14	13	12	11	21	22	23	24	25	26	27	28	Total maxilla
Implant position (FDI)	48	47	46	45	44	43	42	41	31	32	33	34	35	36	37	38	Total mandible
Implants (n)	0	0	2	0	10	1	11	0	0	11	1	10	0	2	0	0	48

(47.1%) and 10 patients (71.4%). The mean radiographic bone loss was 0.7 ± 0.6 mm (range 0-3.6 mm). One of the 85 functionally loaded implants exhibited clinical symptoms of peri-implantitis according to the selected criteria (radiographic bone loss of ≥ 3.5 mm, a PPD ≥ 5 mm, and positive BOP). This resulted in an implant-based peri-implantitis rate of 1.2% (patient-based peri-implantitis: 7.1%). This implant was rated as a radiographic failure. According to the criteria defined by Albrektsson *et al.*,²⁵ this led to a cumulative implant success rate of 97.7% (Table 3).

One out of the 85 titanium abutments fractured after a functional period of 5.43 years and required replacement. The new abutment was integrated into the existing removable denture. The cumulative abutment survival rate was 98.2% after a mean observational time of 5.9 ± 2.2 years (range: 3.2-9.9 years). No loosening of any of the abutment screws was detected. None of the zirconia primary crowns fractured, this led to a cumulative primary crown survival rate of 100%.

Each of the 14 included patients received one or two removable telescopic dentures supported by 4-8 implants and attached by CGDCs. The opposing dentition of 3 patients (21.4%) was restored with a fixed reconstruction; 3 patients (21.4%) wore full dentures, and 2 patients (14.3%)

Table 3. Implant outcomes (n=86)

Implant survival rate	98.8%
Abutment survival rate	98.2%
Implant success rate*	97.7%
Peri-implant mucositis	
implant-based	40 (47.1%)
patient-based	10 (71.4%)
Peri-implantitis	
implant-based	1 (1.2%)
patient-based	1 (7.1%)

*according to Albrektsson *et al.* (1986)

wore tooth-supported, removable dentures. The opposing jaws of 2 patients (14.3%) were restored with IODs supported by milled bars, and 4 patients (28.6%) received IODs supported by CGDCs in both jaws (Table 1). All dentures were found functional at the time of investigation. After a mean observational period of 5.9 ± 2.2 years (range: 3.2-9.9 years), the cumulative survival rate for IODs was 100%.

Table 4. Required prosthetic maintenance of IODs (n=18) retained by ceramo-galvanic double crowns (CGDCs) based on a mean follow-up of 5.9 years

	Total	Relining	DTR ¹	DBMF ²	RC ³	Secondary crown (discoloration)
No of treatments (n)	15	3	6	1	3	2
Share of treatments (%)	100	20	40	6.7	20	13.3
Treatments/P/Y ⁴	0.179	0.036	0.071	0.012	0.036	0.024

¹DTR: Denture teeth replacement; ²DBMF: Denture base material fracture; ³RC: recementation (primary telescope); ⁴per patient per year.

A total of 15 technical complications were registered for 8 out of the 18 restorations (44.4%) in 8 different patients. Five of these complications were related to the CGDC (33.3%) and 10 (66.6%) to the removable dentures. Loss of retention required recementation of 3 not damaged zirconia primary crowns. Two galvano-formed secondary crowns exhibited discolorations and had to be repolished. Eight out of the 18 removable dentures were affected by 10 technical complications. Tooth fractures were the most frequent complication (n=6) and required the replacement of 1 to 3 denture teeth. One removable denture exhibited 3 different denture teeth fractures during the entire observational period of 5.1 years. Three other removable dentures were affected by single denture teeth fracture events. Three other removable dentures required realignment, and one denture required a repair of the fractured part of the denture base material. Apart from the above mentioned loss of retention, for all removable restorations, a sufficient retention force was maintained over the entire observational period, and clinical interventions to improve the retention characteristics were not necessary in any of these cases.

In total, incidence rates of 0.139 treatments per denture per year (T/D/Y) and 0.179 treatments per patient per year (T/P/Y) were recorded. Table 4 provides information on both, the technical complications as well as the required prosthetic maintenance.

DISCUSSION

This practice-based retrospective study presents clinical data for the survival/success of CGDC-supported IODs in 14 patients restored with a total of 85 implants after a mean observational period of 5.9 years. The CSR of the implants was documented with 98.5%, 100% of the prosthetic reconstructions remained in function during this time. The observed rates for technical and biological complications were low, the findings did not endanger the continued functioning of the IODs in any way.

For the evaluation of the present study, it had to be considered that it is based on a small patient lot only. A control group with other types of attachments (e.g., conventional double crowns or ball attachments) that matched the study group was not available. However, notwithstand-

ing these limitations, the study population exclusively consisted of patients with implants and prosthetic restorations with an identical design. Only implants with a Morse taper connection (Ankylos, Dentsply Implants GmbH, Mannheim, Germany) and double crowns manufactured according to the CGDC technique were included. The clinical data were generated under the typical conditions of a private practice. This is an important aspect of the present study because most of the existing clinical data with double crown-retained IODs were collected in university settings, covering mean observational times of less than 5 years.²⁻⁹

The results of the present study revealed a cumulative survival rate of 98.8% for the implants (cumulative success rate according to Albrektsson *et al.*²⁵: 97.7%) after a mean observational time of 6.2 ± 2.3 years. After a mean observational period of 5.9 ± 2.2 years, the cumulative survival rate for removable dentures was 100%. This finding meets the survival rates documented for double crown-retained implant-borne overdentures. The published data on implant-supported double crown-retained overdentures in edentulous jaws revealed survival rates of 97% - 100% for implants, and 93% - 100% for overdentures for mean observational periods of up to five years.^{2,3,6-8}

A specific aspect of the present retrospective clinical evaluation is the use of the ceramo-galvanic double crown. During the entire observational period, none of the zirconia primary crowns fractured. To date, zirconia has been evaluated exclusively as a framework material for crowns and fixed partial dentures. It has demonstrated a high reliability and low fracture rate for functional periods of up to 10 years for these indications.^{19,20} Due to the fact that the IODs are rigidly retained by the CGDCs, high mechanical loads are generated by the distal extensions. Based on the findings of the present study, no increased fracture rate of the unveneered zirconia was detected if used as primary crowns to rigidly attached IODs. This presents a new finding not yet reported by clinical investigations.

During evaluation of the approaches and concepts used for restorative treatment, the rate of required prosthetic maintenance was seriously accounted for.¹⁻³ In the literature, few studies detail the technical complications linked to implant-supported removable dentures using various types of attachments (bars, ball attachments, and double crowns). The requirements for maintenance varied between 0.222

and 4.03 treatments per patient per year (T/P/Y).^{1,6,7,11,12} Preferably, the results of the present study should be compared with studies that also report technical complication rates for IODs retained by double-crowns. A prospective study that assessed 4 interforaminal implants in the mandible over 3 years of follow-up, the need for prosthetic maintenance was documented at 0.41 T/P/Y with bar structures compared to 0.45 T/P/Y for telescopic restorations.⁶ In a practice-based retrospective evaluation of double crown-retained overdentures after a minimum observational time of 10 years, a technical complication of 0.333 treatments/patient/years was reported.¹¹ Another retrospective study that evaluated the technical complication rate of maxillary IODs also using Ankylos implants and double crown attachments documented that all dentures remained in function (prosthetic survival rate:100%) after a mean observational time of >5 years.¹² Technical maintenance procedures were required at a rate of 0.222 T/P/Y. This result meets the findings of the present study with a technical complication rate of 0.178 T/P/Y. These findings reveal that CGDC-retained IODs require a comparatively low maintenance, all the more when considering that about 66% of the appointments were purely prosthesis-related (e.g. fractures of prosthetic teeth, relinings). Similar to other studies with solely implant-supported overdentures, technical complications applying to the removable restoration parts (fractures of resin components) were the most frequent type of technical complication.^{1,6-8,11,12}

It is a limitation in the prosthetic design evaluated in the present study that the primary crowns were cemented adhesively to the abutments. In case of an abutment screw loosening, thus the preparation of an access cavity is needed to retighten the abutment screw.

In several *in vitro* investigations, the retentive forces of CGDCs have been evaluated.¹⁶⁻¹⁸ From these investigations, it was concluded that CGDCs have sufficient retentive properties and are not susceptible to excessive wear. These results are supported by the findings of the present case series. None of the 18 re-examined dentures displayed insufficient retention, and no interventions to improve retention were necessary during the entire observational period. The good retentive characteristics in the present study are potentially explained by two design aspects of the restorations: 1. All dentures were supported by at least 4 CGDCs, and 2. It was possible for all 85 CGDCs to maintain a minimum height of at least 5 mm. The latter appears to be important, as *in vitro* investigations have demonstrated that the height of the primary crown significantly affects the retention force generated by CGDCs.¹⁶

Under these preconditions, no increased risk for technical complications of CGDCs compared with metal-based double crowns was detected for a mid-term clinical evaluation with a mean observational time of >5 years.

In addition to technical complications, the clinical performance of implant-supported restorations can be challenged by biological complications, e.g. peri-implantitis. Based on the published results, within 5-10 years after

implant insertion, peri-implantitis occurs in 10% of implants and 20% of patients. Nevertheless, the individually reported data showed a significant variation²⁶ which is due to differences in the study populations, observational times, level of maintenance measures, and the application of different criteria for the definition of peri-implant mucositis and peri-implantitis.²⁷ Apart from smoking habits and history of peri-implantitis, inadequate oral hygiene is one of the risk factors linked to peri-implantitis.³⁰⁻³² However, information on biological complications, especially with IODs, remains sparse.^{2,3} In the present study, 47.1% of the implants in 10 out of 14 patients (71.4%) exhibited clinical symptoms of peri-implant mucositis (BOP + PPD >4 mm). Considering the selected criteria (crestal bone loss \geq 3.5 mm, PPD \geq 5 mm, positive BOP), one of the implants demonstrated symptoms of peri-implantitis (implant-based prevalence: 1.2%, patient-based prevalence: 7.1%).

These findings should preferably be matched with results evaluated with a comparable implant design and prosthetic treatment concept. In another practice-based study of 20 patients restored with overdentures supported by four implants (using the same implant design as in the present case series) and double-crown attachments, an implant- and patient-based peri-implantitis rate of 10% was detected after a mean observational time of 5.6 years.¹² The same group also reported results for double crown-retained IODs placed in non-smoking patients after a mean observational period of 14.1 years. This study documents a patient-based peri-implantitis rate of 9%.¹¹ The results of the present study match these findings. Based on these findings for double crown-retained IODs, peri-implantitis occurs in 7 to 10% of patients for mean observational periods of 5-14 years, which is somewhat lower than the expected rate of 20% for observational periods of 5-10 years. This finding might be explained by the following factors. In all three studies, the patients periodically attended post-implant hygiene programs. This is of great importance as the positive effect of supportive post-implant hygiene therapy on minimizing the risk for peri-implantitis has been demonstrated in various clinical studies.³⁰⁻³² The design of the prosthesis itself might be another factor that could help to reduce the risk for peri-implantitis. Double crown-retained IODs offer good cleaning access in oral hygiene homecare procedures, thus reducing the risk for hyperplasia and peri-implantitis. This hypothesis was supported by the findings of clinical trials comparing IODs that are bar- or telescopic crown-retained^{4,6}; the two studies determined significantly more hyperplasia and plaque accumulation and hyperplasia for bar attachments. Another possible reason for the fairly low peri-implantitis rates can be observed in the patient selection in the three cited studies. All three studies included either only non-smokers or a small number of smokers (< 15%). Smoking was identified as a significant risk factor for peri-implantitis, and therefore, the small number of smokers in the cited studies could possibly influence the reported patient-based peri-implantitis rates.³⁰

CONCLUSION

Considering the limitations of this retrospective clinical evaluation, the following conclusions can be drawn:

The successful function and high survival rates of CGDC-retained IODs can be expected even over a prolonged period of >5 years. Technical complications mainly related to the removable parts should be anticipated during the functional period without further affecting the function of the IODs. For patients restored with CGDC-retained IODs who regularly attend a supportive post-implant hygiene therapy, biological complications (peri-implantitis) remain a rare event during the first 5 years of clinical service.

Additional studies covering a larger sample and higher evidence levels (RCTs) are necessary to validate the results of this study and to compare this treatment concept with alternative treatment concepts.

ORCID

Sven Rinke <http://orcid.org/0000-0003-3804-6410>

Ralf Buegers <http://orcid.org/0000-0002-6320-4348>

Dirk Ziebolz <http://orcid.org/0000-0002-9810-2368>

Matthias Roediger <http://orcid.org/0000-0002-8615-5147>

REFERENCES

- Andreiotelli M, Att W, Strub JR. Prosthodontic complications with implant overdentures: a systematic literature review. *Int J Prosthodont* 2010;23:195-203.
- Koller B, Att W, Strub JR. Survival rates of teeth, implants, and double crown-retained removable dental prostheses: a systematic literature review. *Int J Prosthodont* 2011;24:109-17.
- Verma R, Joda T, Brägger U, Wittneben JG. A systematic review of the clinical performance of tooth-retained and implant-retained double crown prostheses with a follow-up of ≥ 3 years. *J Prosthodont* 2013;22:2-12.
- Eitner S, Schlegel A, Emeka N, Holst S, Will J, Hamel J. Comparing bar and double-crown attachments in implant-retained prosthetic reconstruction: a follow-up investigation. *Clin Oral Implants Res* 2008;19:530-7.
- Weinländer M, Piehslinger E, Krennmair G. Removable implant-prosthodontic rehabilitation of the edentulous mandible: five-year results of different prosthetic anchorage concepts. *Int J Oral Maxillofac Implants* 2010;25:589-97.
- Krennmair G, Sütö D, Seemann R, Piehslinger E. Removable four implant-supported mandibular overdentures rigidly retained with telescopic crowns or milled bars: a 3-year prospective study. *Clin Oral Implants Res* 2012;23:481-8.
- Bernhart G, Koob A, Schmitter M, Gabbert O, Stober T, Rammelsberg P. Clinical success of implant-supported and tooth-implant-supported double crown-retained dentures. *Clin Oral Investig* 2012;16:1031-7.
- Schwarz S, Bernhart G, Hassel AJ, Rammelsberg P. Survival of double-crown-retained dentures either tooth-implant or solely implant-supported: an 8-year retrospective study. *Clin Implant Dent Relat Res* 2014;16:618-25.
- Heckmann SM, Schrott A, Graef F, Wichmann MG, Weber HP. Mandibular two-implant telescopic overdentures. *Clin Oral Implants Res* 2004;15:560-9.
- Krennmair G, Seemann R, Weinländer M, Piehslinger E. Comparison of ball and telescopic crown attachments in implant-retained mandibular overdentures: a 5-year prospective study. *Int J Oral Maxillofac Implants* 2011;26:598-606.
- Frisch E, Ziebolz D, Rinke S. Long-term results of implant-supported over-dentures retained by double crowns: a practice-based retrospective study after minimally 10 years follow-up. *Clin Oral Implants Res* 2013;24:1281-7.
- Frisch E, Ziebolz D, Ratka-Krüger P, Rinke S. Double crown-retained maxillary overdentures: 5-year follow-up. *Clin Implant Dent Relat Res* 2015;17:22-31.
- Romanos GE, May S, May D. Immediate loading of tooth-implant-supported telescopic mandibular prostheses. *Int J Oral Maxillofac Implants* 2012;27:1534-40.
- Weigl P, Hahn L, Lauer HC. Advanced biomaterials used for a new telescopic retainer for removable dentures. *J Biomed Mater Res* 2000;53:320-36.
- Weigl P, Lauer HC. Advanced biomaterials used for a new telescopic retainer for removable dentures. *J Biomed Mater Res* 2000;53:337-47.
- Beuer F, Edelhoff D, Gernet W, Naumann M. Parameters affecting retentive force of electroformed double-crown systems. *Clin Oral Investig* 2010;14:129-35.
- Bayer S, Kraus D, Keilig L, Gözl L, Stark H, Enkling N. Changes in retention force with electroplated copings on conical crowns: a comparison of gold and zirconia primary crowns. *Int J Oral Maxillofac Implants* 2012;27:577-85.
- Engels J, Schubert O, Güth JF, Hoffmann M, Jauernig C, Erdelt K, Stimmelmayer M, Beuer F. Wear behavior of different double-crown systems. *Clin Oral Investig* 2013;17:503-10.
- Raigrodski AJ, Hillstead MB, Meng GK, Chung KH. Survival and complications of zirconia-based fixed dental prostheses: a systematic review. *J Prosthet Dent* 2012;107:170-7.
- Larsson C, Wennerberg A. The clinical success of zirconia-based crowns: a systematic review. *Int J Prosthodont* 2014; 27:33-43.
- Kurbad A, Reichel K. All-ceramic primary telescopic crowns with Cerec inLab. *Int J Comput Dent* 2003;6:103-11.
- Uludag B, Sahin V, Ozturk O. Fabrication of zirconium primary copings to provide retention for a mandibular telescopic overdenture: a clinical report. *Int J Prosthodont* 2008;21: 509-10.
- Zafiroopoulos GG, Rebbe J, Thielen U, Deli G, Beaumont C, Hoffmann O. Zirconia removable telescopic dentures retained on teeth or implants for maxilla rehabilitation. Three-year observation of three cases. *J Oral Implantol* 2010;36: 455-65.
- Kurbad A, Ganz S, Kurbad S. CAD/CAM generated all-ceramic primary telescopic prostheses. *Int J Comput Dent* 2012;15:237-49.
- Albrektsson T, Zarb G, Worthington P, Eriksson AR. The long-term efficacy of currently used dental implants: a review and proposed criteria of success. *Int J Oral Maxillofac*

- Implants 1986;1:11-25.
26. Albrektsson T, Donos N; Working Group 1. Implant survival and complications. The Third EAO consensus conference 2012. *Clin Oral Implants Res* 2012;23:63-5.
 27. Pjetursson BE, Zwahlen M, Lang NP. Quality of reporting of clinical studies to assess and compare performance of implant-supported restorations. *J Clin Periodontol* 2012;39:139-59.
 28. von Elm E, Altman DG, Egger M, Pocock SJ, Gøtzsche PC, Vandenbroucke JP; STROBE Initiative. The Strengthening the Reporting of Observational Studies in Epidemiology (STROBE) statement: guidelines for reporting observational studies. *J Clin Epidemiol* 2008;61:344-9.
 29. Rinke S, Ziebolz D, Ratka-Krüger P, Frisch E. Clinical Outcome of Double Crown-Retained Mandibular Removable Dentures Supported by a Combination of Residual Teeth and Strategic Implants. *J Prosthodont* 2014 Sep 14.
 30. Rinke S, Ohl S, Ziebolz D, Lange K, Eickholz P. Prevalence of periimplant disease in partially edentulous patients: a practice-based cross-sectional study. *Clin Oral Implants Res* 2011; 22:826-33.
 31. Costa FO, Takenaka-Martinez S, Cota LO, Ferreira SD, Silva GL, Costa JE. Peri-implant disease in subjects with and without preventive maintenance: a 5-year follow-up. *J Clin Periodontol* 2012;39:173-81.
 32. Pjetursson BE, Helbling C, Weber HP, Matuliene G, Salvi GE, Brägger U, Schmidlin K, Zwahlen M, Lang NP. Peri-implantitis susceptibility as it relates to periodontal therapy and supportive care. *Clin Oral Implants Res* 2012;23:888-94.