

The current approach to the diagnosis of vascular anomalies of the head and neck: A pictorial essay

Sinny Goel^{1,*}, Swati Gupta², Aarti Singh¹, Anjali Prakash², Sujoy Ghosh¹, Poonam Narang³, Sunita Gupta¹

¹Department of Oral Medicine and Radiology, Maulana Azad Institute of Dental Sciences, Delhi, India

²Department of Radiodiagnosis, Lok Nayak Jaiprakash Hospital, Delhi, India

³Department of Radiodiagnosis, Govind Ballabh Pant Hospital, Delhi, India

ABSTRACT

Throughout the years, various classifications have evolved for the diagnosis of vascular anomalies. However, it remains difficult to classify a number of such lesions. Because all hemangiomas were previously considered to involute, if a lesion with imaging and clinical characteristics of hemangioma does not involute, then there is no subclass in which to classify such a lesion, as reported in one of our cases. The recent classification proposed by the International Society for the Study of Vascular Anomalies (ISSVA, 2014) has solved this problem by including non-involuting and partially involuting hemangioma in the classification. We present here five cases of vascular anomalies and discuss their diagnosis in accordance with the ISSVA (2014) classification. A non-involuting lesion should not always be diagnosed as a vascular malformation. A non-involuting lesion can be either a hemangioma or a vascular malformation depending upon its clinicopathologic and imaging characteristics. (*Imaging Sci Dent 2015; 45: 123-31*)

KEY WORDS: Hemangioma; Vascular Malformation; Classification; Neck

Vascular anomalies are the most common congenital deformities observed in infants and children. They frequently involve the head, neck and oral cavity.¹ However, vascular anomalies are rarely seen in the maxilla and mandible.² The first use of the term “aneurysm by anastomosis” to describe a congenital arteriovenous malformation (AVM) is attributed to the father of vascular surgery, John Bell, in 1815.¹ The differences between true hemangiomas and vascular malformations were correctly recognized in 1818 by a London surgeon, James Wardrop.¹ Throughout the years, various classifications have continued to evolve for vascular anomalies, including the classification by Mulliken and Glowacki,³ which proved to be a breakthrough. However, according to these classifications, only the involuting vascular lesions were classified into hemangiomas,

and all the non-involuting ones were considered vascular malformations, which occasionally created a dilemma during diagnosis.

Recently, a newer classification has been proposed by the International Society for the Study of Vascular Anomalies (ISSVA, 2014).⁴ In this classification, within the category of vascular tumours, involuting hemangiomas of previous classifications^{1,3} have been categorised as rapidly involuting congenital hemangioma (RICH). Meanwhile, new subcategories of non-involuting congenital hemangioma (NICH) and partially involuting congenital hemangioma (PICH) have been added. This classification has enabled the classification of a number of lesions that were not classifiable as either an involuting hemangioma or vascular malformation in the previous classification systems. Such a situation is encountered when a lesion has clinical and imaging characteristics suggestive of hemangioma, but does not involute, as we noted in one of our cases. In this case, the lesion persisted until adulthood in a non-progressive state, with engulfment of the adja-

Received October 29, 2014; Revised January 11, 2015; Accepted March 21, 2015

*Correspondence to : Dr. Sinny Goel

Department of Oral Medicine and Radiology, Maulana Azad Institute of Dental Sciences, MAMC Campus, Delhi Gate, Central Delhi, 110002, India
Tel) 91-78-38675221, Fax) 91-11-23217081, E-mail) sgoeldoc@gmail.com

cent bone. Doppler ultrasonography (USG) had shown slow vascular flow. However, other imaging characteristics seen with computed tomography (CT) and magnetic resonance imaging (MRI) were suggestive of a hemangioma and were similar to those of a high-flow lesion; they were not those characteristic of a low-flow vascular malformation. Hence, according to the ISSVA (2014) classification, such lesions can be characterised as either NICH or PICH.⁴ It is important to distinguish between a hemangioma and vascular malformation, as treatment differs markedly for these lesions,^{5,6} and life-threatening complications could occur during treatment procedures.³ Hemangiomas, being the result of abnormal cellular proliferation, often respond to treatment with corticosteroids⁶ and irradiation (although the latter is not recommended),⁷ while vascular malformations have stable cellularity and thus may require embolization and surgical resection.^{2,8}

The aim of this pictorial essay is to describe the difficulties encountered by the diagnostician during diagnosis of vascular lesions with older classification systems and to illustrate the importance of a newer classification system (ISSVA 2014) in addressing these difficulties. We present here five cases of vascular anomaly of the head and neck and discuss the diagnosis of each lesion in accordance with the ISSVA (2014) classification.

Cases

Case 1

A 49-year-old female reported with a swelling of the lower lip, present since birth. The lesion was excised at the age of 3 years, but had progressed gradually to the present size over the years. On clinical examination, the lower lip was swollen and firm, febrile with no pulsations felt on palpation (Fig. 1A). Doppler USG revealed heterogeneously echogenic soft tissue with a plexus of multiple tortuous and prominent vascular channels displaying systolic pulsatile blood flow suggestive of arteriovenous malformation (Figs. 1B-D). MRI revealed an iso-intense lesion on the T1-weighted image (Fig. 1E) and a hyper-intense lesion with flow voids within the lesion voids due to high blood flow in the T2-weighted image (Fig. 1C). Angiographic study showed a lesion composed of multiple small tortuous vessels, suggestive of nidus; with arterial feeders arising from the right and left facial arteries and dilated draining veins (Fig. 1G). On the basis of these findings, a diagnosis of high-flow AVM was made.

Case 2

An 18-year-old girl presented with painless hard swelling in the left maxillary buccal alveolus region that had been present for the past 3 years. It had initially increased in size progressively; however, it had remained constant in size for the past 2 years. On examination, the swelling was poorly localized, extending from the left first molar region to the midline, about 4 cm × 2 cm in size, and was raised 1 cm above the surface, with the adjacent teeth inferiorly displaced (Fig. 2A). Swelling was bony hard and non-tender, with an irregular surface on palpation. A panoramic radiograph revealed an ill-defined radiolucency with a sparse trabecular pattern in the left maxillary alveolus region (Fig. 2B). The CT image revealed an expansile lesion with coarse, sparse trabeculae, extending from the left first molar region to the midline (Fig. 2C). Based on these clinical and radiographic findings, a provisional diagnosis of fibrous dysplasia was made. However, a contrast-enhanced CT (CECT) scan of the area revealed an ill-defined enhancing soft tissue mass lesion with involvement of the left maxillary alveolar arch with its expansion and rarefaction. In the arterial phase of CECT scan, enhancing vascular channels were seen with feeder vessels from the left facial artery, without any dilatation of the supplying vessel (Fig. 2D). In the delayed phase, homogeneous enhancement of the lesion was seen (Fig. 2E). Thus these findings were suggestive of slow-flow venous malformation.

Case 3

A 26-year-old female reported with a soft painful swelling in the left submandibular region (Fig. 3A). The patient noticed the swelling at the age of 12 years when it was pea sized, and it progressively increased to a size of approximately 2.5 cm × 3 cm until the age of 18 years; thereafter, the swelling had remained constant in size. There was a history of frequent bleeding from the gums in the same region. The patient was in the first trimester (40 days) of pregnancy when she reported to us. However, during follow-up visits there was no increase in the size of the lesion, irrespective of the hormonal changes of pregnancy.

A panoramic radiograph revealed a well-defined radiolucency in the left mandibular angle region with a scooped-out appearance and smooth margins, with a sharp spicule projecting inferiorly from the inferior margin. There was effacement of the posterior aspect of the inferior cortical wall of the inferior alveolar canal (Fig. 3B). Delayed-

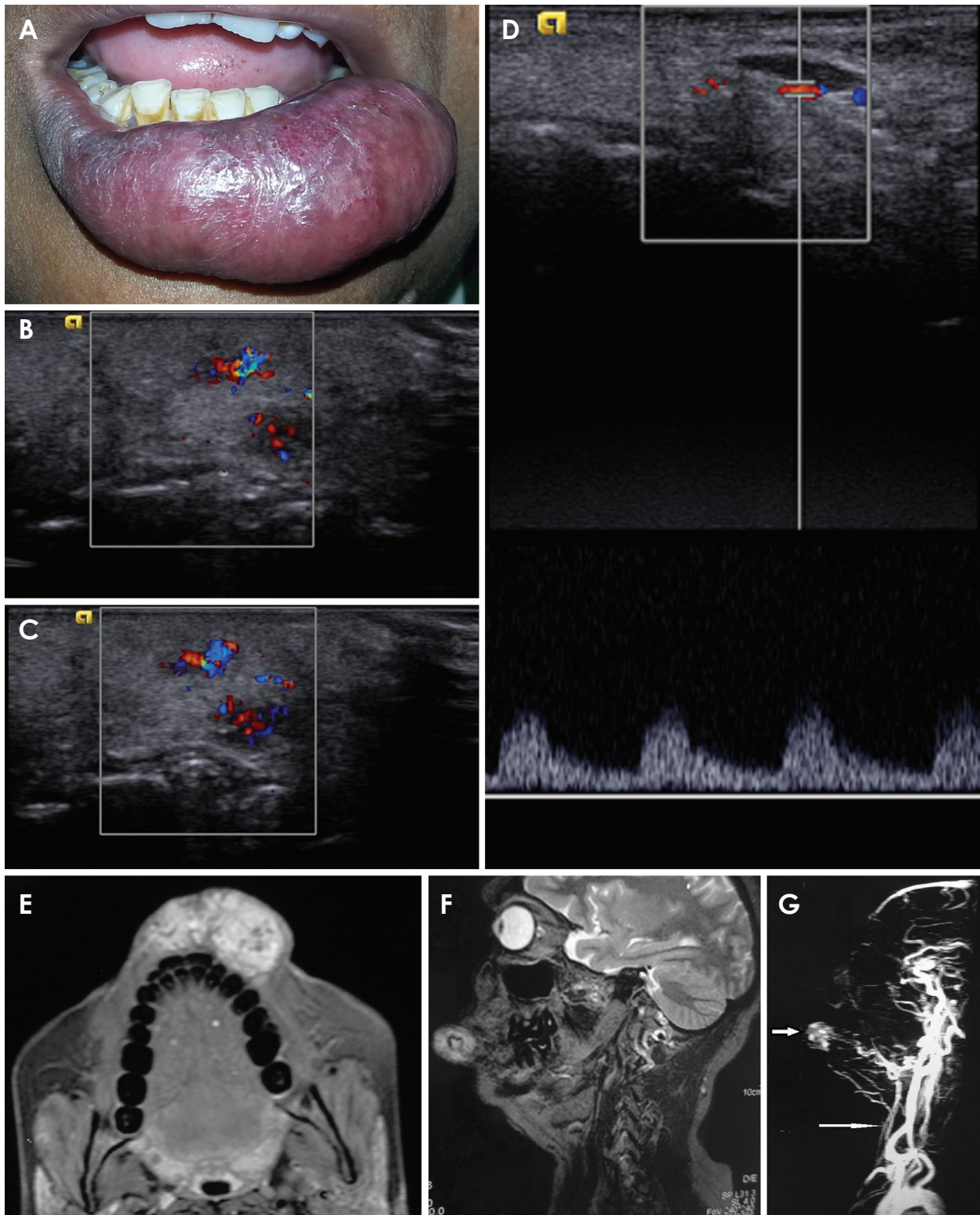


Fig. 1. High-flow vascular malformation of the lower lip in a 49-year-old female. A. Swelling of the lower lip with a reddish tinge and bluish mucosal junction. B and C. Doppler ultrasonography images show heterogeneously echogenic soft tissue with a plexus of multiple tortuous and prominent vascular channels. D. A Doppler ultrasonography image displays systolic pulsatile blood flow suggestive of arteriovenous malformation. E. A T1-weighted axial magnetic resonance image shows an ill-defined, iso-intense lesion in the lower lip. F. A T2-weighted, fat-saturated sagittal magnetic resonance image shows a hyper-intense lesion with flow voids within the lower lip. G. A magnetic resonance angiographic image reveals tortuous vessels (short arrow) within the lesion deriving their supply from a branch of the left facial artery with an early draining vein (long arrow).

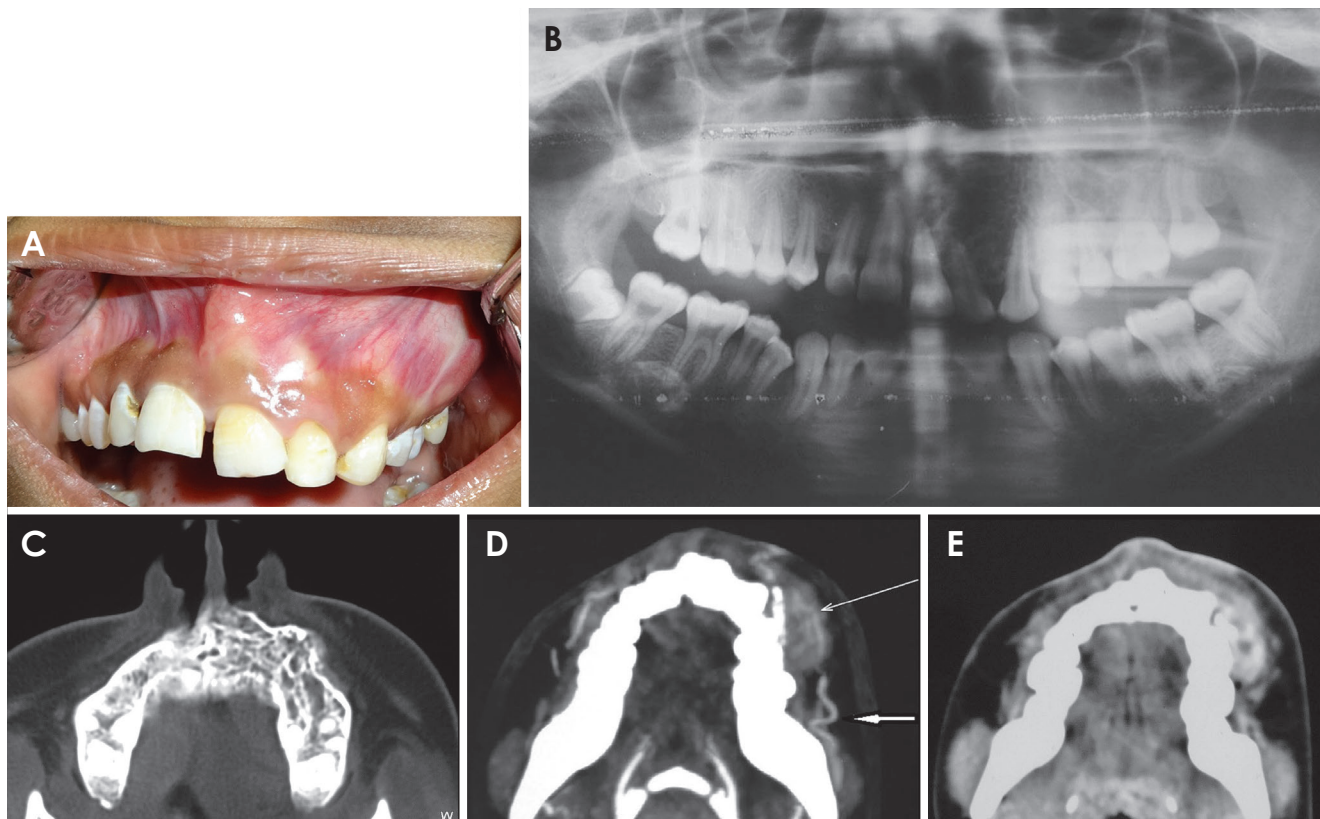


Fig. 2. Venous malformation of the left maxilla in an 18-year-old female. A. A photograph shows swelling of the left maxillary alveolus region with ill-defined margins, an irregular surface and displacement of teeth inferiorly with step formation. B. A panoramic radiograph shows an ill-defined radiolucent lesion in the left maxillary incisor canine region with sparse trabeculae. C. An axial non-contrast computed tomographic image shows an expansile lesion of the left maxillary region with coarse thickened trabeculae. D. The dynamic axial arterial phase-contrast computed tomographic image shows a soft tissue mass (long thin arrow) with a feeder vessel from the left facial artery (short thick arrow). E. The delayed-phase axial contrast-enhanced computed tomography image shows homogeneous enhancement of the lesion.

phase CECT scan revealed dilated serpentine venous channels (Figs. 3C and D). A T2-weighted MR image revealed a diffuse heterogeneous hyper-intense lesion without any mass formation, abutting the ramus-angle region, extending anteriorly into the left pterygomandibular space, with infiltration into the left medial pterygoid and masseter muscles and subcutaneous thickening. No abnormal signal flow voids typical of the high-flow lesions were seen (Figs. 3E and F). Doppler USG revealed a venous pattern with slow flow (Fig. 3G). No systemic skeletal osteolytic lesions could be seen in the other skeletal radiographs. Based on these findings, the lesion was diagnosed as non-involuting congenital hemangioma (NICH).

Case 4

A 35-year-old female patient reported with painful diffuse swelling in the left temporomandibular joint (TMJ) and ramus region (Fig. 4A) that had been present for the previous 18-20 years. There was a history of chronic mod

erate dull continuous pain. The left masseter muscle was tender on palpation. Based on the clinical findings, it was provisionally diagnosed as chronic centrally mediated myalgia. However, a panoramic radiograph revealed multiple spherical radiopaque structures in the area posterior to the left maxillary molar region (Fig. 4B) suggestive of phleboliths associated with a vascular lesion. A venous pattern of flow was seen on Doppler USG imaging. The findings were confirmed with CECT images, which revealed heterogeneous enhancement of the left parotid with involvement of the inter-muscular planes between the medial pterygoid, lateral pterygoid, and temporalis muscles: Superficially, it involved the left masseter with few tubular structures extending into the overlying subcutaneous tissue (Fig. 4C). Based on the above findings, the case was diagnosed as slow-flow venous malformation.

Case 5

A 35-year-old male patient reported with a swelling in

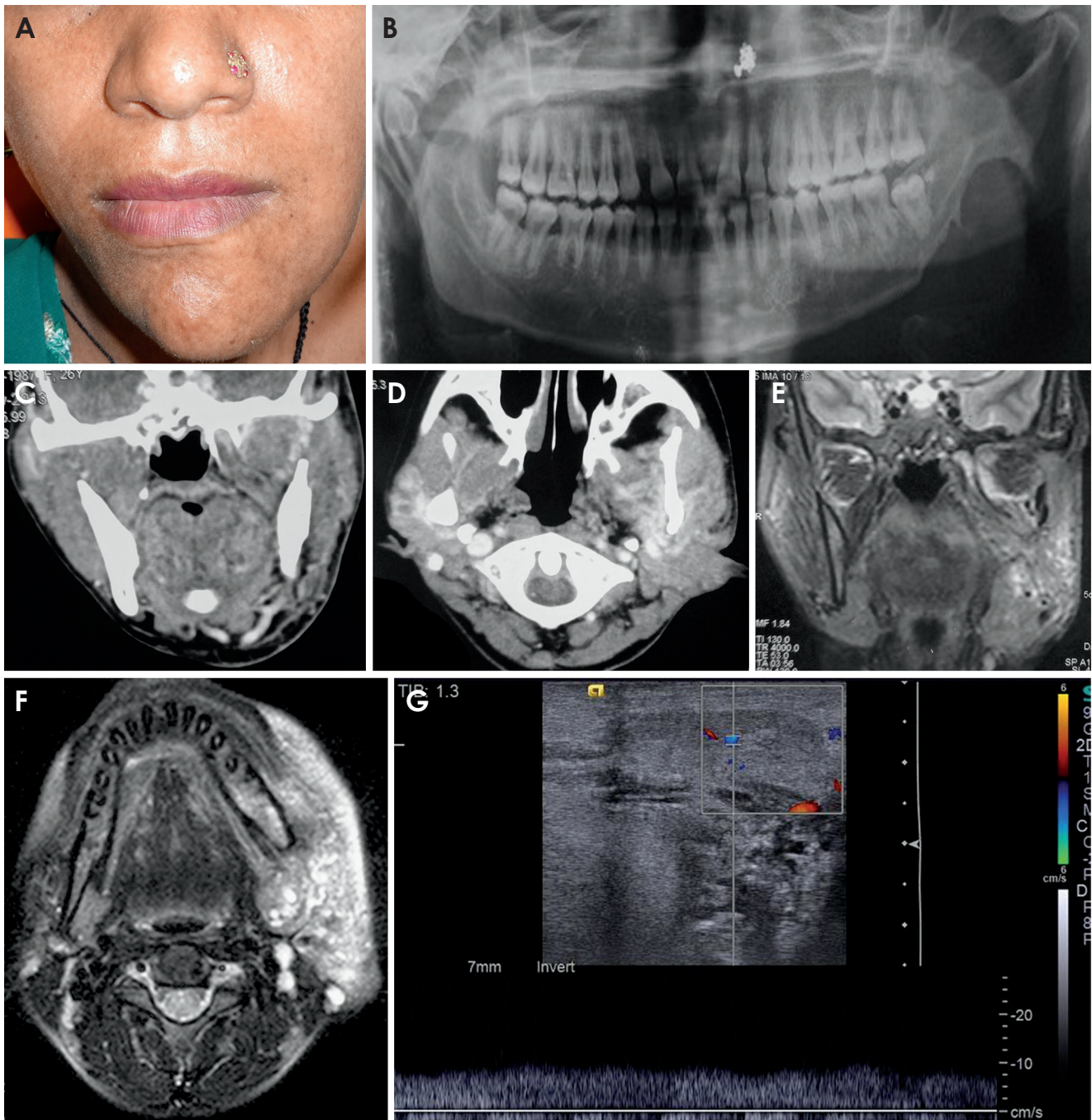


Fig. 3. Non-involuting congenital hemangioma in a 26-year-old female. A. A photograph shows facial asymmetry due to swelling in the left side of the mandible. B. A panoramic radiograph shows bone remodelling and resorption with scalloped margins in the left mandibular angle region with an overlying soft tissue component. C. A coronal contrast-enhanced computed tomographic image reveals multiple dilated vascular channels in the left mandibular angle region. D. An axial contrast-enhanced computed tomographic image reveals an ill-defined enhancing lesion infiltrating the left masseter and left pterygoid muscles with serpentine vascular channels within. E. A coronal T2-weighted magnetic resonance image reveals bulky deep and superficial lobes of the left parotid gland, with heterogeneous hyper-intensity superiorly and loss of fat planes with the adjacent muscles. No abnormal signal flow voids are evident. F. An axial T2-weighted magnetic resonance image reveals bulky deep and superficial lobes of the left parotid gland, with heterogeneous hyper-intensity involving the overlying fat planes. G. A Doppler ultrasonography image is suggestive of slow venous flow

the left submandibular and parotid region that had been present since birth and was firm on palpation with a high-

er surface temperature than the surrounding region. CECT images revealed multiple serpentine dilated channels in

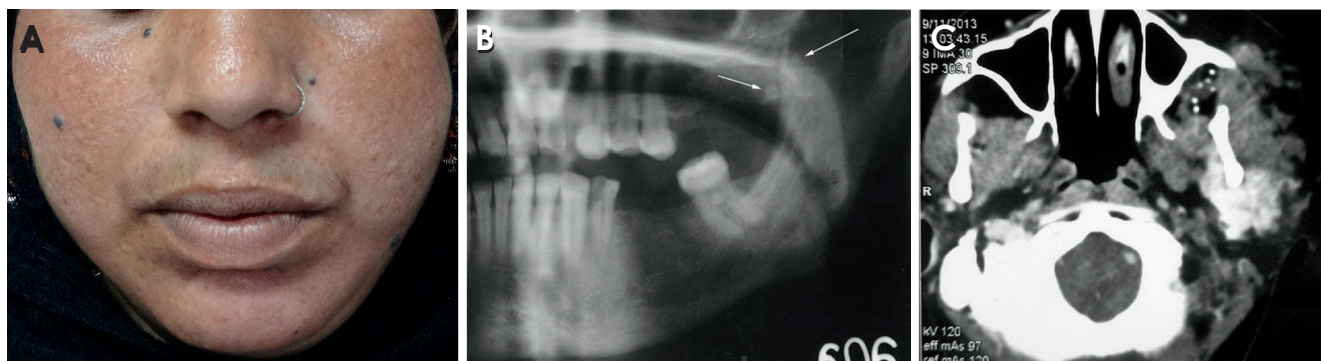


Fig. 4. A. A photograph shows slight facial asymmetry due to swelling in the left temporomandibular joint region. B. A panoramic radiograph reveals phleboliths posterior to the left maxillary tuberosity region (arrows). C. An axial delayed-phase contrast-enhanced computed tomographic image reveals heterogeneous contrast enhancement of the posterior lobe of left parotid gland with superficial extensions and phleboliths in the infratemporal fossa.

the left submandibular and parotid regions with extension into the post-auricular region suggestive of the unusual presence of two separate vascular lesions (Figs. 5A-C). Doppler USG was suggestive of high-flow arteriovenous malformation (Figs. 5D-F).

Discussion

Vascular malformations are the result of errors of vascular development between the 4th and 6th weeks of gestation and are clearly distinct from hemangiomas, which are benign tumours with endothelial proliferation rather than the abnormal vascular morphogenesis seen in vascular malformations.⁹ Recently, the ISSVA has considered the inclusion of partially involuting (PICH) or non-involuting (NICH) hemangiomas, along with the rapidly involuting hemangioma (RICH), in its classification system.⁴

RICH may or may not be present at birth. It enlarges rapidly during the first weeks of life, but its size then remains unchanged until the age of 12-18 months. After that, up to the age of 5 years, they tend to diminish in size and spontaneous involution is usually complete,^{3,4,10} while PICH and NICH persist into adulthood.⁴ PICHs are congenital hemangiomas with a distinct behaviour, evolving from RICH to persistent NICH-like lesions.¹¹ Hemangiomas may be located superficially or deeply. If they are deep, only slight discoloration of the overlying skin may be evident. On palpation, hemangiomas have a firm, rubbery consistency in the proliferation phase in contrast to vascular malformations, which usually feel soft and are easily compressible.¹²

In Case 3, the lesion was neither an involuting hemangioma, as it had persisted into adulthood, nor was it classi-

fiable as a vascular malformation; thus a diagnosis of NICH was made. The lesion was not classifiable as vascular malformation because there was slow venous flow seen with Doppler USG but no mass lesion characteristic of venous malformation¹³ was seen on CECT scan or T2-weighted MRI. Furthermore, there was engulfment of the adjacent bone with a margin of regular resorbed bone with a spicule over it. Although venous malformations can be associated with bone distortion, engulfment of bone is found in association with hemangiomas, as reported by Donnelly et al.¹³ Case 3 showed no increase in the lesion size during pregnancy, while vascular malformations increase in size with hormonal changes.⁸ Thus, our finding of this rare lesion, being classified as NICH, is in accordance with the newer ISSVA classification.⁴ On MRI, the solid component of the hemangioma demonstrates a signal intensity that is iso-intense or slightly hyper-intense to muscle on T1-weighted and hyper-intense to muscle on T2-weighted images.¹⁴

With Doppler US, AVM appears as a heterogeneous lesion with multiple hypoechoic channels, high flow, low resistance and arterialization of the draining veins.¹⁵ CT and MRI demonstrate enlarged vascular channels without an associated soft-tissue mass, but there may be ill-defined peri-lesional T2-weighted hyperintensity and contrast enhancement due to oedema and venous congestion.¹⁴ This feature can be confused with hemangioma,¹⁴ as in Case 3 (NICH), where the CT and T2-weighted MR appearance was similar to AVM; however, Doppler US findings and an absence of multiple arterial feeder vessels excluded the AVM. Angiography demonstrates dilated vessels with multiple feeders from the external carotid artery in AVM.^{16,17}

Most venous malformations are superficial, cold, soft,

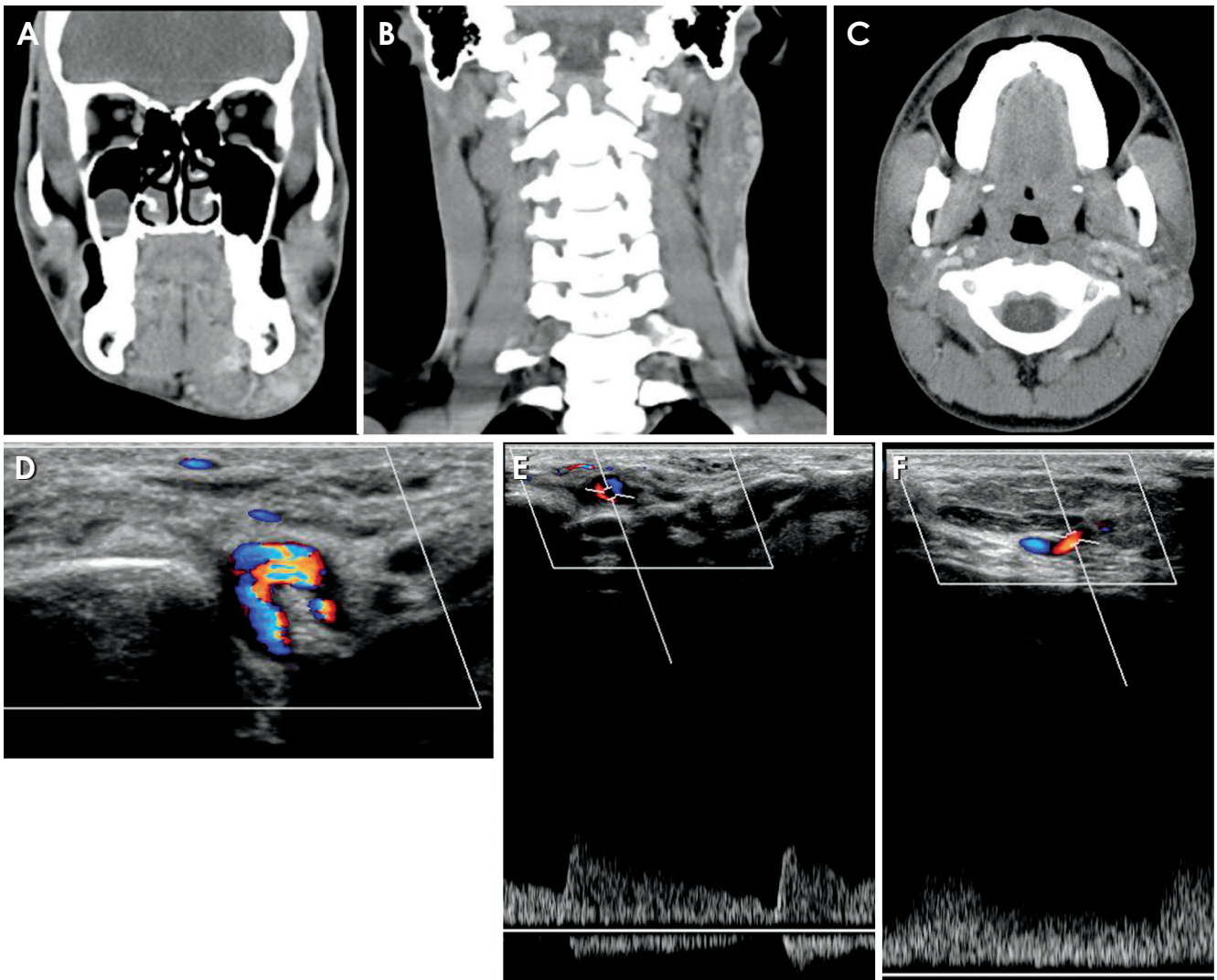


Fig. 5. A. A frontal contrast-enhanced computed tomographic (CECT) image of high-flow vascular malformation shows unusual presence of two separate lesions on the same side of the face. A tangle of serpiginous vessels are present in relation to the anterior belly of the digastric muscle and submandibular space on the left side. B. A coronal CECT image shows the lesion in the relation to the left sternocleidomastoid muscle. C. An axial CECT image shows the lesion in the relation to the posterior aspect of the superficial lobe of the left parotid gland. D and E. Doppler ultrasonography images show tortuous dilated vessels in the substance of the anterior belly of the digastric muscle with color flow within showing the arterial pattern. F. A Doppler ultrasonography image shows tortuous vessels in relation to the parotid gland, showing color flow within and the arterial pattern of flow.

compressible, bluish masses, usually diagnosed clinically.⁵ Adjacent bony structures are often deformed, and invasion of adjacent muscles is common. Thrombosis may be evident with larger lesions, apparent as phleboliths with imaging (Case 4),^{18,19} which is unique to venous malformations.^{20,21} MRI demonstrates an intermediate T1-weighted signal, and markedly hyper-intense T2-weighted and STIR signals. A “bunch-of-grapes” configuration with septations is characteristic, as in Case 2 and Case 4. Occasional dysplastic draining veins and flow voids corresponding to phleboliths are additional features.^{14,22,23} These

lesions are inconspicuous or show late enhancement with time-resolved MR angiography.²⁴ Angiography is rarely necessary unless large vascular connections are suspected, and pure VMs are usually angiographically occult.²⁵

Vascular malformations do not have a characteristic pattern on plain radiographs and produce a poorly defined, radiolucent image, often having honeycomb radiolucencies as in Case 2 of intra-osseous venous malformation or as ill-defined lesions.^{26,27} These appearances make intra-osseous vascular malformations easier to confuse with other pathologies including osteosarcoma, fibrous

dysplasia and central giant cell granuloma;²⁸ this is similar to our Case 2, where the initial provisional diagnosis was fibrous dysplasia, but the lesion was sharply confined to the midline which was different from fibrous dysplasia. Panoramic radiograph showed phleboliths in Case 4 with soft tissue involvement. Both of these cases were diagnosed as venous malformations after advanced imaging modalities.

After conventional radiography, CT is usually the initial imaging examination and can easily reveal the calcified and hyper-attenuating structures representing draining veins and components of the nidus, suggesting a diagnosis of venous vascular malformation.²⁹ CT and MRI clearly delineate the anatomic extent of a mass. USG with Doppler can distinguish venous from arterial flow and offer a graphic visual demonstration of vascularity.³⁰ Diagnostically, angiography is most useful for investigating extensive complex vascular lesions with major “feeding” vessels derived from the ipsilateral and/or contralateral circulation.³⁰ Venous malformations demonstrate dilated vascular spaces that fill in the venous phase. The feeding arteries are normal in diameter and do not increase in number;³¹ this is exemplified by our Case 2. On the other hand, AVMs demonstrate marked enlargement and an increased number of arteries, small vessels and veins.³¹

Vascular malformations arise during fetal development as a result of failure of regression of arteriovenous channels in the primitive retiform plexus.³² These primal arteriovenous communications persist and may expand later on as a result of an increase in blood flow and dilatation of the adjacent arteries and veins,⁹ as in pregnancy and puberty, supported by the fact that some patients first notice the malformation at puberty; in others, deterioration occurs during pregnancy.⁸ Likewise, in our cases of venous malformation, the lesions were first reported by the patients during puberty only. Steal phenomena in vascular malformations due to shunting of blood may result in localised ischemia, resultant pain and ulceration.⁸ This occurred in Case 4, where the patient reported with pain in the TMJ and ramus region. Swelling was apparently not extensive enough to cause disfigurement to the patient, although the lesion was large in size as seen on the imaging findings with masseteric space involvement and loss of fat planes.

Management of the vascular lesions varies depending upon the individual case.³³ Treatment options for malformations include embolization, radiotherapy, sclerotherapy, bone wax packing of bone cavities, and curettage or

surgical resection; with periodic observation. For hemangioma, observation, compression, sclerotherapy, corticosteroids, interferon- α , vincristine, or excision are the recommended treatment modalities.^{6,15-17,33-35}

Thus, it could be stated that a non-involuting lesion should not always be diagnosed as a vascular malformation, unlike in the previous classifications. A non-involuting lesion can be either hemangioma or a vascular malformation depending upon the clinicopathologic and imaging characteristics.

References

1. Mulliken JB, Young AE. Vascular birthmarks: hemangiomas and malformations. Philadelphia: Saunders; 1988.
2. Persky MS, Yoo HJ, Berenstein A. Management of vascular malformations of the mandible and maxilla. *Laryngoscope* 2003; 113: 1885-92.
3. Mulliken JB, Glowacki J. Haemangiomas and vascular malformations in infants and children: a classification based on endothelial characteristics. *Plast Reconstr Surg* 1982; 69: 412-22.
4. International Society for the Study of Vascular Anomalies [Internet]. Little Rock (AR): ISSVA classification for vascular anomalies [assessed 2014 Apr; cited 2014 Oct 28]. Available from: http://www.issva.org/content.aspx?page_id=22&club_id=298433&module_id=152904.
5. Lam SM, Williams EF. Vascular anomalies: review and current therapy. *Curr Opin Otolaryngol Head Neck Surg* 2002; 10: 309-15.
6. Thakral A, Sharma SM. Cervicofacial hemangiomas: pattern, clinical management, and treatment outcomes. *Oral Surg Oral Med Oral Pathol Oral Radiol* 2013; 116: e457-64.
7. Li FP, Cassady JR, Barnett E. Cancer mortality following irradiation in infancy for hemangioma. *Radiology* 1974; 113: 177-8.
8. Kohout MP, Hansen M, Pribaz JJ, Mulliken JB. Arteriovenous malformations of the head and neck: natural history and management. *Plast Reconstr Surg* 1998; 102: 643-54.
9. Takahashi K, Mulliken JB, Kozakewich HP, Rogers RA, Folkman J, Ezekowitz RA. Cellular markers that distinguish the phases of hemangioma during infancy and childhood. *J Clin Invest* 1994; 93: 2357-64.
10. Enjolras O, Riche MC, Merland JJ, Escande JP. Management of alarming hemangiomas in infancy: a review of 25 cases. *Pediatrics* 1990; 85: 491-8.
11. Nasser E, Piram M, McCuaig CC, Kokta V, Dubois J, Powell J. Partially involuting congenital hemangiomas: a report of 8 cases and review of the literature. *J Am Acad Dermatol* 2014; 70: 75-9.
12. Chang E, Boyd A, Nelson CC, Crowley D, Law T, Keough KM, et al. Successful treatment of infantile hemangiomas with interferon-alpha-2b. *J Pediatr Hematol Oncol* 1997; 19: 237-44.

13. Donnelly LF, Adams DM, Bisset GS 3rd. Vascular malformations and hemangiomas: a practical approach in a multidisciplinary clinic. *AJR Am J Roentgenol* 2000; 174: 597-608.
14. Meyer JS, Hoffer FA, Barnes PD. Biological classification of soft-tissue vascular anomalies: MR correlation. *AJR Am J Roentgenol* 1991; 157: 559-64.
15. Yakes WF, Rossi P, Odink H. How I do it. Arteriovenous malformation management. *Cardiovasc Intervent Radiol* 1996; 19: 65-71.
16. Yakes WF, Haas DK, Parker SH, Gibson MD, Hopper KD, Mulligan JS, et al. Symptomatic vascular malformations: ethanol embolotherapy. *Radiology* 1989; 170: 1059-66.
17. Gomes A. Embolization therapy of congenital arteriovenous malformations: use of alternate approaches. *Radiology* 1994; 190: 191-8.
18. Riche MC, Hadjean E, Tran-Ba-Huy P, Merland JJ. The treatment of capillary-venous malformations using a new fibrosing agent. *Plast Reconstr Surg* 1983; 71: 607-14.
19. Dubois JM, Sebag GH, De Prost Y, Teillac D, Chretien B, Brunelle FO. Soft-tissue venous malformations in children: percutaneous sclerotherapy with Ethibloc. *Radiology* 1991; 180: 195-8.
20. Ahuja AT, Richards P, Wong KT, Yuen EH, King AD. Accuracy of high-resolution sonography compared with magnetic resonance imaging in the diagnosis of head and neck venous vascular malformations. *Clin Radiol* 2003; 58: 869-75.
21. Burrows PE, Laor T, Paltiel H, Robertson RL. Diagnostic imaging in the evaluation of vascular birthmarks. *Dermatol Clin* 1998; 16: 455-88.
22. Baker LL, Dillon WP, Hieshima GB, Dowd CF, Frieden IJ. Hemangiomas and vascular malformations of the head and neck: MR characterization. *AJNR Am J Neuroradiol* 1993; 14: 307-14.
23. Gelbert F, Riche MC, Reizine D, Guichard JP, Assouline E, Hodes JE, et al. MR imaging of head and neck vascular malformations. *J Magn Reson Imaging* 1991; 1: 579-84.
24. Chooi WK, Woodhouse N, Coley SC, Griffiths PD. Pediatric head and neck lesions: assessment of vascularity by MR digital subtraction angiography. *AJNR Am J Neuroradiol* 2004; 25: 1251-5.
25. Burrows PF, Robertson RL, Barnes PD. Angiography and the evaluation of cerebrovascular disease in childhood. *Neuroimaging Clin N Am* 1996; 6: 561-88.
26. Loureiro CC, Falchet PC, Gavranich J, Lobo Leandro LF. Embolization as the treatment for a life-threatening mandibular arteriovenous malformation. *J Craniofac Surg* 2010; 21: 380-2.
27. Kakimoto N, Tanimoto K, Nishiyama H, Murakami S, Furukawa S, Kreiborg S. CT and MR imaging features of oral and maxillofacial hemangioma and vascular malformation. *Eur J Radiol* 2005; 55: 108-12.
28. Kondylidou-Sidira A, Dietrich EM, Koloutsos G, Sakkas L, Antoniadis K. Intraosseous vascular malformation of the mandibular condyle: presentation of a case and differential diagnosis. *Oral Radiol* 2012; 28: 150-6.
29. Mossa-Basha M, Chen J, Gandhi D. Imaging of cerebral arteriovenous malformations and dural arteriovenous fistulas. *Neurosurg Clin N Am* 2012; 23: 27-42.
30. Burrows PE, Mulliken JB, Fellows KE, Strand RD. Childhood hemangiomas and vascular malformations: angiographic differentiation. *AJR Am J Roentgenol* 1983; 141: 483-8.
31. Gold L, Nazarian LN, Johar AS, Rao VM. Characterization of maxillofacial soft tissue vascular anomalies by ultrasound and color Doppler imaging: an adjuvant to computed tomography and magnetic resonance imaging. *J Oral Maxillofac Surg* 2003; 61: 19-31.
32. Pribaz JJ, Morris DJ, Mulliken JB. Three-dimensional folded free-flap reconstruction of complex facial defects using intraoperative modeling. *Plast Reconstr Surg* 1994; 93: 285-93.
33. Kademani D, Costello BJ, Ditty D, Quinn P. An alternative approach to maxillofacial arteriovenous malformations with transosseous direct puncture embolization. *Oral Surg Oral Med Oral Pathol Oral Radiol Endod* 2004; 97: 701-6.
34. Altuğ HA, Büyüksoy V, Okçu KM, Doğan N. Hemangiomas of the head and neck with phleboliths: clinical features, diagnostic imaging, and treatment of 3 cases. *Oral Surg Oral Med Oral Pathol Oral Radiol Endod* 2007; 103: e60-4.
35. Konas E, Canter HI, Cil B, Peynircioglu B, Karabulut E, Tuncbilek G, et al. Volumetric assessment of results of treatment of vascular malformations of the head and neck regions treated with a minimally invasive surgical technique after embolization procedure. *J Craniofac Surg* 2009; 20: 402-5.