

A new bite block for panoramic radiographs of anterior edentulous patients: A technical report

Jong-Woong Park¹, Khanthaly Symkhampha², Kyung-Hoe Huh¹, Won-Jin Yi¹, Min-Suk Heo^{1,*}, Sam-Sun Lee¹, Soon-Chul Choi¹

¹Department of Oral and Maxillofacial Radiology and Dental Research Institute, School of Dentistry, Seoul National University, Seoul, Korea

²Division of Oral and Maxillofacial Radiology, Department of Basic Science, Faculty of Dentistry, University of Health Sciences, Vientiane, Laos

ABSTRACT

Purpose: Panoramic radiographs taken using conventional chin-support devices have often presented problems with positioning accuracy and reproducibility. The aim of this report was to propose a new bite block for panoramic radiographs of anterior edentulous patients that better addresses these two issues.

Materials and Methods: A new panoramic radiography bite block similar to the bite block for dentulous patients was developed to enable proper positioning stability for edentulous patients. The new bite block was designed and implemented in light of previous studies. The height of the new bite block was 18 mm and to compensate for the horizontal edentulous space, its horizontal width was 7 mm. The panoramic radiographs using the new bite block were compared with those using the conventional chin-support device.

Results: Panoramic radiographs taken with the new bite block showed better stability and bilateral symmetry than those taken with the conventional chin-support device. Patients also showed less movement and more stable positioning during panoramic radiography with the new bite block.

Conclusion: Conventional errors in panoramic radiographs of edentulous patients could be caused by unreliability of the chin-support device. The newly proposed bite block for panoramic radiographs of edentulous patients showed better reliability. Further study is required to evaluate the image quality and reproducibility of images with the new bite block. (*Imaging Sci Dent* 2015; 45: 117-22)

KEY WORDS: Panoramic, Radiography; Bite Block; Reproducibility of Results

Introduction

With edentulous patients, it is difficult to secure suitable positioning when taking panoramic radiographs and also it is hard to assess the positioning by means of inspecting anatomical structures such as the occlusal plane, antero-posterior position of the anterior teeth, and symmetry in their panoramic radiographs after taken. Several stud-

ies have examined the difficulties of taking panoramic radiographs of edentulous patients. Without distinguishing between dentulous and edentulous images, Dhillon et al.¹ noted that most panoramic radiographs had at least one error. Glass et al.² reported that 89% of panoramic radiographs of edentulous patients had at least one error, which included the following positions: chin too high, too far forward, tongue not raised, chin too low, head tilted, head turned, and too far back. Batenburg et al.³ showed that panoramic radiographs without positioning reproducibility were not reliable for diagnosis and evaluation of the edentulous mandible. Accuracy and reproducibility of edentulous patients' panoramic radiographs are important for dental diagnosis and treatment planning because

*This study was supported by grant no. 04-2012-0058 from the SNUDH Research Fund.

Received February 2, 2015; Revised March 3, 2015; Accepted March 15, 2015

*Correspondence to : Prof. Min-Suk Heo

Department of Oral and Maxillofacial Radiology, School of Dentistry, Seoul National University, 101 Daehak-ro, Jongno-gu, Seoul 110-749, Korea
Tel) 82-2-2072-3016, Fax) 82-2-744-3919, E-mail) hmslsh@snu.ac.kr

panoramic radiographs have been widely used in cases of the screening of cysts, foreign bodies, and neoplasms,^{4,6} finding bone resorption and osteopenia of the jaws,⁷⁻⁹ and installing implants.¹⁰

Conventional bite blocks and chin-support devices, such as the ones included with the Orthopantomograph® OP100 (Imaging Instrumentarium, Tuusula, Finland) (Figs. 1A and B,

respectively), are widely available for positioning anterior edentulous patients during panoramic radiography.¹¹ The chin-support device is more commonly used than the conventional bite block because the height of the bite block is 12 mm, which seems to provide an insufficient vertical dimension for the edentulous area.

However, using the chin-support device for panoramic radiography has also presented some problems. Panoramic radiographs using the chin-support device have frequently shown insufficient inter-maxillary space and lack of reproducibility (Fig. 2). According to the study of Park et al.,¹² the reproducibility of panoramic radiographs of edentulous patients using a conventional chin-support device was worse than that of dentulous patients. Therefore, a new bite block for edentulous patients is required to improve the accuracy and reproducibility of panoramic radiographs of edentulous patients by improving the accuracy and reproducibility of positioning patients for taking panoramic radiographs.

The aim of this report is to propose a new bite block for panoramic radiographs of edentulous patients that could




Fig. 1. A. The conventional bite block for anterior edentulous patients. B. The chin-support device for anterior edentulous patients.

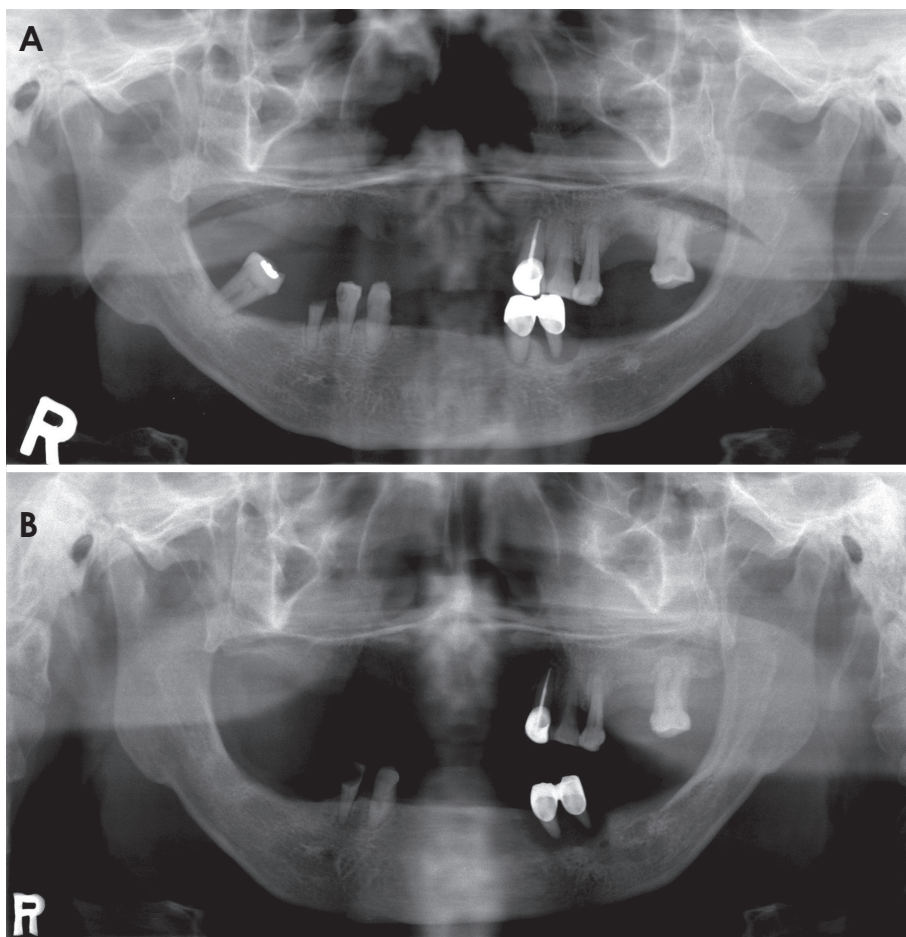


Fig. 2. A and B. Two panoramic radiographs acquired from the same anterior edentulous patient using a conventional chin-support device show lack of reproducibility in the inter-maxillary vertical dimension.

enable a greater degree of accuracy and reproducibility in patient positioning, and reduce the weaknesses of panoramic radiographs taken with a chin-support device.

Materials and Methods

A new bite block for edentulous patients was designed to bring reproducibility when taking panoramic radiographs to a similar level as that of a bite block for dentulous patients. The new bite block for edentulous patients involved modifications in the bite portion that could compensate for the missing anterior teeth and resorbed anterior alveolar bone tissue of anterior edentulous patients. The dimensions of the missing and resorbed tissues were determined by referring to previous studies.

In detail, the new bite block (Fig. 3A) was designed to position anterior edentulous patients in the same manner as

anterior dentulous patients who could bite into the notches of a conventional standard bite block (Fig. 3B) while undergoing panoramic radiography. The new bite block needed to compensate for the area of missing anterior teeth and resorbed alveolar bone. To compensate for those areas, statistical analysis of measured tooth lengths, facio-lingual inclinations, and resorbed anterior alveolar bone dimensions were investigated in the literature. According to Volchansky and Cleaton-Jones,¹³ the mean sizes of teeth were 10.0 mm among the maxillary central incisors and 8.4 mm among the mandibular central incisors in those aged 20 to 40 years. Furthermore, the mean facio-lingual inclination of the maxillary central incisors was 33.50°, and that of the mandibular central incisors was 26.44°. The mean angle between the occlusal plane and Frankfort horizontal plane was 6.79°. Thus, the angle between the maxillary central incisor and vertical plane was 26.71°, and the angle between the mandibular central incisor and vertical plane was 19.65°. Also, the extent of anterior alveolar bone resorption was 5.90 mm in non-denture wearers and 6.69 mm in denture wearers in the maxillary central incisor area, and 7.07 mm in non-denture wearers and 13.03 mm in denture wearers in the mandibular central incisor area.¹⁶

Using these values, the vertical dimension and the antero-posterior horizontal distance (horizontal distance) of the new bite block was determined. For the vertical dimension, the vertical vector of the anterior tooth portion was calculated to be 16.85 mm, and the thickness of the bite position (notch) of the conventional standard bite block for dentulous patients of the Orthopantomograph® OP100 (2 mm) was taken into consideration. Thus, the vertical height of the new bite block was chosen to be 18.85 mm, and adjusted to 18 mm by trial and error (Fig.




Fig. 3. A. The new bite block for anterior edentulous patients. B. The conventional standard bite block for anterior dentulous patients.

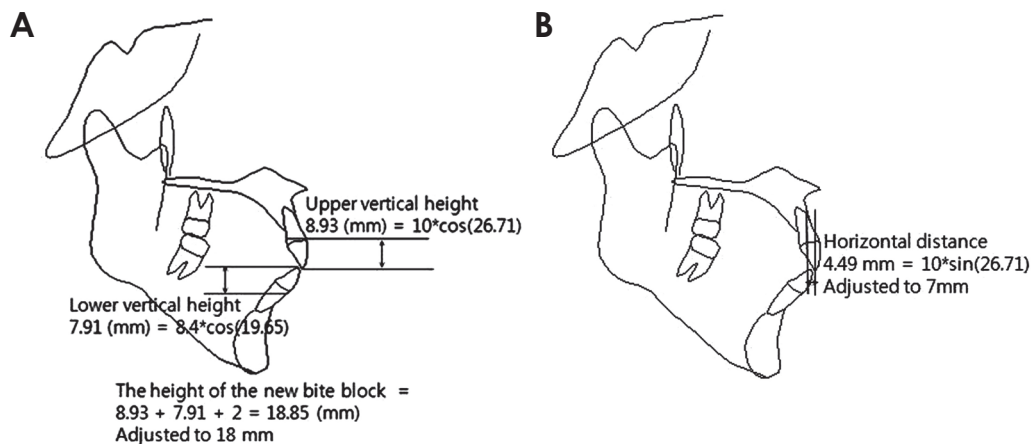


Fig. 4. A. The calculation to determine the height of the new bite block. B. The horizontal distance calculation to determine the antero-posterior dimension of the new bite block.

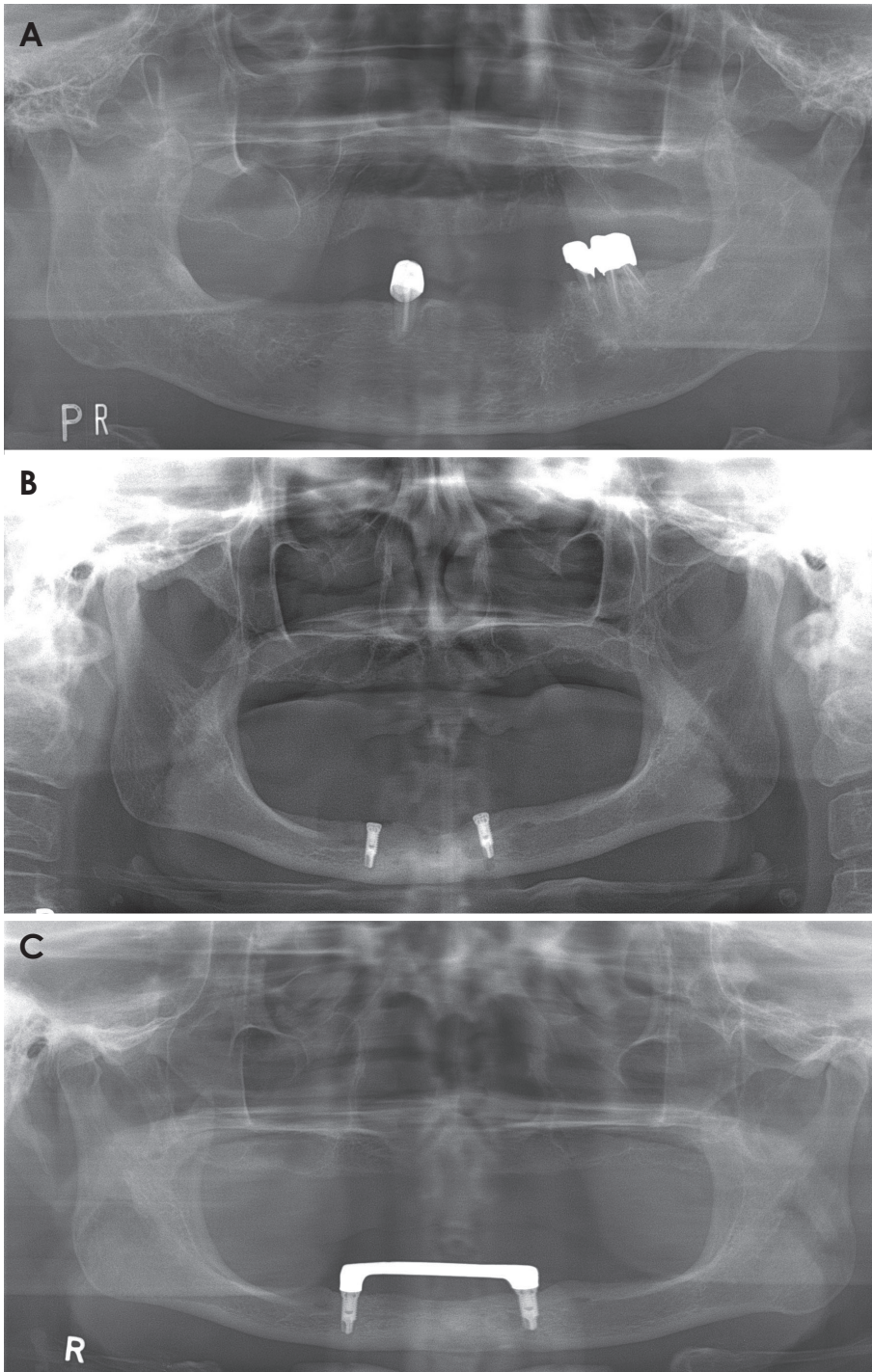


Fig. 5. Panoramic radiographs acquired from anterior edentulous patients using the conventional chin-support device. A. The radiograph shows insufficient inter-maxillary vertical height. B. The radiograph shows asymmetry although the patient's jaw is not asymmetrical. C. The panoramic radiographs acquired from an anterior edentulous patient using the conventional chin-support device show horizontal magnification.

4). For the horizontal distance, which is the difference between the lengths from the panoramic radiograph sensor to the standard block's notch and to the biting position of the new bite block, the horizontal vector of the anterior tooth portion was calculated to be 4.49 mm, and the horizontal vector of the resorbed bone portion was considered to be in the range from 2.65 mm to 3.00 mm. The hori-

zontal distance for the new bite block was chosen to be 5 mm (4.49 mm), and was adjusted to 7 mm by trial and error (Fig. 4).

Panoramic radiographs of anterior edentulous patients were taken using the new bite block. Then, the panoramic radiographs were compared with the radiographs taken previously using conventional chin-support device. Then

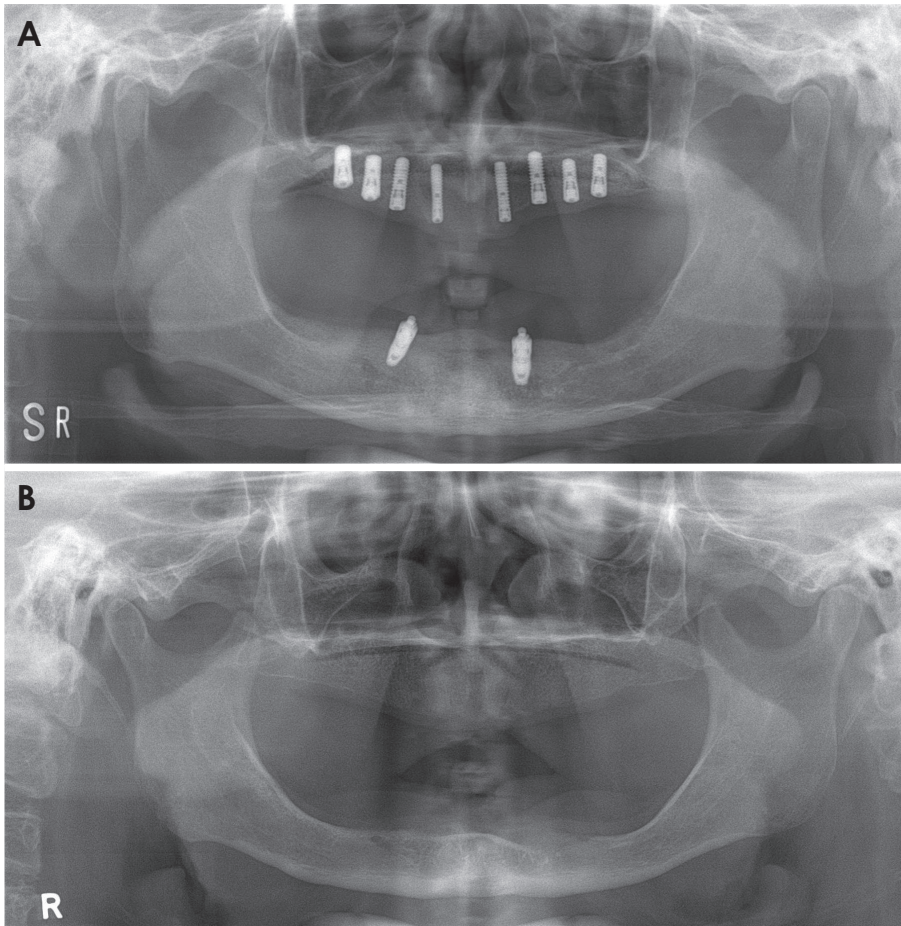


Fig. 6. A and B. The panoramic radiographs taken using the new bite block showed a more suitable vertical height and antero-posterior position, and better bilateral symmetry than the panoramic radiographs taken using the chin-support device.

the reproducibility and technical errors of the radiographs using the conventional chin-support device were evaluated and compared to the radiographs using the new bite block.

Results

Some radiographs taken with the chin-support device have shown insufficient inter-maxillary space (Fig. 5A), and others have lacked reproducibility of anatomical structural dimensions, especially in the horizontal direction (Fig. 5B). The chin-support device might not provide appropriate reproducible and accurate positioning in taking panoramic radiographs.

Panoramic radiographs taken with the new bite block showed better stability in inter-maxillary vertical space, antero-posterior position, and bilateral symmetry than radiographs taken with the conventional chin-support device (Fig. 6). In addition, according to the radiographers' statements, the patients using the new bite block showed less movement and more stable positioning while undergoing panoramic radiography.

Discussion

The panoramic radiographs of edentulous patients taken with the chin-support device showed some errors. These problems could have originated from the unreliability of the chin-support device in positioning patients while undergoing panoramic radiography. In other words, the chin-support device would provide inappropriate reproducibility and inaccurate positioning support. This finding was in accordance with those of Park et al.,¹² justifying the attempt to design a new bite block for panoramic radiographs of edentulous patients. Therefore, this new bite block was designed and implemented, and a patent was obtained on the bite block in the Republic of Korea (Registration No. 1299456).

The new bite block produced better inter-maxillary space, antero-posterior position, and bilateral symmetry in panoramic radiographs than the conventional chin-support device. These results might have originated from stable and accurate positioning of both of the jaws in taking panoramic radiographs with the new bite block.

However, ongoing evaluation of the new bite block should be carried out, including assessment of image quality and reproducibility. It will take time to accumulate panoramic radiographs taken with the new bite block in order to perform these assessments.

References

1. Dhillon M, Raju SM, Verma S, Tomar D, Mohan RS, Lakhanpal M, et al. Positioning errors and quality assessment in panoramic radiography. *Imaging Sci Dent* 2012; 42: 207-12.
2. Glass BJ, Seals RR Jr, Williams EO. Common errors in panoramic radiography of edentulous patients. *J Prosthodont* 1994; 3: 68-73.
3. Batenburg RH, Stellingsma K, Raghoobar GM, Vissink A. Bone height measurements on panoramic radiographs: the effect of shape and position of edentulous mandibles. *Oral Surg Oral Med Oral Pathol Oral Radiol Endod* 1997; 84: 430-5.
4. Kogon S, Bohay R, Stephens R. A survey of the radiographic practices of general dentists for edentulous patients. *Oral Surg Oral Med Oral Pathol Oral Radiol Endod* 1995; 80: 365-8.
5. Spyropoulos ND, Patsakas AJ, Angelopoulos AP. Findings from radiographs of the jaws of edentulous patients. *Oral Surg Oral Med Oral Pathol* 1981; 52: 455-9.
6. Swenson HM, Hudson JR. Roentgenographic examination of edentulous patients. *J Prosthet Dent* 1967; 18: 304-7.
7. Ortman LF, Hausmann E, Dunford RG. Skeletal osteopenia and residual ridge resorption. *J Prosthet Dent* 1989; 61: 321-5.
8. Soikkonen K, Ainamo A, Xie Q. Height of the residual ridge and radiographic appearance of bony structure in the jaws of clinically edentulous elderly people. *J Oral Rehabil* 1996; 23: 470-5.
9. Wical KE, Swoope CC. Studies of residual ridge resorption. I. Use of panoramic radiographs for evaluation and classification of mandibular resorption. *J Prosthet Dent* 1974; 32: 7-12.
10. Kaffe I, Ardekian L, Gelerenter I, Taicher S. Location of the mandibular foramen in panoramic radiographs. *Oral Surg Oral Med Oral Pathol* 1994; 78: 662-9.
11. Scarfe WC, Erasó FE, Farman AG. Characteristics of the Orthopantomograph OP 100. *Dentomaxillofac Radiol* 1998; 27: 51-7.
12. Park JW, Huh KH, Yi WJ, Heo MS, Lee SS, Choi SC. Comparison of the reproducibility of panoramic radiographs between dentulous and edentulous patients. *Imaging Sci Dent* 2014; 44: 95-102.
13. Volchansky A, Cleaton-Jones P. Clinical crown height (length) - a review of published measurements. *J Clin Periodontol* 2001; 28: 1085-90.
14. Tong H, Kwon D, Shi J, Sakai N, Enciso R, Sameshima GT. Mesiodistal angulation and faciolingual inclination of each whole tooth in 3-dimensional space in patients with near-normal occlusion. *Am J Orthod Dentofacial Orthop* 2012; 141: 604-17.
15. Sato M, Motoyoshi M, Hirabayashi M, Hosoi K, Mitsui N, Shimizu N. Inclination of the occlusal plane is associated with the direction of the masticatory movement path. *Eur J Orthod* 2007; 29: 21-5.
16. Canger EM, Celenk P. Radiographic evaluation of alveolar ridge heights of dentate and edentulous patients. *Gerodontology* 2012; 29: 17-23.