

Intraoperative Balloon Angioplasty Using Fogarty Arterial Embolectomy Balloon Catheter for Creation of Arteriovenous Fistula for Hemodialysis: Single Center Experience

Moran Jin, M.D., Young Chul Yoon, M.D., Jin Hong Wi, M.D., Yang-Haeng Lee, M.D.,
Il-Yong Han, M.D., Kyung-Taek Park, M.D.

Background: The purpose of this study was to evaluate the use of a Fogarty arterial embolectomy catheter (Fogarty catheter) in intraoperative balloon angioplasty of the cephalic vein, in order to determine its effect on the patency of arteriovenous fistulas (AVFs) created for hemodialysis access. **Methods:** A total of 156 patients who underwent creation of an AVF were divided into two groups, based whether a Fogarty catheter was used during AVF creation. Group A (89 patients) comprised the patients who underwent balloon angioplasty with a Fogarty catheter during the operation. Group B (67 patients) included the patients in whom a Fogarty catheter was not used during the operation. Patient records were reviewed retrospectively and documented. The patency rate was determined by the Kaplan-Meier method. **Results:** The records of 156 patients who underwent the creation of an AVF from January 2007 to October 2011 were included. The mean follow-up duration was 40.2±19.4 months (range, 1 to 97 months). The patency rates in group A at 12, 36, and 72 months were 83.9%±3.9%, 78.3%±4.6%, and 76.3%±4.9%, respectively, while the corresponding patency rates in group B were 92.5%±3.2%, 82.8%±0.5%, and 79.9%±5.7%, respectively. The patency rates in group B were found to be slightly higher than those in group A, but the difference was not statistically significant (p=0.356). **Conclusion:** Intraoperative balloon angioplasty of the cephalic vein using the Fogarty catheter is a simple and easily reproducible procedure, and it can be helpful in increasing AVF patency in cases of insufficient runoff or a suboptimal cephalic vein.

Key words: 1. Arteriovenous fistula
2. Balloon angioplasty
3. Renal dialysis
4. Vascular patency
5. Geriatric

INTRODUCTION

Autogenous arteriovenous fistula (AVF) for hemodialysis has appeared to be better to prosthetic graft or catheter access in patient morbidity and mortality. Moreover, the maintenance

of autogenous AVF is less expensive than that of a prosthetic conduit [1,2]. However, the creation of an AVF is not always possible in patients with an insufficient cephalic vein. Moreover, cephalic veins with diameters <2.5 mm have been reported to increase the immediate failure rate and to decrease

Department of Thoracic and Cardiovascular Surgery, Busan Paik Hospital, Inje University College of Medicine

Received: August 5, 2014, Revised: November 7, 2014, Accepted: November 18, 2014, Published online: April 5, 2015

Corresponding author: Young Chul Yoon, Department of Thoracic and Cardiovascular Surgery, Busan Paik Hospital, Inje University College of Medicine, 75 Bokji-ro, Busanjin-gu, Busan 614-735, Korea
(Tel) 82-51-890-6834 (Fax) 82-51-891-1297 (E-mail) ppcswoon@hanmail.net

© The Korean Society for Thoracic and Cardiovascular Surgery. 2015. All right reserved.

© This is an open access article distributed under the terms of the Creative Commons Attribution Non-Commercial License (<http://creativecommons.org/licenses/by-nc/3.0>) which permits unrestricted non-commercial use, distribution, and reproduction in any medium, provided the original work is properly cited.




Fig. 1. Fogarty Arterial Embolectomy Catheter (Edwards Laboratories, Santa Ana, CA, USA).

the primary patency rate [3]. Nonetheless, promising results have recently been reported regarding several surgical procedures that have been employed in cases where the cephalic vein is insufficient [3-5]. The purpose of this study was to assess how the use of a Fogarty arterial embolectomy catheter (Fogarty catheter) in intraoperative balloon angioplasty affects the primary patency rate of autogenous AVFs (Fig. 1).

METHODS

1) Patients

Of the 368 patients who underwent AVF creation in the Department of Thoracic and Cardiovascular Surgery at Busan Paik Hospital from January 2007 to October 2011, we included 156 patients who subsequently came to the Department of Internal Medicine for follow-up visits and hemodialysis. We excluded 212 patients who were dialyzed at other hospital after the operation.

The 156 patients who were included in the study were divided into two groups, based on whether a Fogarty catheter was used during AVF creation. A Fogarty catheter (3Fr or 4Fr; Edwards Laboratories, Santa Ana, CA, USA) was used for angioplasty during the operation if the 2.5-mm coronary dilator could not be easily passed into the cephalic vein, sufficient backflow could not be confirmed after venotomy, or if we could not confirm the presence of the thrill after AVF creation. Such cases were included in group A (n=89). The other cases, in which we did not use a Fogarty catheter, were included in group B (n=67). The records of patients included

in this study were retrospectively reviewed until June 2014. The mean follow-up duration was 40.2 ± 19.4 months (range, 1 to 97 months). We collected and documented demographic data including age, gender, body mass index, and co-morbidities such as diabetes, hypertension, tobacco use, cerebral infarction, coronary artery disease, and peripheral arterial obstructive disease.

2) Surgical technique

Preoperatively, each patient was clinically assessed using standard methods, including the Allen test for arterial competency, and by placing a tourniquet on the upper arm while the patient clenched and released the hand several times in order to examine the superficial veins under visual enhancement.

If venous patency in the forearm was satisfactory, a radiocephalic arteriovenous fistula (RCAVF) was created. Otherwise, a brachiocephalic AVF was created. If there was a possibility of stenosis or obstruction in the subclavian vein, the patient underwent upper extremity venous Doppler ultrasonography or conventional venography before surgery. Five patients underwent AVF creation using the basilic vein due to stenotic occlusion of the cephalic vein. All surgical procedures were performed by a single surgeon.

(1) Radiocephalic arteriovenous fistula: A 2-cm longitudinal incision was made after injecting the wrist with 2% lidocaine. The radial artery and the cephalic vein were dissected. Subsequently, arteriotomy and venotomy were performed after clamping the cephalic vein and radial artery using a bulldog vascular clamp. The proximal venous runoff in the cephalic vein was examined through the venotomy using a 2.5-mm coronary dilator. In cases where the coronary dilator could not be passed easily or backflow in the cephalic vein was insufficient, balloon dilatation of the cephalic vein was performed using a Fogarty catheter. A side-to-side anastomosis was performed using a 7-0 prolene suture. After continuous suturing, the cephalic vein was checked for the presence of the thrill, and the anastomosis was checked for bleeding and stenosis. The distal cephalic vein was then ligated and divided. If the thrill could not be confirmed after declamping the cephalic vein, balloon dilatation of the cephalic vein was performed using a Fogarty catheter inserted into the distal opening of the cephalic vein after re-clamping the radial artery.

Table 1. Baseline demographic and AVF characteristics

Variable	Total (n=156)	Group A (n=89)	Group B (n=67)	p-value
Male	96 (61.5)	53 (59.6)	43 (64.2)	0.556
Mean age (yr)	54.6±13.5	54.6±13.9	54.8±13.1	0.929
Body mass index (kg/m ²)	22.9±3.9	22.9±4.7	23.0±2.6	0.760
Mean duration from chronic renal failure diagnosis to AVF creation (mo)	43.1±46.8	44.2±47.3	41.7±46.4	0.750
Creatinine (mg/dL)	7.06±3.08	7.09±3.44	7.03±2.58	0.917
Estimated glomerular filtration rate (mL·min ⁻¹ ·1.73 m ⁻²)	9.56±5.03	9.85±5.90	9.18±3.63	0.431
Hypertension	131 (85.1)	73 (83.9)	58 (86.6)	0.646
Diabetes	80 (51.9)	40 (46.0)	40 (59.7)	0.091
Coronary artery disease	20 (13.0)	13 (14.9)	7 (10.4)	0.411
Peripheral artery disease	1 (0.6)	1 (1.1)	0 (0)	1.000
History of cerebrovascular accident	7 (4.5)	4 (4.6)	3 (4.5)	1.000
Tobacco use	10 (6.5)	8 (9.2)	2 (3.0)	0.188
Upper arm AVF	58 (37.2)	39 (43.8)	19 (28.4)	0.048
Left arm	132 (84.6)	75 (84.3)	57 (85.1)	0.684

Continuous data are shown as mean±standard deviation or median (range) and categorical data as number (%). AVF, autogenous arteriovenous fistula.

(2) Brachiocephalic arteriovenous fistula: A 3-cm transverse incision was made after injecting the antecubital fossa with 2% lidocaine. The brachial artery and the cephalic vein were dissected. Arteriotomy and venotomy were performed after clamping the cephalic vein and the brachial artery using a bulldog vascular clamp. The patency of the cephalic vein was then checked using a coronary dilator. Except for the side-to-end anastomosis, the other procedures were the same as those in the RCAVF procedure.

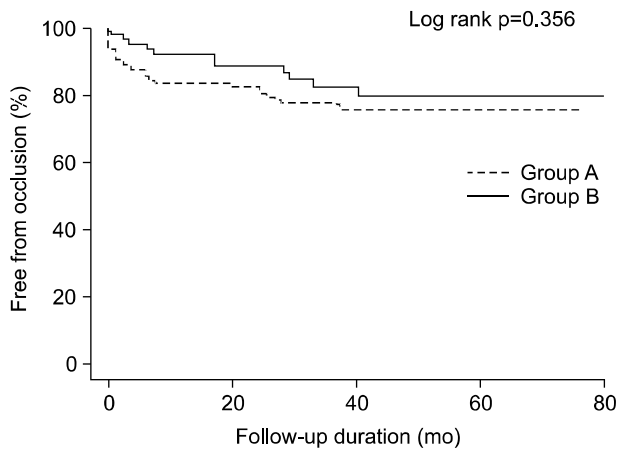
3) Statistical analysis

In order to analyze the characteristics of the two groups, continuous variables were compared using the t-test, and categorical variables were compared using the chi-square test or the Fisher's exact test. Patency rate curves were estimated with the Kaplan-Meier method. Differences between curves were compared using the log-rank test. In all of the statistical tests, statistical significance was defined as a two-tailed p-value <0.05. Statistical analysis was performed with IBM SPSS ver. 20.0 (IBM Co., Armonk, NY, USA). All of the results in this study are expressed as mean±standard deviation.

RESULTS

This study included 156 out of 368 possible patients. Of the patients who were included, 89 (57%) were included in group A (use of a Fogarty catheter), and 67 (43%) were included in group B (non-use of a Fogarty catheter).

A total of 156 AVFs were created in the forearm, and 98 AVFs were created in the upper arm. The mean patient age was 54.6±13.5 years and 61.5% were males. No significant differences were observed between the two groups with regard to gender, age, body mass index, mean duration from chronic renal failure diagnosis to AVF creation, creatinine levels, estimated glomerular filtration rate, hypertension, coronary artery disease, peripheral artery disease, and history of cerebrovascular accidents. The prevalence of diabetes was slightly higher in group B, and tobacco use was slightly higher in group A. However, these differences were not statistically significant (diabetes: 46.0% in group A vs. 59.7% in group B, p=0.091; tobacco use: 9.2% in group A vs. 3.0% in group B, p=0.188). There was a statistically significant difference between the two groups regarding the number of upper arm AVFs. Upper arm AVFs were more common in group A (43.8% in group A vs. 28.4% in group B, p=0.048). The patient characteristics are summarized in Table 1. Primary pa-



	12 mo	24 mo	36 mo	60 mo	72 mo
Group A (n=89)	83.9±3.9 (n=70)	81.2±4.2 (n=58)	78.3±4.6 (n=40)	76.3±4.9 (n=8)	76.3±4.9 (n=2)
Group B (n=67)	92.5±3.2 (n=58)	89.0±3.9 (n=50)	82.8±0.5 (n=30)	79.9±5.7 (n=12)	79.9±5.7 (n=4)

Fig. 2. Kaplan-Meier survival curves for patency.

teny (intervention-free access survival) was defined as the interval from the time of access placement to the time of fistula failure. The patency rates at 12, 36, and 72 months in group A were 83.9%±3.9%, 78.3%±4.6%, and 76.3%±4.9%, respectively, and the corresponding rates in group B were 92.5%±3.2%, 82.8%±0.5%, and 79.9%±5.7%, respectively. The patency rates in group B were found to be slightly higher than those in group A, but the difference was not statistically significant (p=0.356) (Fig. 2).

Fistula failure was defined as the presence of conditions preventing dialysis from being performed, such as thrombotic occlusion, venous hypertension, poor function of the fistula, recurrent cellulitis, and cephalic vein stenosis. Fistula failure occurred in 35 patients during the follow-up period. The causes of fistula failure were thrombotic occlusion (28 patients total; 17 patients in group A vs. 11 patients in group B, p=0.99), ligation due to venous hypertension (3 patients in group B, p=0.08), poor function (2 patients in group A, p=0.16), recurrent cellulitis (1 patient in group B, p=0.32), and cephalic vein stenosis (1 patient in group A, p=0.32). There were no statistically significant differences between the two groups with regard to fistula failure (Table 2). Among the cases of fistula failure, 10 cases (28.5%) showed early fistula failure (<1 month), and no complications related to using a Fogarty catheter occurred.

Table 2. Causes of fistula failure

Cause	Total	Group A	Group B	p-value
Thrombotic occlusion	28 (79)	17 (85)	11 (72)	0.99
Venous hypertension	3 (9)	0	3 (21)	0.08
Poor function	2 (6)	2 (10)	0	0.16
Recurrent cellulitis	1 (3)	0	1 (7)	0.32
Cephalic vein stenosis	1 (3)	1 (5)	0	0.32
Total	35 (100)	20 (100)	14 (100)	

Values are presented as number (%).

DISCUSSION

The National Kidney Foundation’s Kidney Disease Outcomes Quality Initiative and the FistulaFirst initiative have emphasized the importance of dialysis using native AVFs. In October 1997, the National Kidney Foundation’s Kidney Disease Outcomes Quality Initiative clinical practice guidelines for vascular access were published, dealing with AVF placement techniques and prolonging the use of existing accesses. These guidelines recommended that when possible, autogenous AV accesses should be considered before the placement of prosthetic arteriovenous accesses [1,2]. Vascular access is achieved by an AVF, patients requiring fewer procedures, suffer fewer complications, have better survival rates and pay lower costs during renal replacement therapy [1,4]. Although autogenous AVFs are considered the gold standard, it has been reported that one-year patency rates may vary from 36% to 62.5% [4,6-10]. Moreover, using smaller veins for AVFs has been shown to result in an increased number of fistula revisions and an increased rate of fistula failure [5]. Moreover, Dageforde et al. [11] have reported that AVFs created in veins with smaller minimal vein diameters have worse secondary patency. In their study, the 24-month patency rate in veins <0.28 mm in diameter was found to be only 32% (p=0.018).

De Marco Garcia et al. and Veroux et al. [3,5] reported that primary balloon angioplasty and balloon-assisted angioplasty are successful methods for increasing the patency and maturation rate in suboptimal veins (≤2 mm in diameter) used for AVF creation. De Marco Garcia et al. [5] reported that the process of focal angioplasty injury to the venous endothelium, along with the subsequent healing process seen af-

ter primary balloon angioplasty and balloon-assisted maturation, helps the venous wall reorganize into a fibrous conduit. Veroux et al. [3] reported that they performed ballooning of the longer segment of the cephalic vein from the wrist to the elbow before AVF creation. This resulted in a well-functioning AVF even in patients with a very small cephalic vein (≤ 2 mm in diameter). Moreover, the use of this technique allowed them to achieve a low-resistance venous outflow, which was associated with excellent six-month primary patency and working AVF rates (95% and 100%, respectively). They also reported that dilatation of the longer segment of the cephalic vein at the time of AVF creation is highly effective, avoiding the need for multiple late percutaneous transluminal angioplasties. The key factor affecting the patency of the AVF was high-resistance venous outflow.

In addition, Lee et al. [12] reported that in case of the adequate blood flow was established with the RCAVF, hemodynamic factors played an important role in vein wall remodeling on the dialysis site [12]. Therefore, they presented the hypothesis that the hemodynamic conditions in the draining vein could be affected in stenosed or occluded upper arm cephalic vein of RCAVF. They reported that in case of the draining venous flow was not sufficient, maturation failure developed more frequently, the rates of both primary patency and secondary patency were significantly poor, more endovascular interventions were needed [12].

Primary balloon angioplasty and balloon-assisted maturation show good results, but these procedures require a long skin incision, a hybrid procedure, heparin injection for balloon dilatation, the use of contrast enhancers, and radiation exposure. However, intraoperative balloon angioplasty with a Fogarty catheter allows the creation of AVF with suboptimal veins or despite insufficient runoff in the cephalic vein, and increases the patency and functional maturation of AVF without requiring additional procedures. In this study, the seven-year AVF patency rate in patients who underwent angioplasty using a Fogarty catheter because of an insufficient cephalic vein was somewhat better ($76.3\% \pm 4.9\%$) than the rates reported in other studies [9,10,13,14]. Our results appear comparable to patency rates in patients with sufficient cephalic veins who did not undergo angioplasty ($p=0.356$).

We suggest that our procedure has the effect of reducing

the flow resistance and widening the stenosis in the more proximal vein by balloon dilatation. The strength of our technique is that it is easily reproducible, inexpensive, and avoids the need for multiple angiograms and a long skin incision.

A significant difference was found between the two groups regarding the number of upper arm AVFs. According to extant guidelines, if the cephalic vein is sufficient to create an AVF, the surgeon should consider creating a forearm AVF [1]. Otherwise, the surgeon could consider creating an upper arm AVF. Hence, the creation of upper arm AVFs was more likely in patients with an insufficient cephalic vein. Therefore, we performed angioplasty using a Fogarty catheter more frequently when creating upper arm AVFs than when creating forearm AVFs, which explains why upper arm AVFs were more common in group A.

However, we acknowledge that our study has a number of limitations. This study was a retrospective review based on available patient information, and the results were dependent on the availability and accuracy of the information. Our records show the occurrence of limited and inadequate follow-up in patients who needed permanent dialysis access. Our sample size was limited, since only patients with adequate follow-up were included in the analysis. We propose that a prospective randomized control study is needed to confirm the efficacy of our procedure.

In conclusion, intraoperative balloon angioplasty of the cephalic vein using a Fogarty catheter is a simple and easily reproducible procedure, which can be helpful in increasing the patency of AVFs in cases of insufficient runoff or a suboptimal cephalic vein. This procedure has additional advantages, such as not requiring the use of nephrotoxic contrast enhancers, exposure to radiation, or a long skin incision. However, the efficacy of this procedure should be confirmed by performing further studies.

CONFLICT OF INTEREST

No potential conflict of interest relevant to this article was reported.

ACKNOWLEDGMENTS

This study was supported by a Grant of the Samsung Vein Clinic Network (Daejeon, Anyang, Cheongju, Cheonan; Fund No. KTCS04-023).

REFERENCES

1. Sidawy AN, Spergel LM, Besarab A, et al. *The Society for Vascular Surgery: clinical practice guidelines for the surgical placement and maintenance of arteriovenous hemodialysis access*. J Vasc Surg 2008;48(5 Suppl):2S-25S.
2. National Kidney Foundation. *Guidelines and commentaries* [Internet]. New York (NY): National Kidney Foundation [cited 2011 Dec 9]. Available from: <http://www.kidney.org/professionals/KDOQI/guidelines.cfm>.
3. Veroux P, Giaquinta A, Tallarita T, et al. *Primary balloon angioplasty of small (≤ 2 mm) cephalic veins improves primary patency of arteriovenous fistulae and decreases re-intervention rates*. J Vasc Surg 2013;57:131-6.
4. Jennings WC, Kindred MG, Broughan TA. *Creating radio-cephalic arteriovenous fistulas: technical and functional success*. J Am Coll Surg 2009;208:419-25.
5. De Marco Garcia LP, Davila-Santini LR, Feng Q, Calderin J, Krishnasastri KV, Panetta TF. *Primary balloon angioplasty plus balloon angioplasty maturation to upgrade small-caliber veins (< 3 mm) for arteriovenous fistulas*. J Vasc Surg 2010;52:139-44.
6. Lauvao LS, Ihnat DM, Goshima KR, Chavez L, Gruessner AC, Mills JL Sr. *Vein diameter is the major predictor of fistula maturation*. J Vasc Surg 2009;49:1499-504.
7. Lazarides MK, Georgiadis GS, Antoniou GA, Stamos DN. *A meta-analysis of dialysis access outcome in elderly patients*. J Vasc Surg 2007;45:420-426.
8. Renaud CJ, Pei JH, Lee EJ, Robless PA, Vathsala A. *Comparative outcomes of primary autogenous fistulas in elderly, multiethnic Asian hemodialysis patients*. J Vasc Surg 2012;56:433-9.
9. Ravani P, Palmer SC, Oliver MJ, et al. *Associations between hemodialysis access type and clinical outcomes: a systematic review*. J Am Soc Nephrol 2013;24:465-73.
10. Zhang JC, Al-Jaishi AA, Na Y, de Sa E, Moist LM. *Association between vascular access type and patient mortality among elderly patients on hemodialysis in Canada*. Hemodial Int 2014;18:616-24.
11. Dageforde LA, Harms K, Feurer ID, Wright A, Shaffer D. *Pre-operative vein mapping predicts failure of arteriovenous fistula maturation and long-term patency*. J Am Coll Surg 2013;217:S157.
12. Lee JH, Won JH, Oh CK, Jung HA. *Clinical significance of upper-arm cephalic vein patency in autogenous radial-cephalic wrist fistulas for hemodialysis*. Eur J Vasc Endovasc Surg 2012;44:514-20.
13. Huijbregts HJ, Bots ML, Wittens CH, et al. *Hemodialysis arteriovenous fistula patency revisited: results of a prospective, multicenter initiative*. Clin J Am Soc Nephrol 2008;3:714-9.
14. Kotoda A, Akimoto T, Sugase T, Miyamoto N, Kusano E. *Balloon-assisted creation and maturation of an arteriovenous fistula in a patient with small-caliber vasculature*. Case Rep Nephrol Urol 2012;2:65-71.