

직장을 통해 들어간 대장과 직장의 이물: 증례보고

단국대학교병원 외과 권역 외상센터

김형란, 최석호, 윤정석

- Abstract -

Colorectal Foreign Bodies: Six Cases Report and Review of the Literature

Hyoungnan Kim, M.D., Seokho Choi, M.D., Jeongseok Yun, M.D.

Trauma Center, Departments of General Surgery, Dankook University Hospital, Cheonan, Korea

The incidence of foreign body insertion in the anorectum is rare, however, it is increasing, especially in urban populations. Foreign objects in the anorectum can be of different sizes, shapes and materials. Frangible objects like glass or beakers, and sharp foreign bodies that may easily injure the bowel mucosa are particularly dangerous. Physicians have to consider more innovative options on how to extract these foreign bodies without inciting injury; and, if injury would occur, consider different techniques to repair it, whether transanally or transabdominally, and opt for primary repair, or resection with either anastomosis or stoma creation. Here, I introduce our cases with colorectal foreign bodies and present several literatures to help physicians decide when presented with cases like these. [J Trauma Inj 2015; 28: 51-54]

Key Words: Anorectum, Foreign body, Extract

I. Introduction

Regardless of the gender of the patient, whether they insert foreign bodies through their anus for autoeroticism, voluntarily or accidentally, or whether the patient had the past history of psychiatric disorders, the removal of foreign body in the anorectum is for the physician, challenging, interesting and embarrassing in the same time. Since

there was the first report in 16th century,(1) the incidence of foreign body insertion in anorectum is still rare, but it appears increasing, especially, in urban populations.(2,3) The various reasons of inserting the foreign body in rectum are anal autoeroticism, concealment, attention seeking behavior, accident, assault and to alleviate constipation.(4) Foreign body in rectum is known for potential complications and we need to approach more organized-

* Address for Correspondence : **Jeong seok Yun, M.D.**

Trauma Center, Department of Surgery, Dankook University Hospital,
201 Manghyang-ro, Dongnam-gu, Cheonan-si, 330-715, Chungnam, Korea
Tel : 82-41-550-7666, Fax : 82-41-550-0039, E-mail : dutheji77@naver.com

Submitted : March 6, 2015 **Revised** : March 19, 2015 **Accepted** : March 19, 2015

ly. Here, I report 6 cases with colorectal foreign bodies and review several literatures.

II. Case

Between January 2005 and January 2015, 6 of total trauma patients 40034 (incidence: 0.015%) were treated for foreign bodies in the colorectum. All of them were male, the range of ages was 14~49 years old and mean age was 39. Three patients had rectal foreign bodies, two patients had foreign bodies in anus and one inserted a spray cap in his sigmoid colon through the anus. Two of three patients with

rectal foreign bodies for their curiosity went to see the physician two days later. Only one patient had the past history of a psychiatric disorder – attention deficit hyperactivity disorder (ADHD). In all six patients, a 14-years-old boy with ADHD history and a 45-years-old man had the flash light and the metallic ring (Fig. 1) in their rectum accidentally when they were slipping. The remnant patients inserted various things (laboratory beaker (Fig. 2), sausage (25×5 cm), spray cap, and sexual toy glass (12×3 cm) (Fig. 3, 4) by-themselves. We summarized age, location, days of hospital stay, and anesthesia methods in Table 1 and presented several radiologic images in Fig. 1 to Fig. 4.

All foreign bodies were extracted from the patients under anesthetics: spinal (2 patients), general (2 patients) and from spinal to general (2 patients). The endoscopist pulled out the foreign body in three cases. Two patients had their operative position changed from Jack-Knife position to lithotomy. The 45-year-old male patient with the 12×3 cm sized sexual toy glass in his rectum had two operations. At first, we did not extract the foreign body under the 1st spinal anesthesia cooperating with the endoscopist in lithotomy position. We performed 2nd operation two days later under the general anesthesia with the endoscopist's help to pull the foreign object more distal so we could reach it and removed

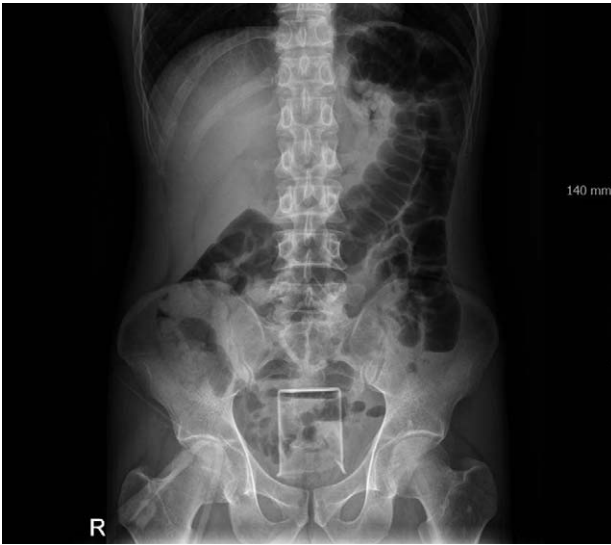

Fig. 1. Pelvic X-ray, metal ring in pelvis.

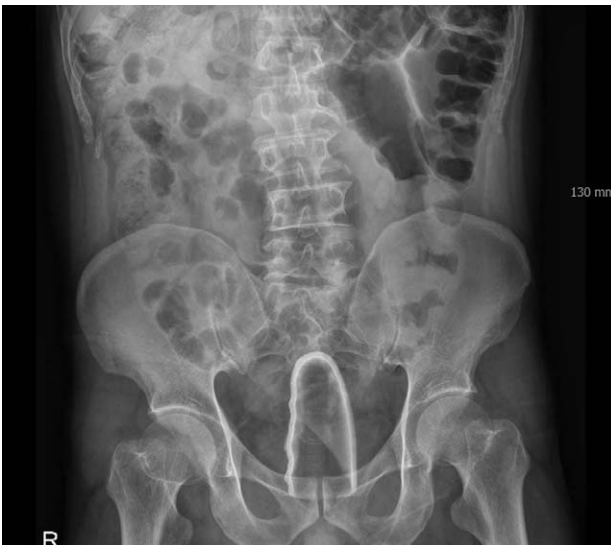

Fig. 2. Pelvic X-ray, laboratory beaker in pelvis.

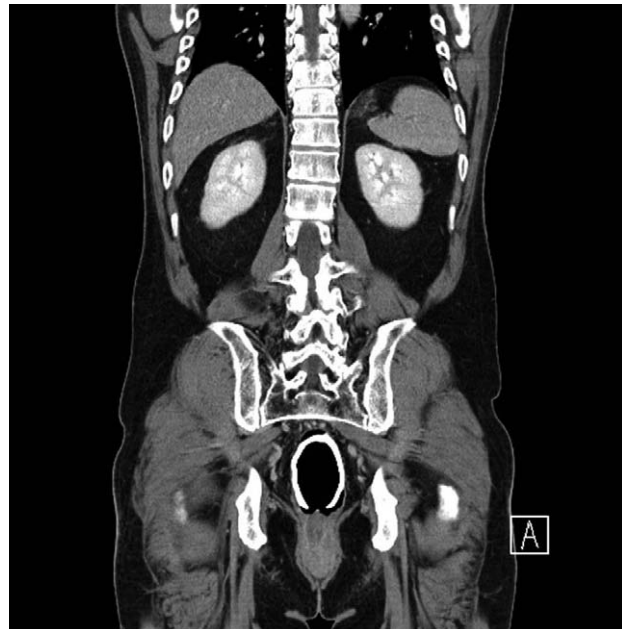


Fig. 3. Pelvic X-ray, sexual toy glass in pelvis.

the foreign body transanally in the same position. The other 45-year-old man with the metallic ring in his rectum (Fig. 3) was cut by metal cutter and removed transanally, but in the next day he had to have the conversion primary repair for his perforated rectum.

All patients stayed in the hospital for mean 6.3 days (range: 2~12 days). There were no postoperative complications. Three of 6 patients visited the outpatient clinic at just one time, and none of them had a consultation with the psychiatrist.

III. Discussion

When you meet the patient with rectal foreign

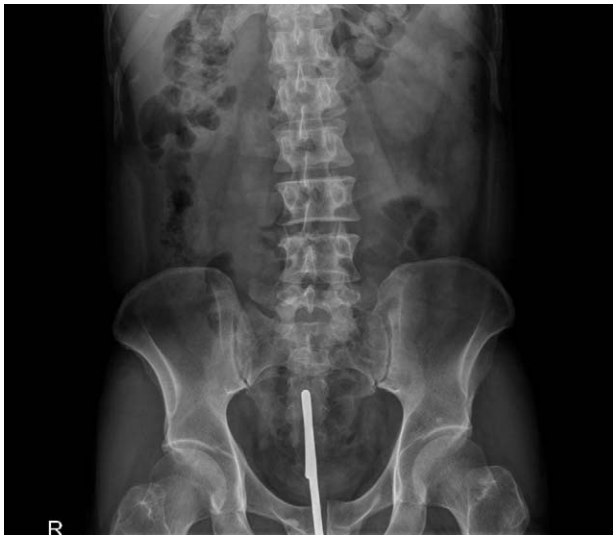

Fig. 4. Abdominopelvic CT, sexual toy glass in rectum.

body, at first you may think that because the foreign body was inserted via the anus, it could be likely extracted through the anus. Actually, several studies(5,6) reported that majority (90%) of the cases is treated by transanal retrieval and routine laboratory investigation and abdominal images are unnecessary.(8) Our cases also were removed through the anus and two patients of them were performed primary repairs via transanally in one, and transabdominally in the other. Here you need to consider the suction effect of the colon. It means that an attempt to pull out the ball-like foreign bodies – for examples, ink bottle, wooden rod et al. – was met with a strong counter suction force. As far back as 1934, Pretty demonstrated the effect of the colon as a vacuum.(7) There are several useful tips to extract foreign bodies via the anus in safely and successfully. The first tip is for shallowly inserted objects: if our fingers or clamps can reach the foreign body. For that we can use the colonoscopy or sigmoidoscopy, and ballooned catheter. In addition, Nivatvongs et al. recommended simply placing a Foley catheter or nasogastric tube into rectum or the sigmoid colon is not enough, and actively injecting a sufficient amount of air during extraction of foreign bodies.(9) It may be useful to apply the pressure of suprapubic or sigmoid by an assistant to push down or prevent the cephalad migration, but if it is a sharp object you need to use endoscopic techniques or other ways.(8) Recently, several studies(9, 10) already reported the use of a laparoscope to help push down the foreign body into the low rectum

Table 1. Patients’ characteristics.

No	Age	Types of foreign bodies	HD* (Days)	Location of foreign bodies	Anesthesia	Treatments
1	14	Flash light	2	Anus	SPI [§]	Transanal extraction
2	37	Laboratory beaker	12	Rectum (AV5~6 cm)	SPI	Transanal extraction & Transanal Primary Repair
3	41	Sausage (25 × 5 cm)	3	Anus	G [¶]	Transanal extraction
4	45	Metal ring	12	Rectum (AV15 cm)	G	Transanal extraction & Transabdominal Primary Repair
5	48	Spray cap	3	Sigmoid colon	SPI->G	Transanal extraction
6	49	Sexual toy glass (12 × 3 cm)			SPI (1 st Op.) G (2 nd Op.)	Transanal extraction

* HD: Days of hospital stay

§ SPI: Spinal anesthesia

¶ G: General anesthesia

where the location our fingers or jaws of the retrieving forceps can reach the foreign body. The second tip is to make a more relaxed anal sphincter by putting the patient under the local, spinal or general anesthesia. The third is the lithotomy position to break the suction effect.(9)

Foreign objects in the rectum can be different sizes and shapes, and often glass-made, so they are breakable, fragile and sharp enough to injure the rectal mucosa. We must handle these cases as complicated and make systemic approaches and treatments.(2) After the extraction of the rectal foreign body, we must be concerned important two points. First, patients are observed for several hours and performed proctosigmoidoscopic examination that most authors recommended as a mean of visually assessing to evaluate the injury of rectal mucosal injury(2) even though Lake et al. described this endoscopic examination in only less than half of cases and only 16% of these had any mucosal abnormality without perforation.(3) Second is about the function of the anal sphincter. If you have patients with any findings of sphincter dysfunction, you need to wait, observe and follow-up at least 3 months before considering any sphincter repair.(1,11) Because many of them will improve.

As I said, because foreign bodies insertion in rectum occurred commonly in male for sexual gratification, patients and physicians could be likely to avoid that problems in formal and in flank. But, physicians should have an active attitude to the treatment of psychiatric and forensic reviews.(12,13) We also reviewed our passive attitude to our patients that were not asked to see the psychiatrist. This article gives a chance for us to change our

minds and policies more psychologically to treat patients with colorectal foreign bodies.

REFERENCES

- 1) Kasotakis G, Roediger L, Mittal S. Rectal foreign bodies: A case report and review of the literature. *Int J Surg Case Rep* 2012; 3: 111-5.
- 2) Goldberg JE, Steele SR. Rectal foreign bodies. *Surg Clin North Am* 2010; 90: 173-84.
- 3) Lake JP, Essani R, Petrone P, Kaiser AM, Asensio J, Beart RW Jr. Management of retained colorectal foreign bodies: predictors of operative intervention. *Dis Colon Rectum* 2004; 47: 1694-8.
- 4) Clarke DL, Buccimazza I, Anderson FA, Thomson SR. Colorectal foreign bodies. *Colorectal Dis* 2005; 7: 98-103.
- 5) Biriukov InV, Volkov OV, An VK, Borisov Elu, Dodina AN. Treatment of patients with foreign body in rectum. *Khirurgiia (Mosk)* 2000; 7: 41-3.
- 6) Subbotin VM, Davidov MI, Faïnshteïn AV, Abdrashitov RR, Rylov IuL, Sholin NV. Foreign bodies of the rectum. *Vestn Khir Im I I Grek* 2000; 159: 91-5.
- 7) Pretty HG. An ink bottle in the rectum. *Can Med Assoc J* 1934; 31: 302-3.
- 8) Cologne KG, Ault GT. Rectal foreign bodies: What is the current standard? *Clin Colon Rectal Surg* 2012; 25: 214-8.
- 9) Nivatvongs S, Metcalf DR, Sawyer MD. A simple technique to remove a large object from the rectum. *J Am Coll Surg* 2006; 203: 132-3.
- 10) Durai R, Biradhar, D, Nq PC. Two port laparoscopic-assisted removal of a migrating rectal foreign body. *Tech Coloproctol* 2010; 14: 263-4.
- 11) Kurer MA, Davey C, Khan S, Chinatapatla S. Colorectal foreign bodies; a systematic review. *Colorectal Dis* 2010; 12: 851-61.
- 12) Atila K, Sökmen S, Astarcioglu H, Canda E. Rectal foreign bodies: a report of four cases. *Ulus Travma Acil Cerrahi Derg* 2004; 10: 253-6.
- 13) Danielson CK, Holmes MM. Adolescent sexual assault; an update of the literature. *Curr Opin Obstet Gynecol* 2004; 16: 383-8.