

## Anticoagulant Therapy-Induced Gallbladder Hemorrhage after Cardiac Valve Replacement

Seong Ho Cho, M.D., Hae Young Lee, M.D., Hyun Su Kim, M.D.

Anticoagulation therapy is essential after cardiac valve surgery. However, spontaneous bleeding remains a major concern during anticoagulation therapy. Spontaneous gallbladder (GB) hemorrhage (hemobilia) is a rare occurrence during standard anticoagulation therapy. This report presents a case of GB hemorrhage that occurred shortly after initiating oral anticoagulant therapy in a patient who had undergone mitral valve replacement surgery.

Key words: 1. Anticoagulants  
2. Hemobilia

### CASE REPORT

A 61-year-old male was admitted to the hospital with symptoms of progressive dyspnea and dizziness. He had a history of hypertension, diabetes mellitus, and angina. He had undergone right coronary artery stent insertion approximately six months previously. After his admission, he was diagnosed with atrial fibrillation and severe mitral regurgitation. Coronary angiography revealed a coronary artery fistula from the proximal left anterior descending coronary artery to the main pulmonary artery. The patient underwent mitral valve replacement, the Cox-Maze III procedure, and external ligation of the coronary fistula. On the first postoperative day, the patient began taking aspirin and clopidogrel. On the second postoperative day, he received 2 mg of warfarin as a starting dose. He was also injected with enoxaparin subcutaneously together with warfarin until his prothrombin time (PT)/international normalized ratio (INR) remained above 1.5 for a prolonged period. He had mild hyperbilirubinemia (total bilirubin level, 2.66 mg/dL) in the immediate postoperative period, his total

bilirubin level gradually decreased, reaching a normal level on the fifth day after the operation.

On the eighth day after the operation, the patient complained of postprandial epigastric pain. His physical examination was significant for cold sweating with a body temperature of 37.6°C, hypoactive bowel sounds, and epigastric tenderness. However, Murphy's sign and digital rectal examination were negative. The significant laboratory findings were a hemoglobin level of 8.8 g/dL, thrombocytopenia with a platelet count of 74,000/mm<sup>3</sup>, mild PT prolongation (INR, 1.59), and mild hyperbilirubinemia with a total bilirubin level of 2.64 mg/dL and a direct fraction of 2.20 mg/dL. Other laboratory results were within normal limits, including hepatitis B and C viral markers as well as all indicators of underlying hepatobiliary diseases, such as previous gallbladder stones or liver cirrhosis. Abdominal computed tomography imaging was performed, and contrast-enhanced scans showed a distended gallbladder with high-intensity sludge-like matter in the lumen (Fig. 1). These findings were thought to represent gallbladder hemorrhage (hemobilia). As soon as this diagnosis was made,

Department of Thoracic and Cardiovascular Surgery, Kosin University Gospel Hospital

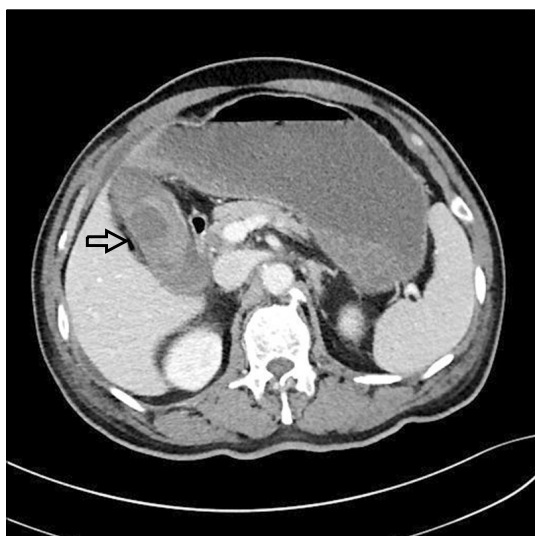
Received: June 16, 2015, Revised: August 5, 2015, Accepted: August 5, 2015, Published online: December 5, 2015

Corresponding author: Seong Ho Cho, Department of Thoracic and Cardiovascular Surgery, Kosin University Gospel Hospital, 262 Gamcheon-ro, Seo-gu, Busan 49267, Korea

(Tel) 82-51-990-6466 (Fax) 82-51-990-3066 (E-mail) [aorta007@naver.com](mailto:aorta007@naver.com)

© The Korean Society for Thoracic and Cardiovascular Surgery. 2015. All right reserved.

© This is an open access article distributed under the terms of the Creative Commons Attribution Non-Commercial License (<http://creativecommons.org/licenses/by-nc/4.0>) which permits unrestricted non-commercial use, distribution, and reproduction in any medium, provided the original work is properly cited.

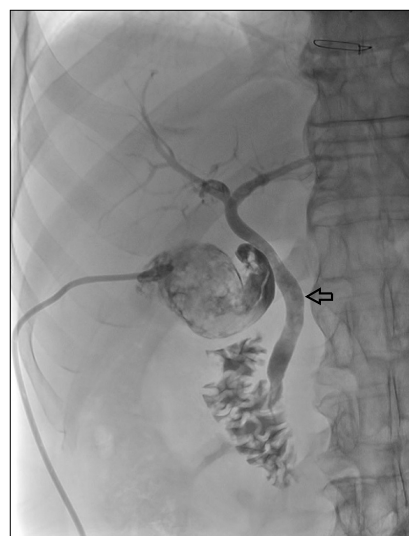

**Fig. 1.** Abdominal computed tomography. A contrast-enhanced computed tomography scan through the gallbladder shows streaks of contrast escaping into the gallbladder lumen and hyperdense contents within the gallbladder (arrow).

anticoagulant medication was stopped, parenteral nutrition was initiated, and the patient was transferred to the hepatobiliary department in order to perform percutaneous transhepatic gallbladder drainage (PTGBD). Endoscopic retrograde cholangiography was performed and a drain was inserted three days after PTGBD. The endoscopy findings included hematoma and acute cholangitis (Fig. 2). After ten days of PTGBD and monitoring the color of the drainage, the drain output turned clear. On the same day, a repeat cholangiogram showed no evidence of ongoing bleeding, and most of the hematoma had resolved. During these ten days, the patient underwent anticoagulation with enoxaparin (200 mg of Clexane twice a day). Upon the resolution of hemobilia, he restarted warfarin and was discharged after the PTGBD was removed on postoperative day 28.

## DISCUSSION

Hemobilia is a hemorrhage into the biliary tract [1]. The term hemobilia was coined by Sandblom in 1948 to describe hemorrhage into the biliary tract as a result of a communication or fistula between the biliary tract and the arteriovenous circulation [2]. Hemobilia is not a common complication, but



**Fig. 2.** Endoscopic retrograde cholangiographic findings of hemobilia. The common bile duct is dilated and a filling defect is present (arrow) when contrast media is injected through the percutaneous transhepatic gallbladder drainage tube, suggesting a blood clot in the bile duct.

urgent management is required to avoid complications such as GB perforation. Several factors may cause GB hemorrhages, including biliary obstruction, acute and chronic cholecystitis, neoplasm, coagulopathy, and iatrogenic injury [3]. Recently, the most common cause of hemobilia has been reported to be trauma, with iatrogenic causes being the most important [4]. The clinical manifestations of hemobilia, known as Quincke's triad, consist of right upper quadrant abdominal pain, jaundice, and upper gastrointestinal tract hemorrhage [5]. The etiology of the hemorrhage is thought to involve chronic inflammation of the gallbladder lumen. Pathologic findings can include transmural inflammation of the GB wall, which can lead to infarction and erosion of the mucosa, in turn causing hemorrhage into the gallbladder lumen [6]. While this patient was receiving anticoagulant therapy, bleeding from the lesion caused bile duct obstruction due to hemobilia. Computed tomography scans may assist in the diagnosis of hemobilia, which has a characteristic finding of high attenuation within the gallbladder lumen with a layered fluid level presenting as blood or sludge [7]. Ultrasonography can be also a useful diagnostic tool, especially for patients with severe renal failure.

Warfarin therapy increases the risk of major bleeding by 0.3%–0.5% per year [8]. Warfarin interferes with the hepatic synthesis of vitamin K-dependent clotting factors II, VII, IX, and X, resulting in their eventual depletion and prolongation of the clotting time, as measured by the PT and INR [9]. Triple antithrombotic therapy is indicated for atrial fibrillation patients undergoing stent insertion who are at a high risk for stroke (CHADS<sub>2</sub> risk score >1), but not for bleeding [10]. Since this patient's CHADS<sub>2</sub> risk score was 2 and he did not have an elevated risk of bleeding, we considered triple antithrombotic therapy. In patients who undergo mitral valve replacement, we maintain the PT-INR in the range of 1.8–2.2 depending on the presence of atrial fibrillation. In the present case, we decided to maintain the INR level in the range of 1.6–1.8 because the patient received triple antithrombotic therapy for the intracoronary stent. Concomitant anticoagulant therapy increases the chances of hemorrhage. Bleeding from the gallbladder while the patient was receiving anticoagulant therapy caused the bile duct obstruction, resulting in cholangitis and sepsis. Therefore, GB hemorrhage, or hemobilia, should be considered in the differential diagnosis of all patients on anticoagulation therapy who present acutely with similar signs and symptoms. The main treatment of hemobilia is directed at hemostasis and restoring the bile flow. When bile flow is interrupted, the clot does not dissolve and remains in the bile duct due to disturbance of the fibrinolytic action of the bile [7]. Although minor cases of hemobilia can be managed with correction of the coagulopathy and hydration, hemobilia usually requires endoscopic therapy, radiologic intervention, or surgery. Endoscopic retrograde cholangiography played a useful role in the management of hemobilia in this patient by removing the blood clot and sludge from the bile duct.

In conclusion, for patients taking anticoagulant medications after cardiac surgery who show signs of anemia and acute abdominal pain (especially in the right upper quadrant), he-

mobilia should be considered in the differential diagnosis, as this acute condition requires immediate additional evaluation and proper management.

## CONFLICT OF INTEREST

No potential conflict of interest relevant to this article was reported.

## REFERENCES

1. Hong JW, Han YS, Lee JH, et al. *A case of non-traumatic hemobilia due to warfarin therapy*. Korean J Gastroenterol 2004;44:292-5.
2. Sandblom P. *Hemorrhage into the biliary tract following trauma; traumatic hemobilia*. Surgery 1948;24:571-86.
3. Pollack BJ, Chak A, Dahman B, Sivak MV Jr. *Warfarin therapy complicated by recurrent hemobilia in a patient with sarcoidosis*. Gastrointest Endosc 1997;46:72-6.
4. Shoeb M, Fang MC. *Assessing bleeding risk in patients taking anticoagulants*. J Thromb Thrombolysis 2013;35:312-9.
5. Hahn YS, Lee HK. *Traumatic hemobilia following blunt chest trauma*. Korean J Thoracic Cardiovasc Surg 1976;9: 117-24.
6. Ehrman JK, Gordon PM, Visich PS, Keteyian SJ. *Clinical exercise physiology*. 3rd ed. Champaign (IL): Human Kinetics; 2013.
7. Kim KH, Kim TN. *Etiology, clinical features, and endoscopic management of hemobilia: a retrospective analysis of 37 cases*. Korean J Gastroenterol 2012;59:296-302.
8. Hart RG, Pearce LA, Aguilar MI. *Adjusted-dose warfarin versus aspirin for preventing stroke in patients with atrial fibrillation*. Ann Intern Med 2007;147:590-2.
9. Wittkowsky AK. *Warfarin*. In: Murphy JE; American Society of Health-System Pharmacists, et al. *Clinical pharmacokinetics*. 5th ed. Bethesda (MD): American Society of Health-System Pharmacists Inc.; 2012. p. 351-72.
10. Paikin JS, Wright DS, Crowther MA, Mehta SR, Eikelboom JW. *Triple antithrombotic therapy in patients with atrial fibrillation and coronary artery stents*. Circulation 2010;121: 2067-70.