

# Miniscrews versus surgical archwires for intermaxillary fixation in adults after orthognathic surgery

Sieun Son<sup>a</sup>  
Seong Sik Kim<sup>a</sup>  
Woo-Sung Son<sup>a</sup>  
Yong-Il Kim<sup>a</sup>  
Yong-Deok Kim<sup>b</sup>  
Sang-Hun Shin<sup>b</sup>

<sup>a</sup>Department of Orthodontics, Pusan National University Dental Hospital, School of Dentistry, Pusan National University, Yangsan, Korea

<sup>b</sup>Department of Oral and Maxillofacial Surgery, Pusan National University Dental Hospital, School of Dentistry, Pusan National University, Yangsan, Korea

**Objective:** We compared the skeletal and dental changes that resulted from the use of two methods of intermaxillary fixation (IMF)—miniscrews and surgical archwire—in 74 adult patients who had Class III malocclusion and were treated with the same orthognathic surgical procedure at a hospital in Korea. **Methods:** All the patients underwent Le Fort I osteotomy and bilateral sagittal split ramus osteotomy with rigid fixation. They were divided into two groups according to the type of IMF used—group 1 underwent surgical archwire fixation and group 2 underwent orthodontic miniscrew fixation. In a series of cephalograms for each patient, we compared vertical and horizontal tooth-position measurements: (a) immediately after surgery ( $T_0$ ), (b) 3 months after surgery ( $T_1$ ), and (c) 6 months after surgery ( $T_2$ ). Cephalometric changes within each group were examined using one-way analysis of variance (ANOVA) while the independent samples *t*-test procedure was used to compare the two groups. **Results:** After surgery, the maxillary incisors tended to be proclined in both groups although there were no significant differences. Incisor overbite increased significantly in both groups from  $T_0$  to  $T_1$ , and the miniscrew group (group 2) showed slightly greater overbite than the archwire group (group 1). **Conclusions:** This study suggest that the use of orthodontic miniscrews and orthodontic surgical archwire for IMF in adult patients results in similar skeletal and dental changes. [Korean J Orthod 2015;45(1):3-12]

**Key words:** Microimplant, Surgery, Cephalometrics

Received March 26, 2014; Revised June 5, 2014; Accepted July 21, 2014.

**Corresponding author:** Seong Sik Kim.  
Professor, Department of Orthodontics, Pusan National University Dental Hospital, 20 Geumo-ro, Mulgeum-eup, Yangsan 626-787, Korea  
**Tel** +82-55-360-5162 **e-mail** softid@pusan.ac.kr

\*This study was supported by Clinical Research Grant, Pusan National University Dental Hospital (2012).

The authors report no commercial, proprietary, or financial interest in the products or companies described in this article.

© 2015 The Korean Association of Orthodontists.

This is an Open Access article distributed under the terms of the Creative Commons Attribution Non-Commercial License (<http://creativecommons.org/licenses/by-nc/3.0>) which permits unrestricted non-commercial use, distribution, and reproduction in any medium, provided the original work is properly cited.

**INTRODUCTION**

Orthodontic correction of skeletal Class III malocclusion is a particularly challenging aspect of orthodontics. For severe skeletal Class III deformities, surgical orthodontic treatment (orthognathic surgery) is one of the best options. The most important step in managing the maxillofacial trauma that follows orthognathic surgery is intermaxillary fixation (IMF). IMF helps maintain newly created maxillomandibular relations and prevents skeletal relapse during the bone healing process.

Traditionally, IMF has been achieved by means of arch bars or interdental eyelet wiring. These techniques have intrinsic disadvantages; for example, they are time-consuming and pose a risk of needle injury to the surgeon.<sup>1</sup> For these reasons, orthodontic surgical wire with hooks have been used for IMF and traction since some time. However, in orthognathic surgery cases with large setback movement or major counterclockwise rotation of the mandible, surgical wire fixation can lead to a significant extrusive load on the anterior teeth. This vertical force persists until muscle function adapts to the postoperative mandibular morphology and occlusion.<sup>2</sup> To reduce the extrusive load on anterior teeth during IMF, Thota and Mitchell<sup>3</sup> employed miniscrew fixation in the anterior region of the jaw.

Initially, bone-anchored screws were introduced as a means of bone fracture fixation.<sup>4</sup> Currently, intraoral miniscrews are often used as a mandibular-fracture treatment alternative to arch bars during IMF.<sup>1,5,6</sup> Miniscrews are also used for skeletal anchorage during orthodontic tooth movement.<sup>7-9</sup> Ueki et al.<sup>10</sup> reported significant differences in occlusal plane and convexity changes in groups with and without miniscrews for IMF. However, there have been no reports on tooth movement in relation to the use of miniscrews for IMF after orthognathic surgery.

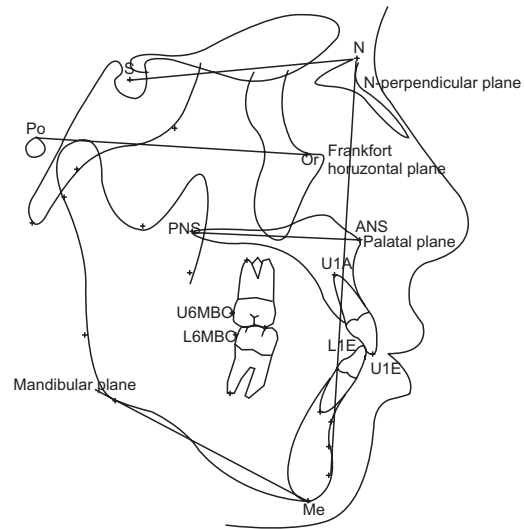
The purpose of the present study was (1) to investigate the skeletal and dental changes that occurred during postoperative orthodontic treatment involving the use

of miniscrews for IMF and (2) to compare the use of miniscrew fixation and surgical archwire fixation for IMF in adult patients who had Class III malocclusion and had undergone maxillomandibular surgery.

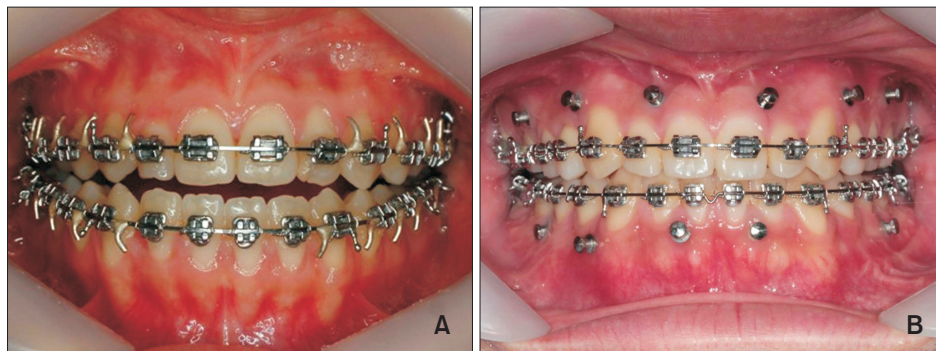
**MATERIALS AND METHODS**

**Subjects**

This retrospective study included patients who underwent orthognathic surgery and post-surgical orthodontic treatment between January 2012 and January 2013



**Figure 2.** Landmarks and reference planes. S, Sella; N, Nasion; Po, Porion; Or, Orbitale; ANS, anterior nasal spine; PNS, posterior nasal spine; Me, Menton; U1E, incisal edge of maxillary central incisor (U1); U1A, root apex of U1; L1E, incisal edge of mandibular incisor (L1), L1A: root apex of L1; U6MBC, mesiobuccal cusp tip (MBC) of maxillary first molar; L6MBC, MBC of mandibular first molar; Frankfort horizontal plane (FH plane), line from Po to Or; N-perpendicular plane (N-perpend plane), perpendicular line to FH plane passing through Nasion.



**Figure 1.** Intermaxillary fixation types. (A) Surgical archwire fixation and (B) Orthodontic miniscrew fixation.

at the Department of Oral and Maxillofacial Surgery, Pusan National University Dental Hospital. The patients consisted of 74 adults (39 male and 35 female patients; mean age,  $21.7 \pm 3.3$  years) who had been diagnosed with skeletal Class III malocclusion and who subsequently underwent 2-jaw surgery (LeFort I osteotomy, bilateral sagittal split ramus osteotomy with rigid fixation). The patients were divided into two groups according to fixation type (Figure 1): conventional fixation using surgical archwires with hooks (group 1: wire fixation group, 20 male and 17 female patients; mean age,  $21.6 \pm 3.0$  years) and miniscrew fixation using orthodontic miniscrews (group 2: screw fixation group, 19 male and 18 female patients; mean age,  $22.0 \pm 3.6$  years). The inclusion criteria were as follows: healthy physical condition, lack of severe facial asymmetry ( $\leq 3$  mm of Menton deviation from facial midline), no temporomandibular dysfunction symptoms or degenerative joint disease on examination, and skeletal Class III deformities. All the patients had undergone pre-surgical orthodontic treatment and now

had well-aligned arches.

The orthodontic treatment entailed the use of a 022-slot preadjusted appliance: 0.019 × 0.025 stainless steel wire in group 1 and rigid rectangular stainless steel wire (minimum 0.017 × 0.025) in group 2. After 6 weeks, postoperative orthodontic treatment was resumed, according to protocols applied equally to both groups. This study was reviewed and approved by the Ethics Committee of Pusan National University Dental Hospital (PNUDH-2013-024).

**Data acquisition**

Lateral cephalograms were obtained immediately after surgery ( $T_0$ ), 3 months after surgery ( $T_1$ ), and 6 months after surgery ( $T_2$ ). Definitions of the landmarks, reference planes, and skeletal variables are provided in Figure 2 and Table 1. The X axis has been defined as the Frankfort horizontal (FH) line and the Y axis as the line perpendicular to the X axis and passing through the Nasion. The intraskeletal reference planes were the palatal plane, the mandibular plane, and the maxillary

**Table 1.** Definitions of measurements used in study

Measurement	Definition
<b>A. Skeletal</b>	
FH-palatal (°)	Angle between Frankfort horizontal (FH) plane and palatal plane
FH-occlusal (°)	Angle between FH plane and maxillary occlusal plane
FMA (°)	Angle between FH plane and mandibular plane
<b>B. Dental (Mx.)</b>	
U1 to SN (°)	Angle formed by lines sella-nasion (SN) and U1E-U1A
U1-X (mm)	Horizontal distance from U1E to Y axis
U1-Y (mm)	Vertical distance from U1E to X axis
U6-X (mm)	Horizontal distance from U6MBC to Y axis
U6-Y (mm)	Vertical distance from U1E to X axis
U1-palatal (mm)	Vertical distance from U1E to palatal plane
U6-palatal (mm)	Vertical distance from U6MBC to palatal plane
<b>C. Dental (Mn.)</b>	
L1-Mn plane (mm)	Vertical distance from L1E to mandibular plane
L6-Mn plane (mm)	Vertical distance from L6MBC to mandibular plane
U1 to MxOP (°)	Angle between maxillary occlusal plane and U1E-U1A
L1 to MnOP (°)	Angle between mandibular occlusal plane (MnOP) and line of L1E-L1A
IMPA (°)	Angle between mandibular plane and line of L1E-L1A
<b>D. Interdental relationship</b>	
Interincisal angle (°)	Angle of line of U1E-U1A and L1E-L1A
Incisor overjet (mm)	Distance of maxillary incisor tip beyond mandibular incisor tip parallel to the occlusal plane
Incisor overbite (mm)	Distance of maxillary incisor tip beyond mandibular incisor tip vertical to the occlusal plane

Mx., Maxillary; Mn., mandibular.

Refer to Figure 2 for the location of each landmarks.

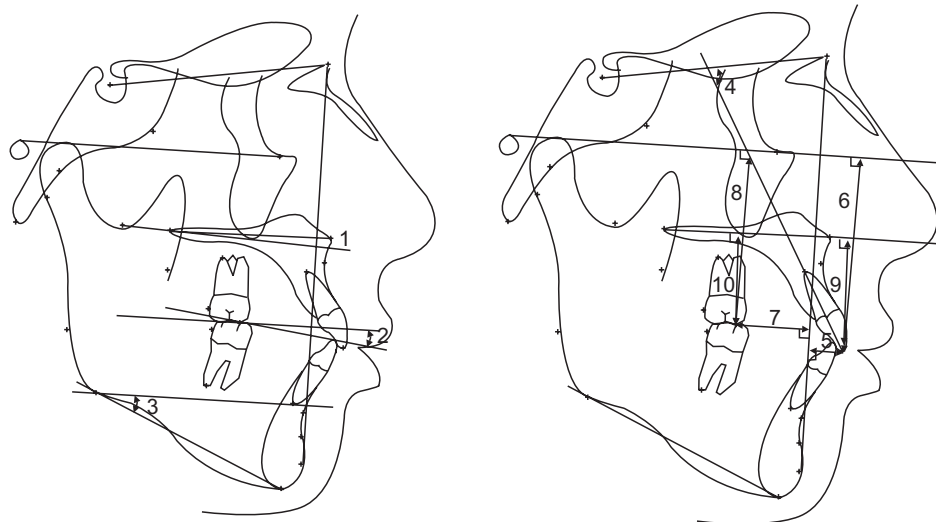
occlusal plane.<sup>11</sup>

**Assessment by lateral cephalogram**

The angular and linear measurements are illustrated in Figure 3 and defined in Table 2. FH-palatal, FH-occlusal and FMA were measured to assess the extent of skeletal movement during post-surgical orthodontic treatment (Figure 3).

To assess the extent of dental changes to the maxilla and mandible during postoperative orthodontic treatment, the horizontal and vertical distances from the incisal edges of the maxillary central incisors were measured, as were the distances from the mesiobuccal cusp tips of the maxillary first molars to the vertical and horizontal reference planes (U1-X, U1-Y, U6-

X, U6-Y, U1-palatal, U6-palatal). The perpendicular distances from mandibular central incisors and the mesiobuccal cusp tips of the mandibular first molars to the mandibular plane were also measured (Figure 4). The incisor inclination of the maxilla (U1 to SN, U1 to MxOP) and the mandible (L1 to Mn plane, L1 to MnOP) and the positional changes of the incisal edges (interincisal angle, incisor overjet, incisor overbite) were measured (Figure 5). The cephalograms were digitized by a single operator using the V-Ceph program (version 6.0; CyberMed, Seoul, Korea). To evaluate intraoperator variability, 10 variables for each patient were reassessed by the same operator after 3 weeks. Because no statistically significant differences ( $p > 0.05$ ) were observed, the first set of measurements was accepted.



**Figure 3.** Cephalometric measurements. 1, FH-palatal plane; 2, FH-maxillary occlusal plane; 3, FMA; 4, U1 to SN; 5, U1-X; 6, U1-Y; 7, U6-X; 8, U6-Y; 9, U1-palatal; and 10, U6-palatal. Refer to Figure 2 and Table 1 for the definition of each measurements.

**Table 2.** Skeletal measurements for group 1 and group 2

Measurement	T <sub>0</sub>	T <sub>1</sub>	T <sub>2</sub>	Sig
Group 1				
FH-palatal (°)	2.13 ± 4.71	1.98 ± 4.61	1.81 ± 4.86	0.96
FH-occlusal (°)	13.52 ± 4.44	13.05 ± 5.00	11.97 ± 4.64	0.35
FMA (°)	28.57 ± 4.69	29.04 ± 4.79	29.54 ± 4.95	0.69
Group 2				
FH-palatal (°)	3.96 ± 5.07	3.55 ± 3.75	3.49 ± 4.14	0.88
FH-occlusal (°)	14.64 ± 4.94	13.36 ± 4.42	13.35 ± 4.59	0.39
FMA (°)	28.96 ± 4.99	29.31 ± 4.81	29.21 ± 5.04	0.95

Values are presented as mean ± standard deviation.

Group 1, Surgical archwire fixation group; group 2, orthodontic miniscrew fixation group; T<sub>0</sub>, immediately after surgery; T<sub>1</sub>, 3 months after surgery; T<sub>2</sub>, 6 months after surgery; Sig, significance.

Refer to Figure 2 and Table 1 for the definition and units of each measurements.

**Statistical analysis**

Statistical analyses were conducted using IBM SPSS Statistics software version 21.0 (IBM Co., Armonk, NY, USA); *p*-values less than 0.05 were considered statistically significant. Time-dependent changes in cephalometric measurement variables indicating dental and skeletal changes were compared with one-way analysis of variance (ANOVA) and Duncan's *post-hoc*

test in each group. Independent sample *t*-tests were used to compare the differences between the groups.

The intra-assessor reproducibility of the measurements was determined by evaluating the variables of 10 randomly selected patients twice, at 3-week intervals, according to the intraclass correlation coefficient (ICC). The mean ICC was 0.965 in the 95% confidence interval.

**RESULTS**

The mean and standard deviation values, as determined from all of the cephalometric measurements immediately after surgery ( $T_0$ ), 3 months after surgery ( $T_1$ ), and 6 months after surgery ( $T_2$ ), were determined. The differences between the  $T_0$  and  $T_1$  stages ( $\Delta T_1$ ;  $T_0-T_1$ ) and the  $T_0$  and  $T_2$  stages ( $\Delta T_2$ ;  $T_0-T_2$ ) were analyzed.

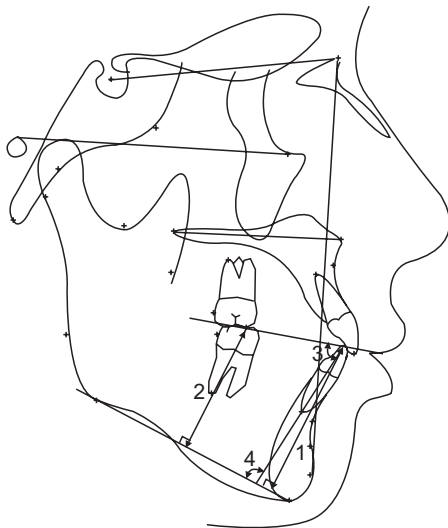
**Skeletal changes**

The FH-palatal plane, FH-occlusal plane, and FMA, as referenced in the measurement of skeletal changes during post-surgical orthodontic treatment, showed no significant time-dependent differences in either group (Table 2). There was no significant skeletal relapse 6 months after surgery ( $p > 0.05$ ).

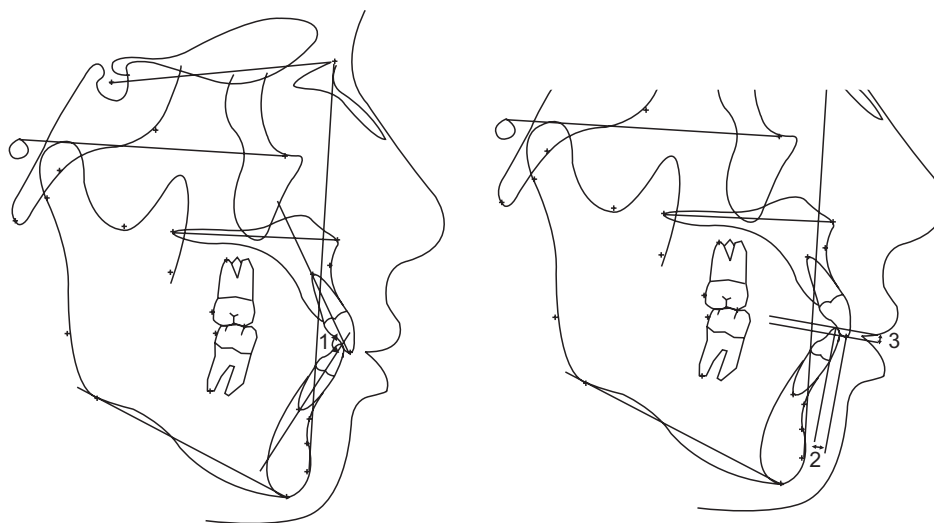
**Dental changes in the wire-fixation group (group 1; Table 3)**

**Vertical changes**

In group 1, U1 to SN increased significantly ( $p < 0.05$ ) but U1 to MxOP tended to decrease. For both U1-Y and U1-palatal, there was no significant difference in the



**Figure 4.** Cephalometric measurements of the mandible. 1, L1-mandibular plane; 2, L6-mandibular plane; 3, L1 to MnOP, and 4, IMPA. Refer to Figure 2 and Table 1 for the definition of each measurements.



**Figure 5.** Cephalometric measurements of interdental relationship. 1, Interincisal angle; 2, incisor overjet; and 3, incisor overbite. Refer to Figure 2 and Table 1 for the definition of each measurements.

**Table 3.** Dental changes in group 1 and group 2

Measurement	T <sub>0</sub>	T <sub>1</sub>	T <sub>2</sub>	Sig
<b>Group 1</b>				
FH-palatal (°)	2.13 ± 4.71	1.98 ± 4.61	1.81 ± 4.86	0.959
FH-occlusal (°)	13.52 ± 4.44	13.05 ± 5.00	11.97 ± 4.64	0.352
FMA (°)	28.57 ± 4.69	29.04 ± 4.79	29.54 ± 4.95	0.688
U1 to SN (°)	103.71 ± 5.39	105.42 ± 6.56	106.38 ± 6.77	0.048*
U1 to MxOP (°)	53.58 ± 4.85	52.35 ± 4.53	52.51 ± 4.59	0.471
U1-X (mm)	7.96 ± 4.60	8.81 ± 4.69	8.79 ± 4.93	0.677
U1-Y (mm)	60.86 ± 5.42	60.63 ± 5.59	60.35 ± 5.66	0.925
U6-X (mm)	27.61 ± 5.02	27.24 ± 4.62	26.93 ± 4.75	0.830
U6-Y (mm)	52.44 ± 5.58	52.49 ± 5.64	52.84 ± 5.49	0.946
U1-palatal (mm)	34.37 ± 3.87	34.26 ± 4.06	33.61 ± 4.14	0.679
U6-palatal (mm)	27.29 ± 3.26	27.33 ± 3.35	27.28 ± 3.18	0.997
IMPA (mm)	86.56 ± 7.83	86.32 ± 6.74	85.80 ± 6.89	0.898
L1 to Mn plane (mm)	49.07 ± 5.26	49.61 ± 5.07	49.90 ± 5.17	0.779
L6 to Mn plane (mm)	36.75 ± 4.22	36.25 ± 3.99	36.14 ± 3.69	0.778
L1 to MnOP (°)	71.13 ± 6.77	69.40 ± 5.92	69.11 ± 6.02	0.329
Interincisal angle (°)	131.97 ± 8.51	130.04 ± 8.13	129.14 ± 7.97	0.322
Incisor overjet (mm)	3.76 ± 1.14	3.82 ± 1.29	3.55 ± 1.04	0.582
Incisor overbite (mm)	0.30 ± 1.59	1.95 ± 0.90	1.86 ± 0.99	0.001 <sup>†</sup>
<b>Group 2</b>				
FH-palatal (°)	3.96 ± 5.07	3.55 ± 3.75	3.49 ± 4.14	0.880
FH-occlusal (°)	14.64 ± 4.94	13.36 ± 4.42	13.35 ± 4.59	0.395
FMA (°)	28.96 ± 4.99	29.31 ± 4.81	29.21 ± 5.04	0.951
U1 to SN (°)	104.63 ± 7.42	106.48 ± 7.76	106.56 ± 7.96	0.047*
U1 to MxOP (°)	52.46 ± 5.74	51.33 ± 6.12	51.25 ± 5.71	0.607
U1-X (mm)	7.34 ± 4.18	8.29 ± 5.13	8.18 ± 5.20	0.655
U1-Y (mm)	62.41 ± 4.46	60.94 ± 3.53	60.94 ± 3.96	0.194
U6-X (mm)	28.69 ± 3.86	27.94 ± 4.41	27.85 ± 4.49	0.648
U6-Y (mm)	53.23 ± 4.02	52.49 ± 3.94	52.58 ± 3.92	0.681
U1-palatal (mm)	34.21 ± 3.50	32.88 ± 3.12	32.88 ± 3.15	0.133
U6-palatal (mm)	27.55 ± 2.75	26.67 ± 3.14	26.72 ± 2.92	0.355
IMPA (°)	85.11 ± 7.15	85.74 ± 6.17	85.98 ± 6.87	0.848
L1 to Mn plane (mm)	49.35 ± 4.32	49.49 ± 4.38	49.61 ± 4.33	0.969
L6 to Mn plane (mm)	37.17 ± 4.00	36.59 ± 3.65	36.93 ± 3.89	0.806
L1 to MnOP (°)	73.02 ± 6.12	70.81 ± 5.99	70.89 ± 6.18	0.215
Interincisal angle (°)	133.03 ± 9.49	129.62 ± 9.30	129.41 ± 9.47	0.184
Incisor overjet (mm)	4.22 ± 1.31	4.02 ± 0.95	3.90 ± 1.05	0.458
Incisor overbite (mm)	0.89 ± 0.87	1.77 ± 1.11	2.05 ± 0.89	0.000 <sup>†</sup>

Values are presented as mean ± standard deviation.

Group 1, Surgical archwire fixation group; group 2, orthodontic miniscrew fixation group; T<sub>0</sub>, immediately after surgery; T<sub>1</sub>, 3 months after surgery; T<sub>2</sub>, 6 months after surgery; Sig, significance.

\* $p < 0.05$ , <sup>†</sup> $p < 0.01$ .

Refer to Figure 2 and Table 1 for the definition and units of each measurements.

**Table 4.** Dental-change difference between group 1 and group 2

Measurement	Group	$\Delta T_1 (T_0-T_1)$		$\Delta T_2 (T_0-T_2)$	
		Mean $\pm$ SD	Sig	Mean $\pm$ SD	Sig
FH-palatal ( $^{\circ}$ )	Group 1	-0.16 $\pm$ 1.38	0.700	-0.32 $\pm$ 2.16	0.827
	Group 2	-0.41 $\pm$ 3.67		-0.47 $\pm$ 3.74	
FH-occlusal ( $^{\circ}$ )	Group 1	-0.47 $\pm$ 2.10	0.215	-1.55 $\pm$ 4.45	0.787
	Group 2	-1.28 $\pm$ 3.34		-1.28 $\pm$ 3.83	
FMA ( $^{\circ}$ )	Group 1	0.47 $\pm$ 2.18	0.857	0.97 $\pm$ 4.94	0.458
	Group 2	0.36 $\pm$ 3.01		0.25 $\pm$ 3.17	
U1 to SN (mm)	Group 1	1.71 $\pm$ 2.92	0.894	2.67 $\pm$ 5.41	0.568
	Group 2	1.85 $\pm$ 5.81		1.93 $\pm$ 5.71	
U1 to MxOP ( $^{\circ}$ )	Group 1	-1.23 $\pm$ 2.96	0.925	-1.07 $\pm$ 4.36	0.890
	Group 2	-1.14 $\pm$ 4.73		-1.22 $\pm$ 4.87	
U1-X (mm)	Group 1	0.86 $\pm$ 1.77	0.895	0.83 $\pm$ 3.92	0.984
	Group 2	0.95 $\pm$ 3.70		0.85 $\pm$ 3.85	
U1-Y (mm)	Group 1	-0.22 $\pm$ 1.15	0.016*	-0.51 $\pm$ 6.05	0.396
	Group 2	-1.47 $\pm$ 2.85		-1.47 $\pm$ 3.10	
U6-X (mm)	Group 1	-0.37 $\pm$ 1.69	0.482	-0.68 $\pm$ 4.49	0.860
	Group 2	-0.75 $\pm$ 2.83		-0.84 $\pm$ 3.13	
U6-Y (mm)	Group 1	0.04 $\pm$ 0.91	0.110	0.39 $\pm$ 5.81	0.340
	Group 2	-0.74 $\pm$ 2.78		-0.65 $\pm$ 3.05	
U1-palatal (mm)	Group 1	-0.11 $\pm$ 1.29	0.019*	-0.76 $\pm$ 3.82	0.463
	Group 2	-1.33 $\pm$ 2.58		-1.33 $\pm$ 2.68	
U6-palatal (mm)	Group 1	0.04 $\pm$ 0.96	0.073	-0.01 $\pm$ 3.51	0.293
	Group 2	-0.88 $\pm$ 2.91		-0.83 $\pm$ 3.15	
IMPA ( $^{\circ}$ )	Group 1	-0.24 $\pm$ 4.11	0.539	-0.76 $\pm$ 11.02	0.458
	Group 2	0.63 $\pm$ 7.53		0.87 $\pm$ 7.38	
L1 to Mn plane (mm)	Group 1	0.54 $\pm$ 1.86	0.575	0.84 $\pm$ 5.12	0.579
	Group 2	0.14 $\pm$ 3.93		0.25 $\pm$ 3.80	
L6 to Mn plane (mm)	Group 1	-0.50 $\pm$ 1.54	0.885	-0.62 $\pm$ 4.07	0.678
	Group 2	-0.58 $\pm$ 3.19		-0.24 $\pm$ 3.70	
L1 to MnOP ( $^{\circ}$ )	Group 1	-1.73 $\pm$ 4.33	0.730	-2.01 $\pm$ 8.24	0.950
	Group 2	-2.21 $\pm$ 7.32		-2.13 $\pm$ 7.05	
Interincisal angle ( $^{\circ}$ )	Group 1	-1.92 $\pm$ 4.99	0.376	-2.83 $\pm$ 10.85	0.728
	Group 2	-3.41 $\pm$ 8.82		-3.62 $\pm$ 8.56	
Incisor overjet (mm)	Group 1	0.07 $\pm$ 1.84	0.484	-0.20 $\pm$ 1.41	0.704
	Group 2	-0.19 $\pm$ 1.28		-0.32 $\pm$ 1.23	
Incisor overbite (mm)	Group 1	1.64 $\pm$ 1.48	0.017*	1.55 $\pm$ 1.62	0.211
	Group 2	0.87 $\pm$ 1.22		1.16 $\pm$ 1.02	

Group 1, Surgical archwire fixation group; group 2, orthodontic miniscrew fixation group;  $T_0$ , immediately after surgery;  $T_1$ , 3 months after surgery;  $T_2$ , 6 months after surgery; SD, standard deviation; Sig, significance.

\* $p < 0.05$ .

Refer to Figure 2 and Table 1 for the definition and units of each measurements.

vertical position at each time point. Likewise, the U6-Y and U6-palatal values, indicating the vertical position of the maxillary first molar, did not change with time.

#### Horizontal changes

U1-X and U6-X, indicating the anteroposterior dental position, showed no significant differences over time ( $p > 0.05$ ).

#### Changes in interdental relationship

The interincisal angle and incisor overjet tended to decrease but the decreases were not statistically significant. ANOVA analysis of time-course changes showed that the incisor overbite value increased at each measurement point and that the differences were significant ( $p < 0.05$ ). The Duncan post-hoc test was used to determine the differences between  $T_0$  and  $T_1$ .

#### Dental changes in screw fixation group (group 2)

##### Vertical changes

In the screw fixation group (group 2), U1 to SN increased significantly ( $p < 0.05$ ) but U1 to MxOP did not. There were no significant differences in the U1-Y or U1-palatal values at any of the time points. Likewise, the U6-Y or U6-palatal values, indicating the vertical position of the maxillary first molar, showed no significant change.

##### Horizontal changes

U1-X, representative of the anteroposterior position of the maxillary incisor edge, showed no significant differences over time. U6-X tended to decrease, but the decrease was not statistically significant.

##### Changes in interdental relationship

The interincisal angle and incisor overjet showed a tendency to decrease but the decreases were not statistically significant. However, changes in the incisor overbite showed a statistically significant increase between  $T_0$  and  $T_1$  ( $p < 0.05$ ), with the values reflecting those of the Duncan *post-hoc* test differences between  $T_0$  and  $T_1$ , as was the case in the wire fixation group (group 1).

#### Dental-change differences for groups 1 and 2 (Table 4)

##### Vertical change differences

The results of an intergroup comparison are listed in Table 4. U1 to SN increased significantly in  $\Delta T_1$  and the extent of change was similar. However, U1 to MxOP did not show statistically significant differences ( $p > 0.05$ ). In group 1, U1-Y and U1-palatal, indicating the mean vertical position of the maxillary incisor, showed

smaller differences than in group 2 ( $p < 0.05$ ). However, this fact is not meaningful because an intragroup comparison (Table 4) showed no significant differences over time. Finally, the changes to U6-Y and U6-palatal ( $\Delta T_1 [T_0-T_1]$ ,  $\Delta T_2 [T_0-T_2]$ ), indicating the mean vertical positional change of the maxillary first molar, did not show statistically significant differences.

##### Horizontal change differences

The differences in the horizontal changes (U1-X, U6-X in both groups) between the groups, as determined by independent samples *t*-test, were not statistically significant ( $p > 0.05$ ).

##### Interdental-relationship change differences

Considering the interincisal angle and incisor overjet, there were no significant differences between the groups in  $\Delta T_1$  or  $\Delta T_2$ . The changes to incisor overbite manifested as statistically significant time-dependent increases in both groups (Table 4), although the extent of increase differed according to the group ( $p < 0.05$ , Table 4). The incisor overbite in group 1 in  $\Delta T_1$  ( $1.64 \pm 1.48$ ) was smaller than that in group 2 ( $0.87 \pm 1.22$ ); the difference was small but statistically significant ( $p < 0.05$ ).

## DISCUSSION

With the advent of the use of screws for IMF, many surgeons have shifted to that technique to avoid or reduce the disadvantages of using the traditional arch bar and wiring techniques. Certainly, the use of screws for IMF has provided many benefits to patients and surgeons. The dental-change differences according to the fixation method had not been evaluated.

Hovell<sup>12</sup> reported maxillary incisor inclination increased at 3 months after surgery, although the inclination decreased significantly with movement of the maxilla immediately after surgery. In the present study, postoperative labial-inclination tendency of the maxillary incisor was seen in both groups, but there was no significant difference in this regard between the groups. Furthermore, there was no significant time-dependent change in any measurements of vertical dental position. The labioversion of the maxillary incisors during the post-surgical orthodontic treatment was caused by the Class III mechanics. Skeletal relapse and compensatory movement of dental structures take place simultaneously after surgical correction of mandibular prognathism.<sup>13,14</sup> Furthermore, dental decompensation in skeletal Class III malocclusion had labioversed maxillary incisors due to skeletal and muscular limitations.<sup>12</sup> Control of maxillary incisor inclination during postoperative orthodontic treatment is needed.<sup>15</sup>



Some studies have reported a limited correction in mandibular incisor inclination during surgical orthodontic treatment, as well as difficulty in changing mandibular incisor inclination by more than 5 degrees.<sup>12,16,17</sup> In the present study, the measurements for the mandibular dentition did not show statistically significant change between the groups.

No significant time-course interdental-relationship differences were found between the groups for the cephalometric variables evaluated, except for incisor overbite. Incisor overbite increased significantly from T<sub>0</sub> to T<sub>1</sub> in both groups, and more so in the screw fixation group than in the wire fixation group. We suggest that maintenance of upper teeth position after surgery should continue for 3 months in order to stabilize the bone structure.

Wisth and Isaksen<sup>2</sup> reported that all forces are transmitted to all dentitions; the vertical vector causes extrusion of anterior teeth and muscle forces are responsible for changes in incisor inclination. They showed that application of vertical forces during orthodontic treatment can result not only in incisor inclination but also in root resorption and consequent loss of marginal periodontal support for extruded teeth. Baek et al.<sup>11</sup> suggested that the maxillary central incisor's direction and extent of relapse (from the vertical position) seem to be more influenced by postoperative orthodontic treatment than is the case for the maxillary first molar, and that post-surgical orthodontic treatment mechanics should be applied to maintain surgical results.

In the present study, increasing tendency of overbite during post-surgical treatment was greater in the wire fixation group than the screw fixation group. We suggest that the use of miniscrew fixation can be beneficial for maintaining surgical results and for minimizing maxillary incisor extrusion.

We set the surgical occlusion on the basis of proper molar relations, canine relations, overjet and overbite, considering both pre-surgical dentition and the extent of post-surgical dental compensation. The overbite of the surgical occlusion at the surgical treatment objective can be made deeper or shallower according to IMF type. In a surgery-first approach, passive surgical wires can be bonded directly to the tooth surface or ligated into the brackets.<sup>15</sup> In our comparison of the two types of fixation appliances there was no significant difference in any dental cephalometric measurement except incisor overbite. Furthermore, the overbite difference was too small to be clinically relevant. Therefore, miniscrew IMF can be viewed as a useful method for first-surgery approach or, in cases where the use of full-size rectangular surgical wire is problematic. On analyzing the use of miniscrews versus surgical archwire in IMF from the crucial perspective of both practical and clinical

considerations, we believe that there were no significant differences in the post-surgical dental changes for the two methods.

The use of the miniscrews for IMF provides many benefits to patients and surgeons: 1) quick and easy insertion; 2) compatibility with any plating system; 3) ideal for use in cases of heavily restored teeth; 4) ease of maintenance of gingival health compared with that seen for arch bars and eyelet wires, and 5) easy and painless removal without anesthesia on an out-patient basis.<sup>1</sup> Additionally, orthodontic miniscrews can be used as anchors for elastic traction. The most common complication associated with the use of miniscrews is iatrogenic injury to dental roots.<sup>19-23</sup> Clinicians need to be aware of this potential complication and take appropriate steps to avoid it.<sup>24</sup>

## CONCLUSION

In the present study, the changes in cephalometric values after 2-jaw orthognathic surgery were compared between two groups of patients, one with miniscrew fixation and the other with wire fixation. The results showed that there were no dental-change differences attributable to one or the other type of fixation, except for incisor overbite. Incisor overbite increased moderately in both groups during the post-surgical orthodontic treatment but the increase was slightly more in the wire fixation group than the miniscrew group. Overall, the results suggest that miniscrew fixation is no less effective clinically than wire fixation. This means that a clinician can choose the fixation type depending on the individual case, e.g., miniscrew fixation may be more useful in a surgery-first approach without orthodontic bracket bonding, or in cases where the use of surgical archwire would be difficult.

## REFERENCES

1. Jones DC. The intermaxillary screw: a dedicated bicortical bone screw for temporary intermaxillary fixation. *Br J Oral Maxillofac Surg* 1999;37:115-6.
2. Wisth PJ, Isaksen TS. Changes in the vertical position of the anterior teeth after surgical correction of mandibular protrusion. *Am J Orthod* 1980;77:174-83.
3. Thota LG, Mitchell DA. Cortical bone screws for maxillomandibular fixation in orthognathic surgery. *Br J Orthod* 1999;26:325.
4. Arthur G, Berardo N. A simplified technique of maxillomandibular fixation. *J Oral Maxillofac Surg* 1989;47:1234.
5. Gibbons AJ, Hodder SC. A self-drilling intermaxillary fixation screw. *Br J Oral Maxillofac Surg* 2003;41:

- 48-9.
6. Sahoo NK, Mohan R. IMF Screw: An ideal intermaxillary fixation device during open reduction of mandibular fracture. *J Maxillofac Oral Surg* 2010;9:170-2.
  7. Lee JS, Park HS, Kyung HM. Micro-implant anchorage for lingual treatment of a skeletal Class II malocclusion. *J Clin Orthod* 2001;35:643-7.
  8. Park HS, Bae SM, Kyung HM, Sung JH. Micro-implant anchorage for treatment of skeletal Class I bialveolar protrusion. *J Clin Orthod* 2001;35:417-22.
  9. Park YC, Lee SY, Kim DH, Jee SH. Intrusion of posterior teeth using mini-screw implants. *Am J Orthod Dentofacial Orthop* 2003;123:690-4.
  10. Ueki K, Marukawa K, Shimada M, Nakagawa K, Yamamoto E. The use of an intermaxillary fixation screw for mandibular setback surgery. *J Oral Maxillofac Surg* 2007;65:1562-8.
  11. Baek SH, Kim K, Choi JY. Evaluation of treatment modality for skeletal Class III malocclusion with labioversed upper incisors and/or protrusive maxilla: surgical movement and stability of rotational maxillary setback procedure. *J Craniofac Surg* 2009;20:2049-54.
  12. Hovell JH. Muscle patterning factors in the surgical correction of mandibular prognathism. *J Oral Surg Anesth Hosp Dent Serv* 1964;22:122-6.
  13. Troy BA, Shanker S, Fields HW, Vig K, Johnston W. Comparison of incisor inclination in patients with Class III malocclusion treated with orthognathic surgery or orthodontic camouflage. *Am J Orthod Dentofacial Orthop* 2009;135:146.e1-9.
  14. Lim LY, Cunningham SJ, Hunt NP. Stability of mandibular incisor decompensation in orthognathic patients. *Int J Adult Orthodon Orthognath Surg* 1998;13:189-99.
  15. Kim DK, Baek SH. Change in maxillary incisor inclination during surgical-orthodontic treatment of skeletal Class III malocclusion: comparison of extraction and nonextraction of the maxillary first premolars. *Am J Orthod Dentofacial Orthop* 2013;143:324-35.
  16. Baek SH, Ahn HW, Kwon YH, Choi JY. Surgery-first approach in skeletal Class III malocclusion treated with 2-jaw surgery: evaluation of surgical movement and postoperative orthodontic treatment. *J Craniofac Surg* 2010;21:332-8.
  17. Nagasaka H, Sugawara J, Kawamura H, Nanda R. "Surgery first" skeletal Class III correction using the Skeletal Anchorage System. *J Clin Orthod* 2009;43:97-105.
  18. Hashemi HM, Parhiz A. Complications using intermaxillary fixation screws. *J Oral Maxillofac Surg* 2011;69:1411-4.
  19. Coburn DG, Kennedy DW, Hodder SC. Complications with intermaxillary fixation screws in the management of fractured mandibles. *Br J Oral Maxillofac Surg* 2002;40:241-3.
  20. Roccia F, Tivolaccini A, Dell'Acqua A, Fasolis M. An audit of mandibular fractures treated by intermaxillary fixation using intraoral cortical bone screws. *J Craniomaxillofac Surg* 2005;33:251-4.
  21. Holmes S, Hutchison I. Caution in use of bicortical intermaxillary fixation screws. *Br J Oral Maxillofac Surg* 2000;38:574.
  22. Choi JH, Yu HS, Lee KJ, Park YC. Three-dimensional evaluation of maxillary anterior alveolar bone for optimal placement of miniscrew implants. *Korean J Orthod* 2014;44:54-61.
  23. Kim JH, Park YC. Evaluation of mandibular cortical bone thickness for placement of temporary anchorage devices (TADs). *Korean J Orthod* 2012;42:110-7.
  24. Kim JS, Choi SH, Cha SK, Kim JH, Lee HJ, Yeom SS, et al. Comparison of success rates of orthodontic mini-screws by the insertion method. *Korean J Orthod* 2012;42:242-8.