



Clinical characteristics of lung abscess in children: 15-year experience at two university hospitals

Mi Suk Choi, MD^{1,2}, Ji Hye Chun, MD¹, Kyung Suk Lee, MD, PhD³, Yeong Ho Rha, MD, PhD², Sun Hee Choi, MD, PhD¹

¹Department of Pediatrics, Kyung Hee University Hospital at Gangdong, Kyung Hee University School of Medicine, Seoul, ²Department of Pediatrics, Kyung Hee University Hospital, Kyung Hee University School of Medicine, Seoul, ³Department of Pediatrics, CHA Bundang Medical Center, CHA University, Seongnam, Korea

Purpose: Information on the clinical features of lung abscess, which is uncommon in children, at hospitalization is helpful to anticipate the disease course and management. There is no report concerning lung abscess in Korean children. We aimed to identify the clinical characteristics of pediatric lung abscess and compare the difference between primary and secondary abscess groups.

Methods: The medical records of 11 lung abscess patients (7 males and 4 females) from March 1998 to August 2011 at two university hospitals were retrospectively reviewed. The clinical characteristics, symptoms, underlying disease, laboratory and radiologic findings, microbiological results, and treatments were examined.

Results: Six patients had underlying structural-related problems (e.g., skeletal anomalies). No immunologic or hematologic problem was recorded. The mean ages of the primary and secondary groups were 2.4 and 5.3 years, respectively, but the difference was not statistically significant. The mean length of hospital stay was similar in both groups (22.8 days vs. 21.4 days). Immunologic studies were performed in 3 patients; the results were within the normal range. Most patients had prominent leukocytosis. Seven and 4 patients had right and left lung abscess, respectively. *Staphylococcus aureus*, *Streptococcus pneumoniae*, and antimycoplasma antibodies were detected in both groups. Two patients with primary lung abscess were administered antibiotics in the absence of other procedures, while 8 underwent interventional procedures, including 5 with secondary abscess.

Conclusion: The most common symptoms were fever and cough. All patients in the primary group were younger than 3 years. Structural problems were dominant. Most patients required interventional procedures and antibiotics.

Key words: Lung abscess, Child, Predisposing factor

Corresponding author: Sun Hee Choi, MD, PhD
Department of Pediatrics, Kyung Hee Hospital at Gangdong, 892 Dongnam-ro, Gangdong-gu, Seoul 05278, Korea

Tel: +82-2-440-6278

Fax: +82-2-440-6295

E-mail: chsh0414@naver.com

Received: 15 September, 2014

Revised: 3 December, 2014

Accepted: 12 December, 2014

Introduction

Lung abscess is a thick-walled cavity in the pulmonary parenchyma that contains purulent material and is initiated or complicated by infectious organisms¹. Lung abscess is classified as primary or secondary depending on underlying conditions. Primary lung abscess occurs in the absence of a specific lung disease, while secondary lung abscess occurs in the presence of predisposing structural or functional lung diseases including congenital lung disorders, ciliary dyskinesia, and cystic fibrosis, systemic diseases such as neuro-developmental abnormalities and congenital immunodeficiencies that may lead to aspiration or infection^{1,2}. It is known that primary and secondary lung abscesses present differences in causative organisms, progression, and prognosis^{3,4}.

The introduction of antimicrobials into clinical practice has improved the prognosis of lung abscess, but the literature from 1969 to 2005 reported mortality rates ranging from

Copyright © 2015 by The Korean Pediatric Society

This is an open-access article distributed under the terms of the Creative Commons Attribution Non-Commercial License (<http://creativecommons.org/licenses/by-nc/3.0/>) which permits unrestricted non-commercial use, distribution, and reproduction in any medium, provided the original work is properly cited.

2.0%–38.2%⁵). Pediatric lung abscess can occur at any age and morbidity is lower than that in adults^{1,2}. There are few published articles regarding the prevalence and clinical course of pediatric lung abscess in children^{1,2}, and in Korea, there have been only a few reports of cases associated with congenital cystic adenomatoid malformation or necrotizing pneumonia⁶⁻⁸. The aim of this study is to understand clinical characteristics and to compare the difference between primary and secondary lung abscess for effective evaluation and treatments for lung abscess in Korean children. For these, data from patients with lung abscess at two university hospitals during 15 years were collected and information on clinical manifestations, management, and outcomes was reviewed.

Materials and methods

1. Patients

In this study, the diagnosis of lung abscess satisfied the following criteria: (1) air-fluid level on chest radiographs; (2) thick-walled cavities containing suppurative material and destruction of lung parenchyma on chest computed tomography (CT); (3) radiologist readings that confirmed lung abscess at the time of hospitalization if no radiographs or CT images were available in the record. We excluded cases of pneumonia, necrotizing pneumonia, and empyema without definite abscess formation on radiologic images. We retrospectively reviewed medical records from March 1997 to August 2011. Patients who were discharged from the Pediatric Department, Kyung Hee University Hospital at Gangdong, and Kyung Hee University Medical Center with an International Classification of Disease-9 diagnosis code for lung abscess were selected. After reviewing the medical records, we identified a total of 11 patients under 16 years of age whose radiologic findings were consistent with lung abscess. The patients were categorized into primary and secondary abscess groups in accordance with the presence of underlying disease.

2. Methods

Patient characteristics, clinical symptoms and signs, time to defervescence and recovery, length of hospital stay, and the presence of underlying disease were investigated. Laboratory findings were examined for inflammatory responses and microbiological tests, including blood, sputum, urine, or thoracic fluid cultures and specific antigen or antibody reaction in serum and urine were examined for causative organisms. We reviewed treatment regimens including antibiotic therapy and interventional invasive procedures, designated as percutaneous drainage and surgical procedures including chest tube insertion (thoracostomy), thoracotomy, or lobectomy. Recovery from disease was defined as one of the following: radiologic resolution, clinical symptom improvement, or defervescence (maintenance of body temperature below 38°C

for at least 24 hours)^{9,10}. We characterized the lung lesions by location and size of abscess, pneumothorax, pleural effusion, and spherical mass or cyst on chest radiographs and chest CT images.

3. Statistical analysis

The patients were classified into primary and secondary abscess groups depending on the presence of underlying disease. Differences between 2 groups were examined using the Mann-Whitney *U* test for continuous variables and Fisher chi-square test for dichotomous outcomes (SPSS ver. 15, SPSS Inc., Chicago, IL, USA). Continuous variables were expressed as mean±standard deviation and dichotomous outcomes were described as number of patients or percentages (%). *P* values of <0.05 were considered statistically significant.

Results

1. Patient data, underlying diseases, and radiologic and laboratory findings (Table 1)

A total of 11 patients with lung abscess were recruited (male:female=7:4). Male patients tended to have primary lung abscess (male:female=4:1 vs. 3:3, primary and secondary, respectively). The age of the patients ranged from 1 to 16 years. The mean age of the primary abscess group was younger than that of the secondary abscess group (2.4±0.5 years vs. 5.3±6.0 years, *P*=0.976), although this was not statistically significant. All patients in the primary abscess group were younger than 36 months.

Five patients with primary lung abscess had no history of choking or aspiration and 6 patients in the secondary group had underlying disease without aspiration. The underlying conditions in patients with secondary abscess were neonatal respiratory distress syndrome (1 patient), congenital cystic adenomatoid malformation (CCAM, 2 patients), pectus excavatum (2 patients), and Tetralogy of Fallot (1 patient). The abscess was located in cysts in patient with CCAM (Fig. 1). One of 2 patients with pectus excavatum had a medical history of incompletely treated pulmonary tuberculosis and thoracic scoliosis. The other patient had developmental delay. The patient with Tetralogy of Fallot had a history of treatment for wound infection after Blalock-Taussing shunt and total correction. Immunologic tests were performed in 2 patients in the primary group and 1 patient in the secondary group. The findings of immunologic studies were with normal ranges.

On chest radiographs, pneumonia was the most common finding associated with lung abscess (10 patients), followed by atelectasis, pneumatocele, pleural effusion, thoracic mass or cyst (3 patients), and pneumothorax (2 patients). The locations of the lung abscesses were varied on chest CT. In patients with primary abscess, 2 were located in the right lung and 3 were in the left lung. Two patients exhibited involvement of more than two pulmonary lobes, one

with abscess in left upper and lower lobes and the other with lung abscess in the right upper and middle lobes. The lung abscesses were >20 mm in diameter, and the size was not significantly different between primary and secondary groups (38±15.7 mm vs. 42±19.4 mm, respectively, *P*=0.833).

White blood cell counts, C-reactive protein (CRP) and erythrocyte sedimentation rates (ESRs) on admission were elevated in 10 of 11 patients, and there were no difference between 2 groups: complete blood cell count (22,170/μL vs. 14,904/μL), CRP (11.7 mg/dL vs. 14.5 mg/dL) and ESR (46.2 mm/hr vs. 59.6 mm/hr). Nine patients presented with a left shift in the leukocyte count; 2 patients were excluded due to missing or incomplete medical records.

2. Clinical manifestations and laboratory data

Fever was the most common symptom, and was reported in all 11 patients (100%) at the time of admission. Ten patients (91%) presented with cough and sputum. Rhinorrhea and dyspnea were reported in 3 (27%) and 2 patients (18%), respectively. A variety of symptoms such as chest pain, weight loss, abdominal pain, lethargy, and shoulder pain were also present (Table 2).

The mean duration of fever before hospitalization was 9.1±8.3

days in all 11 patients without significance between 2 groups (9.6±8.0 days vs 8.7±9.2 days, *P*=0.8). There were no differences between primary and secondary abscess groups in terms of length of hospital stay (21.4±9.9 days vs. 22.8±11.4 days, *P*=0.9), mean time to defervescence (17.4±7.6 days vs. 12.0±7.2 days, *P*=0.353), hospital days before invasive procedure, including thoracostomy, thoracotomy, or surgery (12.3±11.2 days vs. 19.2±9.4 days, *P*=

Table 2. Clinical manifestations of the lung abscess patients (n=11)

Presentation	No. of patients (%)
Fever	11 (100)
Cough, sputum	10 (91)
Rhinorrhea (patients 3, 6, 7)	3 (27)
Dyspnea (patients 5, 8, 10)	2 (18)
Chest pain (patient 7)	1 (9)
Weight loss (patient 8)	1 (9)
Abdominal pain (patient 8)	1 (9)
Lethargy (patient 4)	1 (9)
Shoulder pain & swelling (patient 4)	1 (9)
Redness around sternum (patient 11)	1 (9)

Some patients had more than one symptom

Table 1. Demographic data, underlying diseases, and radiologic and laboratory findings (n=11)

Patient No.	Sex/age (yr)	Fever duration	Underlying diseases	Radiologic findings	Location of lung abscess	WBC (cells/μL)/segmented neutrophil (%)	CRP (mg/dL)/ESR (mm/hr)
Primary lung abscess (n=5)							
1	M/2	16		Pneumonia, pneumatocele	LLL sup. seg.	14,900/62.2	0.97/60
2	F/3	2		Pneumonia, atelectasis, pleural effusion	LUL apico-posterior seg, LLL sup. seg.	28,350/85.0	7.32/52
3	M/2	3		Pneumonia	RUL apical & post. seg.	18,900/54.7	14.79/47
4	M/3	20		Thoracic mass or cyst	LUL	37,100/*	6+ [†] /60
5	M/2	7		Pneumonia, atelectasis, Pleural effusion, pneumothorax, pneumatocele	RUL, RML	11,600/84.0	23.6/12
Secondary lung abscess (n=6)							
6	M/2	2	RDS	Pneumonia	RLL sup. seg.	15,030/51.2	10.9/64
7	F/9	2	CCAM	Pneumonia	LUL apico-posterior seg.	13,500/84.7	17.36/44
8	F/16	20	Incomplete treatment of pulmonary Tbc, pectus excavatum scoliosis	Pneumonia, pneumothorax	RUL, apical, anterior & post. seg.	17,990/92.0	29.9/78
9	M/1	21	CCAM	Pneumonia, pneumatocele, pleural effusion, thoracic cyst	RLL sup., lateral basal, post. basal seg.	13,900/65.3	2.37/62
10	M/3	4	Pectus excavatum, developmental delay	Pneumonia, thoracic mass	RLL sup. & post. basal seg.	15,700/*	*/*
11	F/1	3	TOF, s/p BT shunt & total correction, wound infection	Pneumonia, atelectasis	RUL apical & post. seg.	15,700/48.4	12/50

WBC, white blood cell counts; CRP, C-reactive protein; ESR, erythrocyte sedimentation rate; LLL, left lower lobe; sup., superior; post., posterior; seg., segment; LUL, left upper lobe; RUL, right upper lobe; RML, right middle lobe; RDS, respiratory distress syndrome; RLL, right lower lobe; CCAM, congenital cystic adenomatoid malformation; Tbc, tuberculosis; TOF, Tetralogy of Fallot; BT shunt, Blalock-Taussing shunt; s/p, state of postoperation.

*Missing or incomplete medical records. [†]Semiquantitative data.

0.393), and time to recovery or discharge (24.7 ± 6.5 days vs. 14.8 ± 7.4 days, $P=0.161$).

3. Etiology and treatments

Putative microbiologic results were found for 6 patients (55%) from specimens of blood, sputum, urine, and thoracic fluid (Table 3). *Staphylococcus aureus* was isolated from pleural culture in 1 patient and *Streptococcus pneumoniae* was isolated in 3 patients, from culture of abscess specimen, blood culture with pleural culture, and urine antigen test, respectively. Antimycoplasm antibody tests were performed in 8 patients and were positive response in 2 patients. There was no evidence of viral infection in any patient. No microbial pathogens were detected in the other 5 patients.

Two patients in the primary abscess group were improved with antibiotic therapy alone. One patient who had recurrent fever and rash suggestive of Kawasaki disease was treated with intravenous immunoglobulin. One patient with *S. pneumoniae* pneumonia who had had persistent fever after discharge from the hospital was diagnosed with lung abscess by chest x-ray performed in the outpatient clinic, and showed improvement in clinical symptoms and radiologic findings upon treatment with a third generation oral cephalosporin.

Eight patients were treated with invasive procedures in combination with antibiotic therapy including third-generation cephalosporins, clarithromycin, clindamycin, vancomycin, and beta-lactam/beta-lactamase complexes. Third generation cephalosporins (8 patients) and clindamycin (7 patients) were used most com-

Table 3. Etiologic pathogens and treatments in lung abscess patients (n=11)

Patient No.	Specimens	Isolated pathogens	Procedures
Primary lung abscess (n=5)			
1	Blood	Not found	None
2	Blood	<i>M. pneumoniae</i>	Chest tube
3	Urine	<i>S. pneumoniae</i>	None
4	Pleural fluid Cx.	<i>S. aureus</i>	Chest tube & lung segmentectomy
5	Pleural fluid & blood Cx.	<i>S. pneumoniae</i>	Chest tube
Secondary lung abscess (n=6)			
6	Abscess Cx.	<i>S. pneumoniae</i>	Chest tube
7	Blood	<i>M. pneumoniae</i>	Lung segmentectomy & chest tube
8	Blood	Not found	Chest tube
9	Blood	Not found	Chest tube
10	Blood	Not found	Fluoroscopy guided closed thoracotomy
11	Blood	Not found	None*

Cx., culture; *M. pneumoniae*, *Mycoplasma pneumoniae*; *S. pneumoniae*, *Streptococcus pneumoniae*; *S. aureus*, *Staphylococcus aureus*.

*One patient was transferred to another hospital without undergoing invasive procedures.

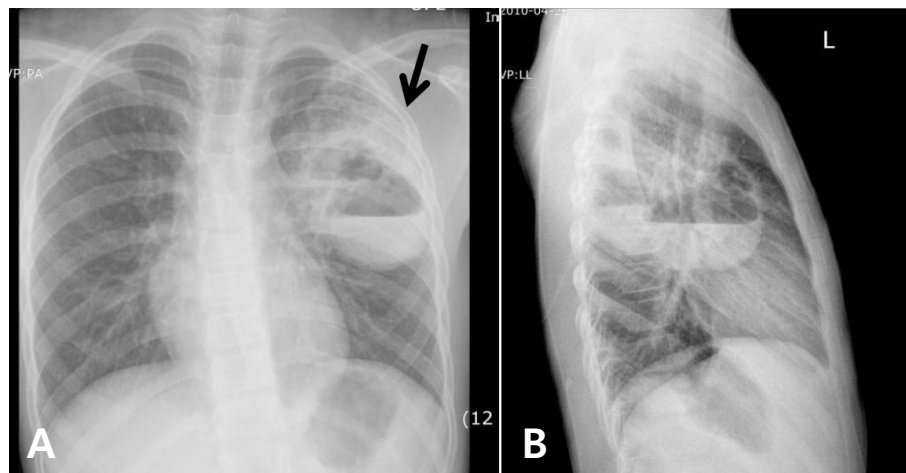


Fig. 1. The chest radiography of a typical secondary lung abscess with congenital cystic adenomatoid malformation in patient 7 shows two cysts with an air-fluid level (arrow), respectively, on postero-anterior view (A) and lateral view (B).

monly. The antibiotic regimens were similar in the primary and secondary groups. Pleural injection of urokinase and imipenem via the chest tube was tried in 1 patient who had serological confirmation of *Mycoplasma pneumoniae*. There was no significant difference between groups in the mean duration of intravenous antibiotics administration during hospitalization (19.8 ± 10.9 days vs. 22.3 ± 10.6 days, $P=0.762$) or in the time to defervescence after antibiotics use (8.8 ± 8.0 days vs. 6.2 ± 3.8 days, $P=0.755$).

Three patients in the primary abscess group and 5 in the secondary abscess group required invasive procedures (60% vs. 80%). One patient with CCAM (Fig. 1) and one with primary abscess due to multidrug resistant *S. aureus* underwent segmentectomy after the acute inflammatory phase. Histologic findings in the patient with primary lung abscess due to *S. aureus* revealed acute and chronic inflammation with fibrosis consistent with abscess and including hemorrhage and edema and focal peripheral emphysematous change. The other patient was diagnosed with type II CCAM with organizing pneumonia. Three patients in the primary abscess group required thoracostomy. The infecting organisms in these patients were *S. aureus* in 1, *S. pneumoniae* in 1, and *M. pneumoniae* in 1. Four patients in the secondary abscess group required thoracostomy and 1 underwent fluoroscopy-guided thoracotomy. All of these patients had favorable outcomes without any complications.

Discussion

In this study, there were several findings that differ from those of previous studies. First, the patients with primary lung abscess were around 2 years of age, and were younger than those with secondary lung abscess, although this did not reach statistical significance because the sample size was too small. The finding that all of the patients in the primary group were younger than 3 years has not been reported in other studies. Second, in the secondary group, predisposing factors related to structural problems such as skeletal anomalies were dominant. Third, in previous reports, percutaneous aspiration was a preferred intervention when needed, while in the present series the majority of patients underwent interventional procedures that included thoracostomy and segmentectomy, and in all such cases, the timely interventional procedures appeared to be valuable. Lastly, in the present series, there were no reported sequelae in any patients; all were completely cured.

While all patients in the present series had fever, none presented with gastrointestinal signs or symptoms or hemoptysis^{1,4,8,11,12}. One patient, who had penicillin resistant *S. aureus* in pleural effusion, reported shoulder pain. Overall, in the present study, there was no significant difference in clinical manifestations between primary and secondary lung abscess groups.

Previous studies have reported that duration of hospitalization ranged from 13 days to 28 days in patients with primary lung abscess and was longer for patients with secondary lung abscess⁴. However, in the present study, the duration of hospital stay did not differ between the two groups. The discordance may be because of the small number of patients, and, in addition, the types of underlying or accompanying conditions. Conditions such as leukemia, congenital heart disease, central nervous system abnormalities, and immune compromise have been reported as common predisposing factors in cases of secondary lung abscess^{1,4,11,12}. We confirmed underlying lung diseases in 4 patients, including respiratory distress syndrome, partially treated pulmonary tuberculosis, and CCAM, while 2 patients had structural abnormalities (pectus excavatum and scoliosis). Pectus excavatum and scoliosis are musculoskeletal disorders that influence lung function by means of restrictive lung disease caused by decreased intrathoracic capacity, atelectasis caused by cardiac displacement with subsequent left lung compression, and, in severe cases, paradoxical respiration caused by disturbed mechanical forces^{10,13}. These mechanical problems in the lung, rather than a lack of pulmonary immunological defense, may have contributed to abscess formation. It should also be noted that predisposing underlying factors may have differed as a result of the prevalence of primary immune deficiencies and trends of antibiotics use in Korea^{14,15}.

Aspiration plays a major role of lung abscess formation which is related with dependent segments¹⁶. In our series, 6 patients including 1 patient with primary abscess and *S. aureus* pneumonia, and 1 with secondary abscess and CCAM required segmentectomy had abscess in superior or posterior segments of lower lobes and posterior segments of upper lobes. However, there was no history of aspiration in our patients.

In contrast to lung abscess in adults^{11,17,18}, primary and secondary lung abscess in children is frequently caused by *S. pneumoniae*, *S. aureus*, and *Pseudomonas aeruginosa*^{1,17}. Because of a reluctance to perform invasive procedures, such as transtracheal aspiration and percutaneous lung needle biopsy, it may be difficult to verify the pathogens in lung abscess. Only 3 patients had pathogens (*S. pneumoniae* in 2 and *S. aureus* in 1) isolated in bacterial cultures^{5,12}, and several patients had findings suggestive of recent infection by *M. pneumoniae* and *S. pneumoniae*, i.e., high anti-mycoplasma antibody titer and positive rapid antigen urine test. Only a few cases of pulmonary abscess in children with *M. pneumoniae* infection have been described in the literature, and because false-positive test results are common, the detection of pneumococcal antigen in urine by Binax Now is not recommended for the diagnosis of pneumococcal pneumonia in children¹⁹. In this study, detection of the antipneumococcal antigen in urine may have meant only a low possibility of *S. pneumoniae* as a pathogen.

Administration of parenteral antibiotics for 2–3 weeks followed by oral therapy is recommended as treatment for lung abscess^{6–8},

and beta-lactam/beta-lactamase complex is regarded as the treatment of choice for primary lung abscess²⁰. Other studies have reported the use of broad-spectrum antibiotics including third-generation cephalosporins and flucloxacillin or fluoroquinolones for coverage of aerobic and anaerobic bacteria and penicillin-resistant strains^{1,6-8,20}. In our series, third generation cephalosporins and clindamycin were commonly used, and no patients were treated with fluoroquinolones.

Abscess drainage is necessary in 20% of cases. The primary indications for drainage are failure to respond to medical therapy alone and the presence of factors such as significant hemoptysis, suspected neoplasm, fever persisting beyond 7–10 days^{1,21}, or abscess size >6 cm^{1,7,21}. Several authors have reported that left untreated, lung abscesses can lead to irreversible changes including bronchiectasis and fibrosis within 6 to 12 weeks^{21,22}. Management decisions in patients with lung abscess may be affected by the nature of the underlying disease. In our patients, thoracostomy was common, which was a different approach from previous studies that have reported percutaneous aspiration as treatment for abscess associated with pneumonia and effusion.

In conclusion, lung abscess in children can occur over a wide range of ages, but an age of <3 years may be influential. Structural problems that cause chest wall deformities or mechanical changes are predominant factors in secondary lung abscess. The combination of antibiotics treatment and interventional procedures may result in a more favorable clinical course for patients with lung abscess in the presence of any aggravating condition. In the present series, the rate of identification of pathogens was low and attempted identification of pathogens was lacking.

Conflict of interest

No potential conflict of interest relevant to this article was reported.

Acknowledgments

This study was exempt from Institutional Review Board oversight in the aspect that all patients had been hospitalized in a conventional therapeutic setting and cases were reported before 2011.

References

1. Patradoon-Ho P, Fitzgerald DA. Lung abscess in children. *Paediatr Respir Rev* 2007;8:77-84.
2. Miller MA, Ben-Ami T, Daum RS. Bacterial pneumonia in neonates and older children. In: Taussig LM, Landau LI, editors. *Pediatric respiratory medicine*. St. Louis: Mosby, 1999.
3. Lorber B. Bacterial lung abscess. In: Mandell GL, Bennett JE, Dolin R, editors. *Mandell, Douglas, and Bennett's principles and practice of infectious diseases*. 7th ed. Philadelphia (PA): Churchill Livingstone/Elsevier, 2010;925-9.
4. Yen CC, Tang RB, Chen SJ, Chin TW. Pediatric lung abscess: a retrospective review of 23 cases. *J Microbiol Immunol Infect* 2004;37:45-9.
5. Takayanagi N, Kagiyama N, Ishiguro T, Tokunaga D, Sugita Y. Etiology and outcome of community-acquired lung abscess. *Respiration* 2010;80:98-105.
6. Jun SE, Park HJ. Clinical features of congenital cystic adenomatoid malformation of the lung. *Pediatr Allergy Respir Dis* 2008;18:129-37.
7. Lee KY, Yim SJ, Yoon JS, Han JW, Lee JS. Two cases of community acquired necrotizing pneumonia in healthy children. *Pediatr Allergy Respir Dis* 2006;16:71-8.
8. Pyun BY, Kim HH, Chung JT, Lee JS. A study as epidemiologic and clinical aspect of *Mycoplasma pneumoniae* pneumonia during the last 5 years. *Pediatr Allergy Respir Dis* 1998;8:240-7.
9. Francois P, Desrumaux A, Cans C, Pin I, Pavese P, Labarere J. Prevalence and risk factors of suppurative complications in children with pneumonia. *Acta Paediatr* 2010;99:861-6.
10. Kliegman RM, Stanton BM, Geme JS, Schor NF, Behrman RE, editors. *Nelson textbook of pediatrics*. 19th ed. Philadelphia (PA): WB Saunders Co., 2011;1480-1.
11. Moreira Jda S, Camargo Jde J, Felicetti JC, Goldenfun PR, Moreira AL, Porto Nda S. Lung abscess: analysis of 252 consecutive cases diagnosed between 1968 and 2004. *J Bras Pneumol* 2006;32:136-43.
12. Chan PC, Huang LM, Wu PS, Chang PY, Yang TT, Lu CY, et al. Clinical management and outcome of childhood lung abscess: a 16-year experience. *J Microbiol Immunol Infect* 2005;38:183-8.
13. Goretsky MJ, Kelly RE Jr, Croitoru D, Nuss D. Chest wall anomalies: pectus excavatum and pectus carinatum. *Adolesc Med Clin* 2004;15:455-71.
14. Korea Centers for Disease Control and Prevention [Internet]. Cheongju: Korea Centers for Disease Control and Prevention; 2006 [cited 2014 Sep 14]. Available from: http://cdc.go.kr/CDC/cms/content/88/1188_view.html.
15. Song JH. Current status and future strategies of antimicrobial resistance in Korea. *Korean J Med* 2009;77:143-51.
16. Prather AD, Smith TR, Poletto DM, Tavora F, Chung JH, Nallamshetty L, et al. Aspiration-related lung diseases. *J Thorac Imaging* 2014;29:304-9.
17. Bartlett JG. Anaerobic bacterial infections of the lung. *Chest* 1987;91:901-9.
18. Bartlett JG. The role of anaerobic bacteria in lung abscess. *Clin Infect Dis* 2005;40:923-5.
19. Yazbeck MF, Dahdel M, Kalra A, Browne AS, Pratter MR. Lung abscess: update on microbiology and management. *Am J Ther* 2014;21:217-21.
20. Committee on Infectious Diseases. The use of systemic fluoroquinolones. *Pediatrics* 2006;118:1287-92.
21. Bradley JS, Byington CL, Shah SS, Alverson B, Carter ER, Harrison C, et al. The management of community-acquired pneumonia in infants and children older than 3 months of age: clinical practice guidelines by the Pediatric Infectious Diseases Society and the Infectious Diseases Society of America. *Clin Infect Dis* 2011;53:e25-76.
22. Lee JY, Koo SM, Park KA, Seo YR, Kim SH, Kim YK, et al. Analysis of lung parenchymal sequelae following treatment for lung abscess. *Tuberc Respir Dis* 2011;71:438-44.