

Severe Anemia Due to Parvovirus Infection Following Treatment with Rituximab in a Pediatric Kidney Transplant Recipient : Anemia after Treatment of Rituximab in Kidney Recipient Patient

**Seung Yun Kim, M.D.,
Hyoung Jin Lee, M.D.,
Eujin Park, M.D.,
Yo Han Ahn, M.D.,
Il-Soo Ha, M.D.,
Hae Il Cheong, M.D.,
Hee Gyung Kang, M.D.**

Department of Pediatrics, Seoul
National University College of
Medicine, Seoul, Korea,
Research Coordination Center for Rare
Diseases, Seoul National University
Hospital, Seoul, Korea

Corresponding author:

Hee Gyung Kang, M.D.
Department of Pediatrics, Seoul National
University Children's Hospital Research
Coordination Center for Rare Diseases, Seoul
National University Hospital 101 Daehang-
no, Jongno-Gu Seoul 110-769, Korea
Tel: +82-2-2072-0658
Fax: +82-2-743-3455
E-mail: kanghg@snu.ac.kr

Received: 8 August 2015
Revised: 30 September 2015
Accepted: 13 October 2015

This is an open-access article distributed under the terms of the Creative Commons Attribution Non-Commercial License (<http://creativecommons.org/licenses/bync/3.0/>) which permits unrestricted non-commercial use, distribution, and reproduction in any medium, provided the original work is properly cited.

Copyright © 2015 The Korean Society of
Pediatric Nephrology

Rituximab (RTX), a monoclonal antibody against the B-cell marker CD20, is commonly used as a treatment for antibody-mediated diseases or B-lymphocyte-mediated diseases. Destruction of B cells may reverse the disease course in many conditions; however, patients who are treated with RTX cannot respond appropriately to *de novo* infection due to lack of B lymphocytes. Here, we report one such case. A 7-year-old renal allograft recipient presented with severe anemia due to parvovirus infection after RTX treatment. The patient had focal segmental glomerulosclerosis and had received cadaveric kidney transplantation 6 months previously. She was treated with high-dose steroid for acute rejection and RTX for Epstein Barr Virus infection 3 months previously. At presentation, her hemoglobin level was 5.4 g/dL and leukocyte and platelet counts were normal. She had microcytic normochromic anemia and high viral load of parvovirus B19(70,578 copies/mL). Intravenous immunoglobulin (200 mg/kg-d) treatment controlled the progression of anemia and parvovirus infection. *De novo* parvovirus infection during the B lymphocyte-depletion period may have precipitated the severe anemia in this case. Close monitoring of infection is required after RTX therapy.

Key words: Rituximab, parvovirus, kidney transplantation, PRCA, anemia

Introduction

Renal transplantation is known as the treatment of choice for children who have end-stage renal disease. The result of pediatric kidney transplantation has improved with the development of more potent immunosuppressive agents such as tacrolimus and mycophenolate mofetil have lower acute rejection rates, superior graft survival rates, and lower mortality rates¹⁾. However, effective treatment approaches for post-transplantation complications such as infections and malignancies are yet to be established. According to the North American Renal Transplant Cooperative Study database, 2.4% of pediatric renal transplantation recipients developed a malignancy, over 50% of which are post-transplantation lymphoproliferative disorders (PTLDs), often caused by Epstein-Barr virus (EBV) infection²⁾. PTLDs are also reported in cases of hematopoietic stem cell transplantation, and in some transplantation

institutions, the anti-CD20 agent rituximab (RTX) is used as a preemptive therapy for EBV infection to prevent the development of PTLDs by destroying B cells, the main cells infected by the EBV³.

Pure red cell aplasia (PRCA) is known as severe normochromic, normocytic anemia associated with reticulocytopenia and the absence of erythroblasts in an otherwise normal bone marrow. It may present as a primary hematologic disorder or secondary to parvovirus infection, lymphoma, leukemia, thymoma, treatment with recombinant human erythropoietin (EPO) or other drugs, ABO-incompatible hematopoietic stem cell transplantation, and pregnancy⁴. Parvovirus infection is known to induce PRCA, especially in immunocompromised patients such as solid organ transplant recipients⁵, bone marrow transplant recipients⁶, and HIV-infected patients⁷. In a kidney organ transplant recipient, chronic anemia associated with parvovirus infection was reported⁸. There are some reports about complications following RTX therapy such as increased number of infection, hepatitis B reactivation, and progressive multifocal leukoencephalopathy, and a case where the patients developed parvovirus infection following RTX therapy for the treatment of lymphoma⁹. Here, we report a case of severe anemia caused by parvovirus infection following RTX therapy in a pediatric kidney transplant recipient.

Case report

A renal allograft recipient who was 7 years and 7 months old visited our hospital with complaints of tiredness. Six months previously, she had received a cadaveric kidney allograft after having undergone dialysis for five years. Her end-stage renal disease was caused by focal segmental glomerulosclerosis (FSGS). Kidney transplantation was successful without immediate postoperative complications. For maintenance of immunosuppression, prednisone, tacrolimus, and mycophenolate mofetil were administered. Her baseline creatinine level was 0.99 mg/dL. Three months after the kidney transplantation, her serum creatinine level increased to 1.63 mg/dL, and the allograft kidney biopsy showed moderate interstitial inflammation, suggesting acute T-cell-mediated rejection. At the time of biopsy, EBV viral load was 7,611 copies/mL, and whole-

blood antigen and CMV antigen test results were negative. Methyl prednisolone 5 mg/kg for 3 days was administered for treatment. In addition, RTX 375 mg/m² was administered to eradicate B cells, the main cells infected by the EBV. Within two months, her CMV viral load titer increased to 2,633 copies/mL plasma and CMV antigen load was 1/200,000 WBC, which successfully treated with ganciclovir induction therapy for 5 days.

At presentation, her creatinine level was 1.57 mg/dL with a tacrolimus level of 2.1 ng/mL. She had severe anemia (hemoglobin level 5.4 g/dL) with a reticulocyte count of 0.64% (normal range 0.5-1.8%); however, neither neutropenia nor thrombocytopenia was present (WBC 7190/ μ L and platelet 345,000/ μ L). A peripheral blood smear examination showed microcytic normochromic, anisocytic RBC along with atypical lymphocytes (1%). There was no evidence of iron deficiency (serum ferritin level 483.16 ng/mL [normal range 4.6-204.7 ng/mL], iron level 122 μ g/dL [normal range 50-130 μ g/dL], iron saturation 52.1% [normal range 16-60%]). Her direct and indirect Coombs tests were negative, plasma hemoglobin level was 5.3 mg/dL [normal range 0-5.0 mg/dL], and haptoglobin level was less than 7 mg/dL [normal range 30-180 mg/dL]. Although her plasma hemoglobin level was higher than normal and haptoglobin level was low, her reticulocyte count was normal and peripheral blood smear examination showed no evidence of hemolytic anemia. The B-cell number (CD19-positive cells) was zero and CMV and EBV titers were negative.

Parvovirus B19 PCR was positive and the viral load was 70,578 copies/mL plasma. With clinical diagnosis of parvovirus-associated PRCA, intravenous immunoglobulin (IVIG, 200 mg/kg/d) was administered for 4 days. After the treatment, her hemoglobin level increased, as shown in Figure 1, with a decrease of parvovirus viral load to 11,669 copies/mL plasma. Bone marrow study was not performed due to the recovery of anemia with treatment.

One month after her outpatient clinic follow-up, her hemoglobin level was 11.8 g/dL, and parvovirus viral load decreased to less than 100 copies/mL plasma.

Discussion

Here, we report a case of parvovirus infection associated

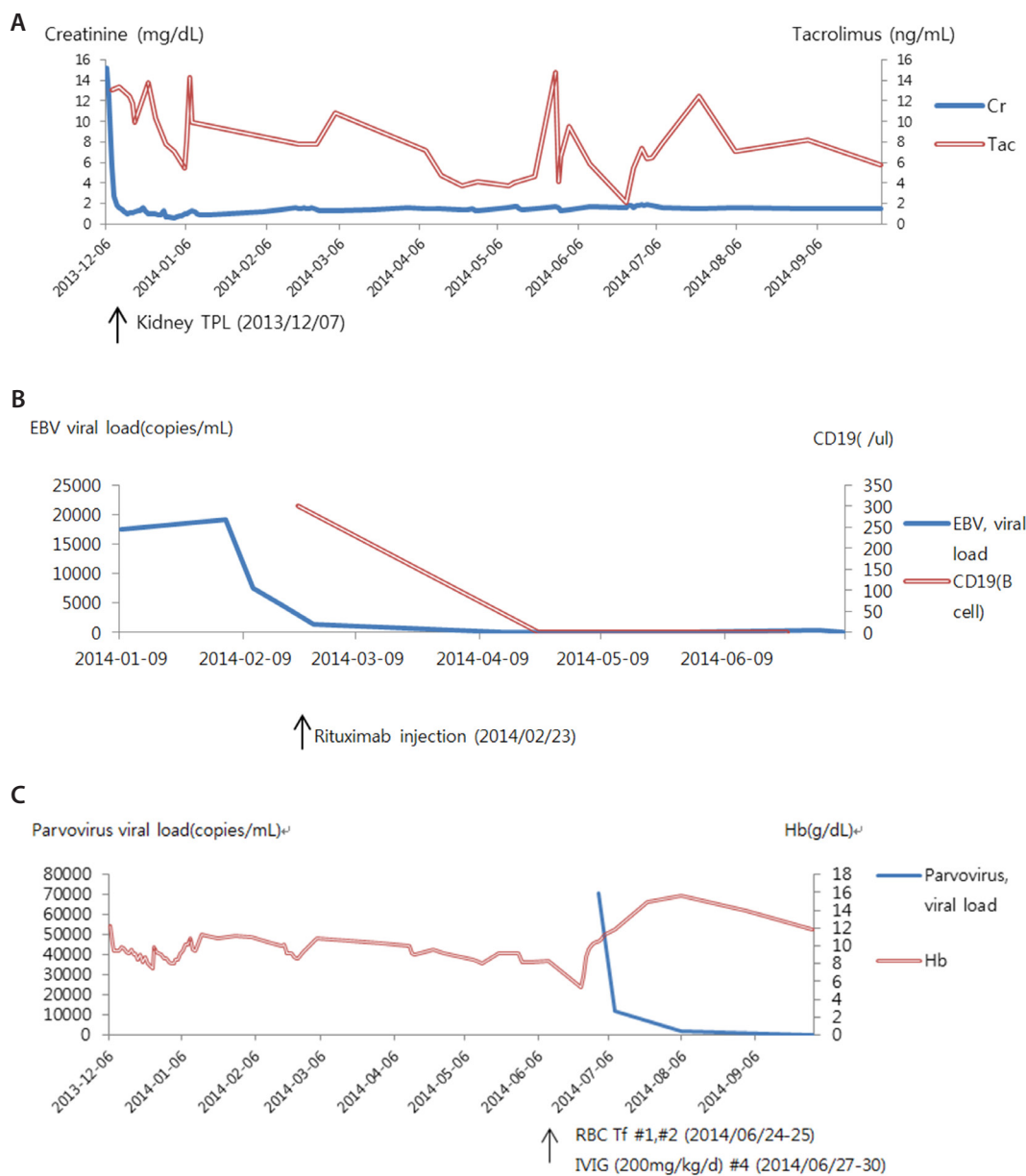


Fig.1. (A) Creatinine and tacrolimus levels. Abbreviation:TPL,transplantation (B) EBV viral load and CD19 (B cell) levels. (C) Changes in the hemoglobin level (g/dL) and parvovirus viral load during treatment. Abbreviation: Tf, transfusion

with severe anemia following RTX therapy in a pediatric kidney recipient. Other cases of patients who developed PRCA following RTX therapy have been previously reported. Sharma et al. described a patient with B-cell non-Hodgkin lymphoma treated with RTX who developed PRCA due to parvovirus B19 infection¹⁰. In another patient with B-cell lymphoma, the PRCA was due to parvovirus infection following treatment with CHOP and RTX¹¹.

In the field of kidney transplantation, currently, RTX is

commonly used for desensitization of ABO-incompatible transplants, treatment of antibody-mediated rejection, treatment of PTLDs, or recurrent and de novo glomerulonephritis in the allograft¹². In our case, RTX was administered to reduce the risk of EBV-related PTLD. After using RTX, B-cell counts remained zero for 2 months, and we suspected that the patient had been infected with parvovirus. As she did not have B lymphocytes, the patient was unable to produce antibodies against new infections.

Anemia without iron deficiency or definite hemolysis and without decrease in cell numbers of other lineages, led us to suspect parvovirus infection. Prompt resolution of anemia as well as a decrease in parvovirus titer with IVIG treatment also implies that impaired humoral immunity precipitated prolonged parvovirus infection, which in turn induced severe anemia.

In this case, the bone marrow biopsy was not performed due to prompt recovery of anemia with treatment. As the diagnosis of PRCA is confirmed by bone marrow biopsy, this patient was not confirmed to have PRCA. However, the possible diagnosis of PRCA was supported by other characteristics such as normal leukocyte and platelet counts with low reticulocyte count (below $10 \times 10^9/L$), without evidence of definite hemolysis, and increased parvovirus viral load during the anemic period.

Many cases of the secondary PRCAs are attribute to medications and disappear when the medication is stopped. Those secondary to parvovirus B19 can be treated by administration of intravenous immunoglobulin. Primary PRCAs and secondary PRCAs that do not respond to the treatment of the underlying disease are considered immunologically mediated diseases⁴⁾. A previous study has reported successful treatment of parvovirus infection with IVIG (0.5-2g/kg over 2-10 days)⁸⁾, and this treatment (dose: 200 mg/kg·day for 4 days) was also effective in the patient in the present case, as proven by the decrease in the viral titer and recovery of anemia.

In summary, parvovirus-associated severe anemia developed in a pediatric kidney allograft recipient following RTX therapy. Although RTX therapy has a wide range of applications, it also has adverse effects such as virus infections, as documented in this study, and therefore, its use should be carefully considered, and monitoring for opportunistic infections is required when RTX therapy is administered.

Acknowledgements

This study was supported by a grant (HI12C0014) from

the Korean Health Technology R&D Project, Ministry of Health & Welfare, the Republic of Korea.

References

1. Kim SD, Cho BS. Current status of pediatric kidney transplantation. *Korean J Pediatr.* 2009;52:1075-81.
2. North American Pediatric Renal Trials and Collaborative Studies. NAPRTCS 2010 Annual Transplant Report [Internet]. 2013 [cited April.3.2013]. Available from: https://webemmes.com/study/ped/annlrept/2010_Report.pdf.
3. Comoli P, Basso S, Zecca M, Pagliara D, Baldanti F, Bernardo ME, et al. Preemptive therapy of EBV-related lymphoproliferative disease after pediatric haploidentical stem cell transplantation. *Am J Transplant.* 2007;7:1648-55.
4. Sawada K, Fujishima N, Hirokawa M. Acquired pure red cell aplasia: updated review of treatment. *Br J Haematol.* 2008;142: 505-14.
5. Liang TB, Li DL, Yu J, Bai XL, Liang L, Xu SG, et al. Pure red cell aplasia due to parvovirus B19 infection after liver transplantation: a case report and review of the literature. *World J Gastroenterol.* 2007;13:2007-10.
6. Tsigotis P, Girkas K, Economopoulou C, Bouchla A, Papanicolaou N, Economopoulou P, et al. Pure Red Cell Aplasia due to B19 Parvovirus Infection after Autologous Stem Cell Transplantation. *Case Rep Transplant.* 2011;2011:251930.
7. Koduri PR. Parvovirus B19-related anemia in HIV-infected patients. *AIDS Patient Care STDS.* 2000;14:7-11.
8. Mathias RS. Chronic anemia as a complication of parvovirus B19 infection in a pediatric kidney transplant patient. *Pediatr Nephrol.* 1997;11:355-7.
9. Gea-Banacloche JC. Rituximab-associated infections. *Semin Hematol.* 2010;47:187-98.
10. Sharma VR, Fleming DR, Slone SP. Pure red cell aplasia due to parvovirus B19 in a patient treated with rituximab. *Blood.* 2000;96:1184-6.
11. Song KW, Mollee P, Patterson B, Brien W, Crump M. Pure red cell aplasia due to parvovirus following treatment with CHOP and rituximab for B-cell lymphoma. *Br J Haematol.* 2002;119:125-7.
12. Becker YT, Samaniego-Picota M, Sollinger HW. The emerging role of rituximab in organ transplantation. *Transpl Int.* 2006;19: 621-8.