

Mandibular metastasis of cholangiocarcinoma: A case report

Tae Min You¹, Kee-Deog Kim², Ho-Gul Jeong³, Wonse Park^{2,*}

¹Department of Advanced General Dentistry, Dankook University, Cheonan, Korea

²Department of Advanced General Dentistry, Yonsei University, Seoul, Korea

³Department of Oral and Maxillofacial Radiology, Yonsei University, Seoul, Korea

ABSTRACT

Tumors metastasizing from distant regions to the oral and maxillofacial region are uncommon, comprising only 1%-2% of all malignancies. Cholangiocarcinoma is a malignancy that arises from cholangiocytes, which are epithelial cells that line the bile ducts. These cancers are difficult to diagnose and have a poor prognosis. In this paper, we report a rare case of mandibular metastasis of cholangiocarcinoma diagnosed at the primary site and discuss the radiographic findings observed in this case. (*Imaging Sci Dent* 2015; 45: 247-51)

KEY WORDS: Cholangiocarcinoma; Neoplasm Metastasis; Mandible

Cholangiocarcinoma is a malignancy that arises from cholangiocytes, which are epithelial cells that line the bile ducts. It is the second most common primary liver cancer after hepatocellular carcinoma, and is rare in many parts of the world, including Europe and the USA, where it accounts for <1% of all malignant tumors. Cholangiocarcinoma is difficult to diagnose and has a poor prognosis, with five-year survival rates of <5%, due to its tendency to exhibit insidious progression.¹⁻³

Tumors metastasizing from distant regions to the oral cavity are rare, accounting for only 1%-2% of all malignancies.^{4,5} Metastatic tumors in the oral cavity are located mostly in the mandible, usually in the molar region.^{4,6} The clinical manifestations of mandibular metastasis include pain, bony or soft-tissue swelling, tooth mobility, a non-healing extraction site, and paresthesia of the lower lip. Metastases from the breast and lung can present as osteolytic lesions in the jaw, and metastases from the prostate can present as osteoblastic lesions, usually seen as radiopaque or mixed radiopaque and radiolucent lesions.^{4,7,8} According to previous studies, metastatic tumors in the

oral region mainly originate from the lung, kidneys, and prostate in men, and from the breast, reproductive system, and kidneys in women.^{4,9} In Korean studies, the most common site of origin has been reported to be the liver for males and the reproductive system for females.^{6,10} However, some cases of metastatic cholangiocarcinoma to the oral cavity, presenting as a maxillofacial lesion, have been reported in the literature.^{7,11-14}

We report herein a rare case of mandibular metastasis of cholangiocarcinoma diagnosed at the primary site and discuss the radiographic characteristics of this case.

Case report

A 54-year-old woman experienced migrating back pain and was treated with physical therapy in a local clinic, but the symptoms did not improve. Computed tomography revealed a mass in the left lobe of the liver, and she was thus referred to Yonsei Medical Center for further evaluation and treatment. Needle aspiration biopsy of the liver revealed intrahepatic cholangiocarcinoma (adenocarcinoma, well differentiated, T3NXM1; Fig. 1). Thoracic spine metastasis, which had caused a compression fracture at T11, was revealed on magnetic resonance imaging, and a whole-body bone scan was performed (Fig. 2). The liver mass was treated with chemotherapy for 12 months, and

Received June 20, 2015; Revised August 15, 2015; Accepted August 24, 2015

*Correspondence to : Prof. Wonse Park

Department of Advanced General Dentistry, College of Dentistry, Yonsei University, 50 Yonsei-ro, Seodaemun-gu, Seoul 03722, Korea
Tel) 82-2-2228-8980, Fax) 82-2-2227-8906, E-mail) wonse@yuhs.ac

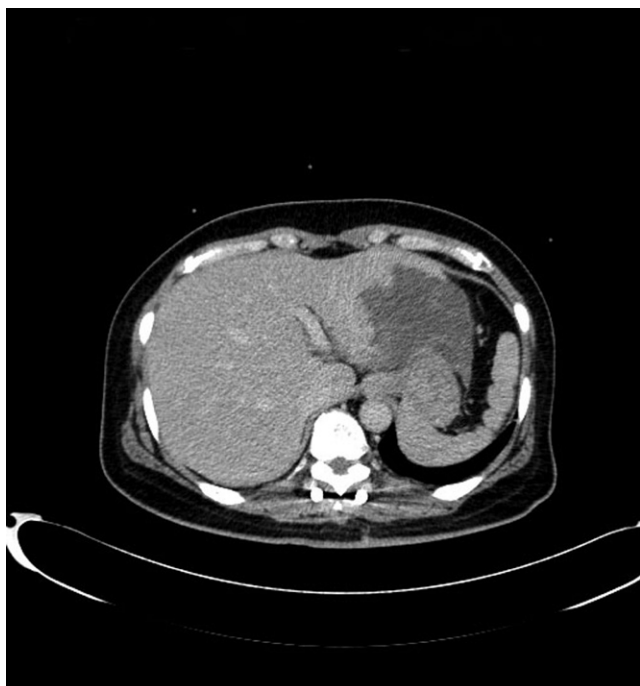

Fig. 1. A computed tomographic image of the abdomen demonstrates a left intrahepatic mass, which was found to be a cholangiocarcinoma.

the spinal metastasis was treated with radiotherapy and laminectomy with facetectomy. After completion of the 11th chemotherapy cycle, the patient refused further treatment.

One month later, the patient returned to the medical center with a complaint of painful swelling in the right mandible. Computed tomography revealed an expansile 2.0 cm × 1.2 cm soft-tissue mass involving the outer cortex of the body of the right posterior mandible. The buccal cortex of the mandible demonstrated osteolytic destruction and the lingual cortex was thinned (Fig. 3). A needle aspiration biopsy of the mandibular mass revealed metastatic mucin-forming adenocarcinoma from the liver. She refused a right hemimandibulectomy, and chose to receive radiotherapy. The patient was then referred from the Department of Radiation Oncology to the Department of General Dentistry at Yonsei University for dental evaluation and dental care prior to radiotherapy.

When she visited the dental clinic, she had no remarkable facial, bony, or vestibular swellings, and the cervical lymph nodes were not enlarged on palpation. Slight generalized gingival swelling and redness were noted, as well as heavy calculus deposition. A panoramic X-ray found a well-circumscribed radiolucent region on the right mental foramen of the mandible (Fig. 4). The right premolar had

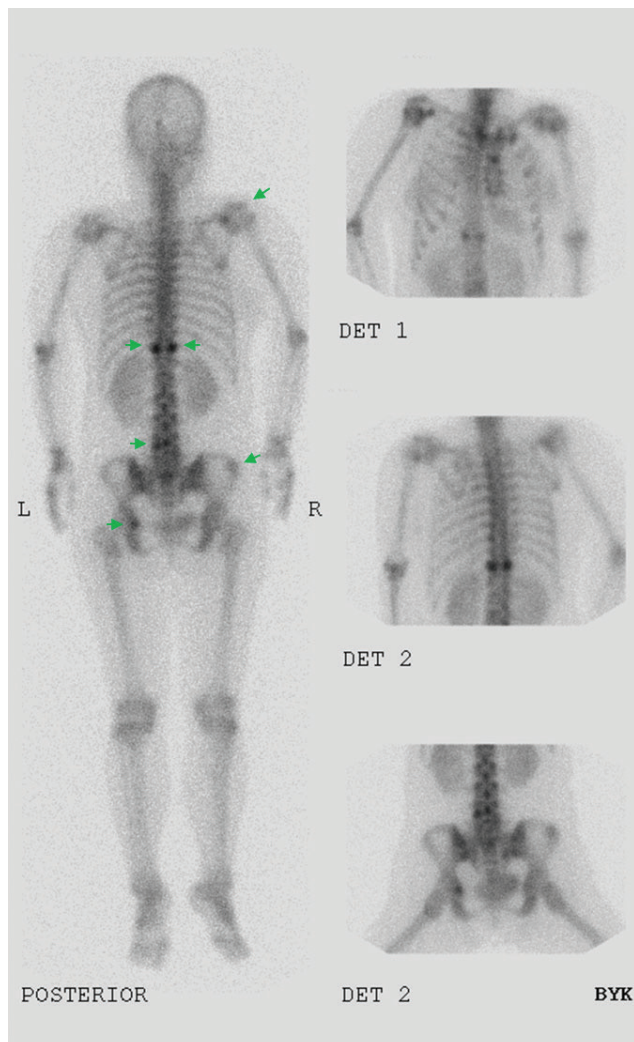


Fig. 2. A whole-body bone scan shows multiple bone metastases (arrows) from the cholangiocarcinoma.

the vitality on ice test and had no mobility. No paresthesia was reported in the right lower lip. She was treated with scaling and tooth brushing instructions only. A biopsy was not performed.

The patient underwent palliative radiotherapy in the area of the mandibular metastasis in several fractions (35 Gy in ten fractions). One month after radiation therapy, the mandibular pain had disappeared, but a whole-body positron-emission tomography/computed tomography (PET/CT) scan revealed hypermetabolism in the right liver, left humerus, sacrum, right ilium, and lumbar spine, mild hypermetabolism in the right mandible, and a small nodule in the right upper and lower lobes of the lung, suggesting multiple bone and lung metastases. The patient desired further treatment at another hospital, and did not return to Yonsei Medical Center.

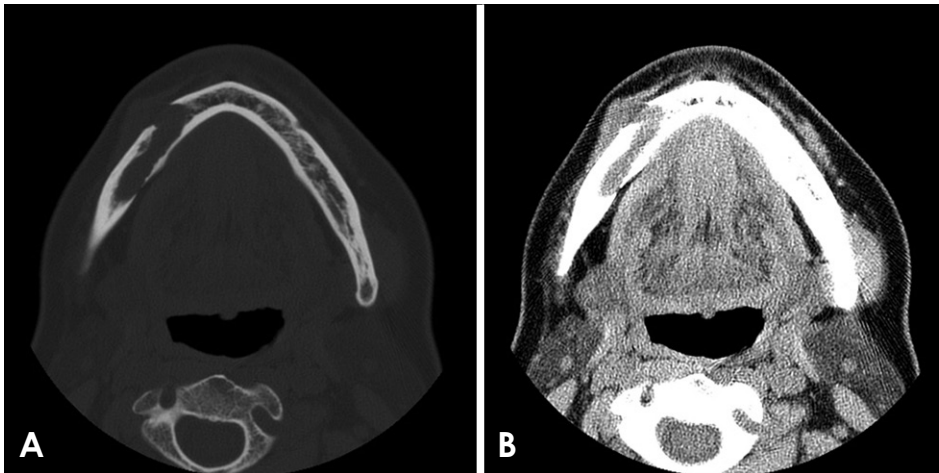


Fig. 3. A. A computed tomographic image reveals osteolytic destruction by an expansile, 2.0 cm × 1.2 cm soft-tissue mass involving the outer cortex of the right mandibular body. B. The lesion is shown on the soft-tissue computed tomographic image.

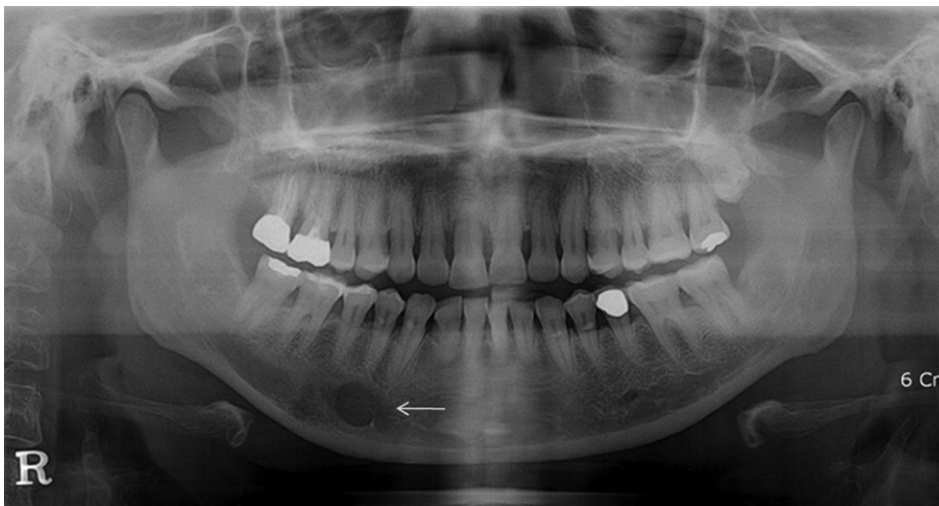


Fig. 4. A panoramic radiograph shows an osteolytic lesion in the right premolar area (arrow).

Discussion

The oral cavity is a very unusual metastasis site. Oral metastasis is usually evidence of widespread disease, and the actual incidence is difficult to determine with precision, since an unknown number of patients die without a workup for oral metastasis. The known cases of oral metastasis involve patients who show oral symptoms while living. Therefore, metastatic cholangiocarcinoma to the mandible is rare because metastatic spread to other vital organs prior to the mandible results in a low survival rate.

However, the number of case reports of metastatic cholangiocarcinoma in the oral and maxillofacial region is increasing worldwide due to improvements in the treatment of malignant tumors and the average patient survival time. Watts¹² reported a case of cholangiocarcinoma of the right subcondyle, which showed a “hotspot” in a bone scan and the loss of definition of the sigmoid notch of the mandible

in a panoramic view. Harding-Kaba et al.¹¹ reported a case of cholangiocarcinoma where the patient presented with a painful cheek swelling that was found to be an osteolytic lesion of the lower jaw. Patrocínio et al.¹³ reported a cholangiocarcinoma that presented as trismus due to metastasis to the parotid gland, and was clearly separated from other structures by a capsule. McClure et al.⁷ described a single case of left mandibular condyle metastasis from a cholangiocarcinoma in a 15-year retrospective study of metastatic maxillofacial cancer, but no further information was presented about the cholangiocarcinoma patient. The most recent case, reported by Nakanishi et al.,¹⁴ involved metastasis of a cholangiocarcinoma to the oral floor contiguous with the lingual mucosa. However, their report contained no description of mandibular metastasis (Table 1).

In our case, osteolytic destruction and a soft-tissue mass involving the outer cortex of the right mandibular body

Table 1. Previous cases of metastatic cholangiocarcinoma in the oral and maxillofacial region.

Author(s)	Patient's age (years)/gender	Metastatic site	Radiographic features
Watts (1979) ¹²	39/Male	Right condyle	Hotspot in bone scan and osteolytic mandible
Harding-Kaba et al. (2008) ¹¹	64/Female	Right mandible	Osteolytic lesion of the lower jaw
Patrocinio et al. (2008) ¹³	29/Female	Parotid gland	Separated from other structures by a capsule
McClure et al. (2012) ⁷	45/Male	Left condyle	No description
Nakanishi et al. (2014) ¹⁴	77/Female	Oral floor	No description

were observed, whereas lower-lip paresthesia, gingival lesions, and tooth mobility were not noted, although an osteolytic lesion was close to the mental foramen and premolar teeth. A whole-body bone scan that was performed on the patient's first visit to Yonsei Medical Center did not show hot uptake in the right mandible, but mild hyper metabolism was found in a whole-body PET/CT scan performed one month after radiation therapy of the mandible.

A whole-body bone scan was performed on the patient's first visit to Yonsei Medical Center, more than one year before the incidence of mandibular swelling. We therefore suspected that no mandibular metastasis had taken place when the whole-body bone scan was taken, although it is possible that the whole-body bone scan did not detect the mandibular metastasis.

The radiographic features of bone metastasis are characterized as osteolytic, osteoblastic, or mixed.¹⁵ Although most metastatic bony lesions are osteolytic, metastatic tumors from the prostate, lung, and breast are very often found to be osteoblastic.¹⁶ Tumors originating from the gastrointestinal tract and breast often appear as mixed-type.⁸ Bone scans are of considerable utility in detecting areas of osteoblastic activity in areas affected by trauma, infection, and arthropathy,¹⁷ but may not detect metastatic tumors that are primarily associated with bone destruction and minimal or no osteoblastic activity.^{17,18} In contrast, PET/CT has been found to show higher sensitivity than bone scans in the detection of osteolytic metastatic tumors, but lower sensitivity in detecting osteoblastic bony lesions.¹⁹ We can therefore speculate that the bone scan did not detect mandibular metastasis, whereas the PET/CT scan showed mild hypermetabolism because our patient experienced osteolytic bone destruction in the right mandible.

Although a few anatomic routes have been suggested as the metastatic pathway, the precise mechanism of oral and maxillofacial metastasis remains unclear. Metastasis from the abdomen or thorax is thought to take place through the blood vessels, mainly through Batson's vertebral and paravertebral plexus of veins, which comprises a valve-

less venous system.²⁰

In conclusion, metastatic cholangiocarcinoma to the oral cavity is rare; however, clinicians must consider it as a possibility, especially in patients with known risk factors, because the prognosis of oral metastasis is usually poor and most patients die within one year of diagnosis.²¹ Although most metastases to the oral region are noted after the diagnosis and treatment of the primary malignancy, in nearly 30% of patients with oral metastasis, an oral metastatic region is the first indication of an undiscovered malignancy at a distant site.²² Therefore, clinicians should be aware of the clinical and radiographic features of oral metastatic tumors.

Acknowledgements

This research was supported by a grant awarded to Wonse Park from the Basic Science Research Program through the National Research Foundation of Korea (NRF) funded by the Ministry of Science, ICT and Future Planning (NRF-2013R1A1A1009513).

References

- Gatto M, Alvaro D. New insights on cholangiocarcinoma. *World J Gastrointest Oncol* 2010; 2: 136-45.
- Mosconi S, Beretta GD, Labianca R, Zampino MG, Gatta G, Heinemann V. Cholangiocarcinoma. *Crit Rev Oncol Hematol* 2009; 69: 259-70.
- Patel T. Cholangiocarcinoma - controversies and challenges. *Nat Rev Gastroenterol Hepatol* 2011; 8: 189-200.
- Hirshberg A, Shnaiderman-Shapiro A, Kaplan I, Berger R. Metastatic tumours to the oral cavity - pathogenesis and analysis of 673 cases. *Oral Oncol* 2008; 44: 743-52.
- van der Waal RI, Buter J, van der Waal I. Oral metastases: report of 24 cases. *Br J Oral Maxillofac Surg* 2003; 41: 3-6.
- Lim SY, Kim SA, Ahn SG, Kim HK, Kim SG, Hwang HK, et al. Metastatic tumours to the jaws and oral soft tissues: a retrospective analysis of 41 Korean patients. *Int J Oral Maxillofac Surg* 2006; 35: 412-5.
- McClure SA, Movahed R, Salama A, Ord RA. Maxillofacial metastases: a retrospective review of one institution's 15-year experience. *J Oral Maxillofac Surg* 2013; 71: 178-88.

8. Heindel W, Gübitz R, Vieth V, Weckesser M, Schober O, Schäfers M. The diagnostic imaging of bone metastases. *Dtsch Arztebl Int* 2014; 111: 741-7.
9. Daley T, Darling MR. Metastases to the mouth and jaws: a contemporary Canadian experience. *J Can Dent Assoc* 2011; 77: b67.
10. Shin SJ, Roh JL, Choi SH, Nam SY, Kim SY, Kim SB, et al. Metastatic carcinomas to the oral cavity and oropharynx. *Korean J Pathol* 2012; 46: 266-71.
11. Harding-Kaba MB, Delaval C, Lakouichmi M, Jammet P, Goudot P, Yachouh J. Maxillofacial metastasis of a cholangiocarcinoma. *Rev Stomatol Chir Maxillofac* 2008; 109: 51-2.
12. Watts PG. Secondary cholangiocarcinoma in the mandible. *Br Dent J* 1979; 146: 385-6.
13. Patrocínio LG, Patrocínio TG, Pacheco LF, Patrocínio JA. Trismus as the first manifestation of cholangiocarcinoma. *Med Oral Patol Oral Cir Bucal* 2008; 13: E573-5.
14. Nakanishi Y, Xu B, LeVeal C. Oral floor and gingival metastasis of cholangiocarcinoma: a case report and review of the literature. *Case Rep Pathol* 2014; 2014: 712912.
15. Uchiyama Y, Murakami S, Kakimoto N, Nakatani A, Kishino M, Hamab Y, et al. Diagnostic imaging findings for mandibular metastasis from gastric adenocarcinoma. *Oral Surg Oral Med Oral Pathol Oral Radiol Endod* 2009; 107: e49-53.
16. Zachariades N, Koumoura F, Vairaktaris E, Mezitis M. Metastatic tumors to the jaws: a report of seven cases. *J Oral Maxillofac Surg* 1989; 47: 991-6.
17. Liu NB, Zhu L, Li MH, Sun XR, Hu M, Huo ZW, et al. Diagnostic value of 18F-FDG PET/CT in comparison to bone scintigraphy, CT and 18F-FDG PET for the detection of bone metastasis. *Asian Pac J Cancer Prev* 2013; 14: 3647-52.
18. Zhang L, Chen L, Xie Q, Zhang Y, Cheng L, Li H, et al. A comparative study of 18F-fluorodeoxyglucose positron emission tomography/computed tomography and (99m)Tc-MDP whole-body bone scanning for imaging osteolytic bone metastases. *BMC Med Imaging* 2015; 15: 7.
19. Uchida K, Nakajima H, Miyazaki T, Tsuchida T, Hirai T, Sugita D, et al. (18)F-FDG PET/CT for diagnosis of osteosclerotic and osteolytic vertebral metastatic lesions: comparison with bone scintigraphy. *Asian Spine J* 2013; 7: 96-103.
20. Batson OV. The function of the vertebral veins and their role in the spread of metastases. 1940. *Clin Orthop Relat Res* 1995; 312: 4-9.
21. Zachariades N. Neoplasms metastatic to the mouth, jaws and surrounding tissues. *J Craniomaxillofac Surg* 1989; 17: 283-90.
22. Hirshberg A, Buchner A. Metastatic tumours to the oral region. An overview. *Eur J Cancer B Oral Oncol* 1995; 31B: 355-60.