

Clinical Outcomes of 48 Pet Ferrets with Adrenal Disease

Ji-Won Jung*, Young-min Choi*, Hun-young Yoon and Soon-wuk Jeong¹

Department of Veterinary Surgery, College of Veterinary Medicine, Konkuk University
*Woosung Animal Medical Center

(Accepted: September 29, 2014)

Abstract : Medical records of 48 pet ferrets that underwent adrenalectomy were retrospectively reviewed to investigate the frequency and clinical outcomes of adrenal diseases in pet ferrets. These diseases were most commonly diagnosed in ferrets aged 3 to 5 years and in neutered females (58.3%). Adrenal disease occurred most frequently in the left adrenal gland (72.9%), followed by involvement of both adrenal glands (16.7%) and the right adrenal gland (10.4%). The mean sizes (length * thickness) of the adrenal glands as determined by ultrasonography were 8.96 * 5.08 mm and 12.91 * 8.26 mm for the left and right adrenal glands, respectively. In the ferrets with adrenal disease, alopecia (82.2%) was the main presenting clinical signs in both sexes, and vulvar swelling was seen in 32.1% of the females with adrenal disease. The common incidental findings included renal cysts (29.2%) and splenomegaly (25.0%). Histological findings showed pheochromocytoma, adenoma, and hyperplasia in 44.7%, 14.9%, and 12.8% of cases, respectively. The survival rates at 1- and 2- years after surgery were 87.5% and 74.0%, respectively. Alopecia and vulvar swelling improved within an average of 3.4 months and 12 days after surgery.

Key words : Ferret, adrenal disease, adrenalectomy.

Introduction

Adrenal disease in ferrets is a typical illness, which is readily recognized compared to other illnesses, as it is accompanied by alopecia and sexual changes (1,5,10).

Although it is known that many pet ferrets are treated for adrenal disease (6,7,9), no domestic reports on adrenal disease in ferret exist to date.

The purpose of this study was to evaluate pet ferrets that developed adrenal disease and were treated surgically in order to characterize the clinical features of adrenal disease, including age at onset, gender, clinical signs, location of affected glands, ultrasonographic estimated size and actual size, histological diagnosis, incidental findings, and outcome following adrenalectomy.

Materials and Methods

The present study included 48 pet ferrets with adrenal disease that were treated with surgery at Woosung Animal Medical Center (Woosung AMC) between 2008 and 2013. Adrenal disease was confirmed by histological views. Information collected for each ferret included data on signalments, clinical signs, ultrasonographic views, intraoperative and histologic findings, and survival.

Hematologic examination

Blood was collected from jugular vein and blood urea nitrogen (BUN) and creatinine were measured preoperatively

by automatic blood analyzer (VetScan VS2 chemistry analyzer, USA)

Ultrasonography

Ultrasonography was performed using the ACUSON Sequoia™ C512 ultrasonography system (Siemens Healthcare) with an 8-15-MHz ultrasonography probe. Ferrets were placed in dorsal recumbency for examination and were anesthetized with isoflurane only if calibration was difficult. Both glands were examined through the longitudinal plane first, and the left adrenal gland was evaluated before the right adrenal gland. Sizes were confirmed by turning the probe in small increments until the adrenal gland reached the maximal size. For the left adrenal gland, the front of the kidney was moved to the center, and the gland was examined while the probe was moved gradually towards the caudal vena cava. For the right adrenal gland, the probe was moved medially to confirm the caudate lobe of the liver and the caudal vena cava, and the right gland was located towards the dorsal plane of the caudal vena cava. Length, thickness, shape, echotexture (homogeneous, heterogeneous, cystic, and mineralized), and echogenicity were evaluated for each gland.

Surgical Procedure

Ferrets were fasted for 4-5 hours prior to the surgery. A 24-gauge IV catheter was inserted into the cephalic vein and hydration was maintained with 0.9% NaCl. Ferrets were pre-treated with antibiotics and atropine (0.05 mg/kg). Anesthesia was induced with 4-5% isoflurane, and maintained with 2-3% isoflurane.

One of the most important considerations during surgery is maintenance of body temperature. Therefore, a warm water

¹Corresponding author.
E-mail : swjeong@konkuk.ac.kr

circulator was used to sustain body temperature. Heart rate and body temperature were continuously monitored throughout the surgery.

Ferrets were placed in dorsal recumbency for the surgery, and a wide region from the xyphoid to the pubis was prepared. The surgical area was disinfected with chlorhexidine or providone. A ventral midline incision 8-10 cm in length was made starting from 1-2 cm behind the xyphoid. A number 15 scalpel blade was used for the skin incision. A cautionary point to note when making the skin incision is that the linea alba is opaque but thin. In some cases with splenomegaly, the spleen is attached directly below the linea alba, and it can easily be damaged during incision. After exposing the abdominal cavity with a Gelpi self-retaining retractor, a general examination of the spleen, intestines, and other abdominal organs was performed. Sizes and changes in the exterior appearance of the spleen and nodules in the pancreas were examined. Males were examined for the presence of paraurethral cysts. After evaluation, the spleen, intestines, and other organs were exposed outwards and kept hydrated with gauze.

Left Adrenalectomy

The left adrenal gland is located anteriorly and medially from the left kidney, and covered with retroperitoneal fat. In its normal state, it can be difficult to locate because it is covered with fat, but if it is enlarged and altered in shape, it becomes easier to locate. The left adrenal gland was exposed using mosquito hemostats or cotton tips to carefully separate it from the overlying fatty tissue. A hemostatic clip was used to ligate the adrenolumbar vein, which emerges from the caudal vena cava and connects to the ventral surface of the left adrenal gland. The vein that is connected dorsally was also ligated. Occasionally, if the adrenal gland is enlarged markedly, its removal may create dead space, and slight bleeding from the fat may occur. Either overall ligation or gel foam was used to achieve hemostasis in the fatty tissue. The linea alba was sutured in a simple continuous pattern using 3-0 sutures. The subcutaneous tissue layer was sutured with a simple continuous pattern, and the skin was sutured with a simple interrupted pattern using 3-0 or 4-0 sutures.

Right Adrenalectomy

For right adrenalectomy, the surgical incision was extended further than it was for left adrenalectomy because removal of the right adrenal gland is comparatively more difficult. The spleen, intestines, and other organs were retracted to the left to facilitate adequate exposure. The right adrenal gland was located on the right dorsal surface of the caudal vena cava below the caudate lobe of the liver. The caudal vena cava was exposed by separating the hepatorenal ligament from the right kidney and pulling the caudate lobe of the liver forward. Caution is required at this point, in order to avoid lacerating the liver or caudal vena cava. These structures were carefully separated by approaching from the outer surface of the adrenal gland. Sharp iris scissors, micro scissors, mosquito hemostats, or cotton tips were used to achieve separation. Moving forward with separation from structures surrounding the adrenal gland, the point of attachment of the caudal vena cava was located. At this point, the caudal vena cava was

separated from the right adrenal gland using hemostatic clips for ligation. If laceration of the caudal vena cava inadvertently occurred during the surgery, the laceration was repaired with 5-0 and 7-0 sutures, and a satinsky vena cava clamp was used. If separation was difficult due to strong attachment to the caudal vena cava, an intracapsular technique was used, where only adrenal gland tissues are removed by cutting the capsule surrounding the adrenal gland. The surgical incision was closed using the same process previously described for left adrenalectomy.

Postoperative Care

Ferrets were hospitalized after surgery to ensure the maintenance of adequate hydration and body temperature. Cephalixin (25 mg/kg) was intravenously injected twice a day. Dexamethasone (1 mg/kg) was intravenously injected post-surgery, and prednisolone (0.5 mg/kg) was subcutaneously injected twice a day from the second day after surgery. Where only one adrenal gland had been removed, the twice daily injections were continued for 10 days and then sequentially reduced to once a day, once every two days, and once every three days prior to discontinuation. However, where both adrenal glands were removed, life long administration was continued once every three days. Ferrets were offered food 6 hours after the surgery and were discharged 10-14 days after the surgery.

Histopathological Examination

Adrenal glands were fixed in 10% formalin and histopathologically examined at the Neodin Veterinary Science Institute.

Statistical analysis

Data were analyzed using the paired *t*-test (adrenal gland size), and Kaplan-Meier method (survival). A *p* value of < 0.05 was considered statistically.

Results

The mean age of ferrets presenting with adrenal disease was approximately 3 years and 9 months. The most frequently reported ages at presentation were above 3 years but below 4 years (*n* = 12), and above 4 years but below 5 years (*n* = 12), with each of these age ranges accounting for 26.7% of the ferrets in this study. Twenty-eight (58.3%) were neutered females, and 20 (41.7%) were neutered males.

On Ultrasonographic views, thirty-five (72.9%) exhibited disease of the left adrenal gland only, and 5 (10.4%) exhibited disease of the right adrenal gland only. Eight ferrets (12.5%) exhibited disease of both the left and right adrenal glands.

Adrenal gland sizes as estimated by ultrasonography were compared with the actual gland sizes measured after surgical removal (Table 1). According to the estimates derived from ultrasonography, the mean length x thickness of left and right adrenal gland was 8.96 mm * 5.08 mm and 12.91 mm * 8.26 mm, respectively. In comparison, that of the left and right adrenal glands after adrenalectomy was 9.23 mm * 6.02 mm and 16.16 mm * 13.5 mm, respectively. For both left and right adrenal glands, the sizes of the glands after adrenalectomy were slightly larger than ultrasonography based estimates.

Table 1. Comparison of adrenal gland (AD) sizes as estimated from measurements taken during ultrasonography before surgery, and actual sizes as measured after adrenalectomy

	Left AD (mm)				Right AD (mm)			
	Ultrasonographic dimension (n = 28)		Actual dimension (n = 21)		Ultrasonographic dimension (n = 13)		Actual dimension (n = 6)	
	Length	Thickness	Length	Thickness	Length	Thickness	Length	Thickness
Mean	8.96	5.08	9.23	6.02	12.91	8.26	16.16	13.5
(Min-Max)	(6.0-19.8)	(3.0-11.5)	(4.0-23)	(2.0-12.0)	(6.0-65.0)	(3.0-45.0)	(7.0-55.0)	(3.0-54.0)
Reference range*	4.0-8.1	1.8-3.9	6.0-8.0	2.0-3.0	4.9-10.6	1.3-3.7	6.0-8.0	2.0-3.0

*Reference ranges (2,12).

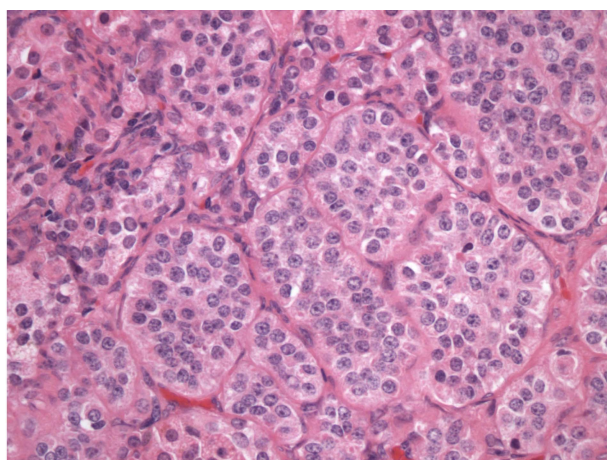


Fig 1. Histological appearance of pheochromocytoma (Hematoxylin & Eosin staining, × 400). Pheochromocytoma is arranged in nest or pocket pattern, separated by fibrovascular septa. Neoplastic cells show polygonal shape, eosinophilic granular cytoplasm, and oval to round nucleus. Nuclei showing the characteristic stippled chromatin.

Alopecia was the most common clinical sign, with 37 of the 45 symptomatic ferrets (82.2%). Vulvar swelling was evident in 9 of 28 (32.1%) of the female ferrets. Loss of appetite was reported in 15.6% of ferrets. Weight loss, diarrhea, vomiting, an abdominal mass, and dysuria were each found in 2 or fewer ferrets.

Histopathology results were obtained for 47 of these 56 diseased adrenal glands. The most common histological observation was pheochromocytoma (Fig 1), which was evident in 21 adrenal glands. Other histological diagnoses were adenoma (7), hyperplasia (6), adrenitis (5), lymphoma (3), adrenal hemorrhage (3), carcinoma (1), and adrenal infarction (1).

Incidental findings were detected in 26 of the 48 ferrets (54.2%) with adrenal disease. A total of 22 ferrets showed signs of kidney disorder, and renal cysts (14) were the most common abnormality. Crystals on ultrasonographic views were found within the urinary bladder (6), and renal failure occurred in two cases (Case 1, BUN 180 mg/dl, Creatinine 3.5 mg/dl; Case 2, BUN 56 mg/dl, Creatinine 2.1 mg/dl; Reference range, BUN 18~32 mg/dl, Creatinine 0.2~0.5 mg/dl). Splenomegaly was identified in 12 ferrets. Hairball in the stomach, lymphoma, and peritonitis were each confirmed in 1 ferret.

Of the 37 ferrets that exhibited alopecia prior to surgery,

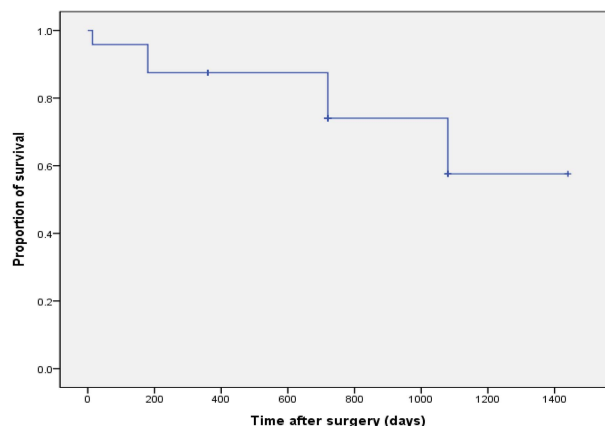


Fig 2. Kaplan-Meier survival curve of ferrets surgically treated for adrenal diseases.

after surgery the condition improved in 11, did not improve in 7, and was unconfirmed in 19 ferrets. Among the 11 ferrets with noted improvement, the shortest time from surgery to improvement was within 1 month, the longest was 6 months, on average, the alopecia improved within 3.4 months. Among the 9 females with vulvar swelling, resolution of reproductive organ edema was confirmed in 7 ferrets, and unconfirmed in 2 ferrets.

The 1- and 2- year survival rates were 87.5% and 74.0% respectively (Fig 2). The longest recorded survival time was reported for a ferret that remained alive 47 months after the initial adrenalectomy. This ferret underwent an operation on other side 37 months after the first operation.

Discussion

Adrenal disease occurrence rates reportedly range from 0.55-25.0% (1,10,13). Neutering at an early age is believed to be a primary cause of adrenal disease (5,6). The adrenal disease occurrence rate in Germany was 0.55% (10,11). Most pet ferrets in Korea are imported from the United States after being neutered at an early age, and are raised in conditions similar to those in the United States ; they are typically fed with food imported from the United States. The situation is different in Europe, where neutering is not common and the feed is different; it seems that tumor related diseases occur more often in ferrets in the United States, and adrenal diseases are the most common.

In the present study, the occurrence of the disease in the left adrenal gland was approximately seven times higher than in the right adrenal gland. The reason for this predilection towards the left adrenal gland is unknown. However, the difference may be due to anatomical or physiological factors. Because the right adrenal gland is attached to the caudal vena cava, confirmation of diseases affecting it, and the surgical approaches to treatment, are more difficult compared to the left adrenal gland (3,7,13,14).

The present study used a thickness of 3.9 mm as the diagnostic standard when performing the ultrasonography examination (3,4,8,10,12). However, 8 of 28 ferrets showed lower values, but surgical treatment was utilized due to the presence of definitive clinical signs such as alopecia and vulvar swelling in these ferrets. Potential adrenal disease in ferrets can be diagnosed based on clinical signs. Ultrasonography can be used to confirm the diagnosis, and it is also useful for establishing surgical plans. Moreover, full recovery is possible after surgical treatment.

In the present study, pheochromocytoma was diagnosed in 21 ferrets, representing a rate of 44.7%. This is not concordant with previous reports that most adrenal diseases were hyperplasia, adenoma, and adenocarcinoma (1,4,7,13,14), however it is concordant with one report in which pheochromocytomas accounted for 30-80% of diagnoses (8).

It has been reported that insulinoma and splenomegaly are the most common concurrent diseases (7,10). Renal cysts and splenomegaly were common in the present study and they were mostly incidental findings, rather than contributing to the illness directly.

In a previous study, the timing of alopecia improvement post-surgery varied from a few weeks to a few months, while vulvar swelling among females resolved within 14 days (2). Similarly in the present study, at least 1 month passed before there was any improvement in alopecia, and the average improvement time was 3.4 months. Most vulvar swelling in females had resolved by the time of discharge (10-14 days).

It has been reported that following removal of one adrenal gland, the adrenal disease occurrence rate on the opposite side was 17%, and despite bilateral adrenalectomy, incomplete removal resulted in recurrence 7-22 months post-surgery, at a rate of 15% (14). Other reports have shown that symptoms appeared 3-14 months after surgery, at a reported rate of 17% (1,2). Twelve of the 48 ferrets in the current study showed no signs of improvement due to development of disease in the opposite gland or due to recurrence after a few months; a rate of 25%. It took from 7 months to 40 months for the opposite side to develop disease after signs improved. Complete removal and histological diagnosis did not result in a difference in survival rates (13).

The most common postoperative complications are hypogly-

cemia and hypothermia (3). With right adrenalectomy, acute renal failure occurs in cases of excessive bleeding due to caudal vena cava laceration or caudal vena cava ligation (2). Metastasis to other organs due to malignancy is reported to be rare (2). Hypoglycemia and hypothermia did not cause issues in the present study, but postoperative renal failure did occur in some cases. With regard to malignant tumor diagnosis, metastasis to other organs was not confirmed.

The present study focused on adrenal disease in ferrets with adrenalectomy. However, further research investigating other tumor-related diseases in ferrets is necessary.

References

1. Bailey DB, Page RL. Tumors of Endocrine System. In: Small Animal Clinical Oncology. 4th ed. St. Louis: Saunders. 2007: 589-590.
2. Bartlett LW. Ferret soft tissue surgery. *Sem Avn Exo Med* 2002; 11: 221-230.
3. Beeber N. Surgical management of adrenal tumors and insulinomas in ferrets. *J Exo Med* 2011; 20: 206-216.
4. Besso JG, Tidwell AS, Gliatto JM. Retrospective review of the ultrasonographic features of adrenal lesions in 21 ferrets. *Vet Radiol Ultrasound* 2000; 41: 345-352.
5. Eatwell K. Two unusual tumors in a ferret (*Mustela putorius furo*). *J Small Anim Pract* 2004; 45: 454-459.
6. Miwa Y, Kurosawa A, Ogawa H, Nakayama H, Sasai H. Neoplastic diseases in ferrets in Japan: a questionnaire study for 2000 to 2005. *J Vet Med Sci* 2009; 71: 397-402.
7. Miwa Y, Nakata M, Kurosawa A, Sasai H, Sasaki N. Adrenal diseases in ferrets in Japan. *J Vet Med Sci* 2008; 70: 1323-1326.
8. Neuwirth L, Isaza R, Bellah J. Adrenal neoplasia in seven ferrets. *Vet Radiol Ultrasound* 1993; 34: 340-346.
9. Rosenthal KL, Wyre NR. Endocrine diseases. In: *Ferrets, Rabbits, and Rodents Clinical Medicine and Surgery*. 2nd ed. St. Louis: Saunders. 2012: 86-91
10. Shoemaker NJ. Ferrets: endocrine and neoplastic diseases. In: *BSAVA Manual of Rodents and Ferrets*. Gloucester: BSAVA. 2009: 320-324.
11. Shoemaker NJ, Schuurmans M, Moorman H, Lumeij JT. Correlation between age at neutering and age at onset of hyperadrenocorticism in ferrets. *J Am Vet Med Assoc* 2000; 216: 195-197.
12. Shoemaker NJ, Voorhout G. Ultrasonographic visualization of the adrenal glands of healthy ferrets and ferrets with hyperadrenocorticism. *J Am Anim Hosp Assoc* 2007; 43: 78-84.
13. Swiderski K, Seim H, MacPhail C. Long term outcome of domestic ferrets treated surgically for hyperadrenocorticism: 130 cases (1995-2004). *J Am Vet Med Assoc* 2008; 232: 1338-1343.
14. Wolf TM. Ferrets. In: *Manual of Exotic Pet Practice*. St. Louis: Saunders. 2009: 362-364.

부신질환을 지닌 애완 페렛 48마리의 임상적 결과

정지원* · 최영민* · 윤현영 · 정순욱¹

건국대학교 수의과대학, *우성동물메디컬센터

요 약 : 애완 페렛의 부신질환은 우리 나라에서도 많이 접하게 되는 질병이다. 하지만 아직 페렛의 부신질환에 대한 연구가 우리나라에서는 이뤄지지 않고 그 실태 보고도 없는 상태이다. 그러므로 본 연구는 부신절제술을 실시한 48마리의 페렛을 대상으로 국내 애완 페렛의 부신질환 발생상황을 알아보고자 하였다. 부신 질환이 있는 애완 페렛은 주로 3~5년령에 다발하였으며, 중성화된 암컷에서 58.3%의 높은 발생을 보였다. 부신질환은 왼쪽 부신 72.9%, 오른쪽 부신 10.4%, 양쪽 부신에 16.7% 있었으며, 초음파상에서 부신크기(길이 * 두께)는 왼쪽 부신 8.96 * 5.08 mm, 오른쪽 부신 12.91 * 8.26 mm 로 나타났다. Alopecia가 82.2%로 주요 임상증상이었고 vulvar swelling은 암컷중 32.1%에서 나타났다. 주된 병발질환으로 renal cyst 29.2%, splenomegaly 25%를 보였다. 조직학적 소견에서 pheochromocytoma, adenoma, hyperplasia 가 각각 44.7%, 14.9%, 12.8% 이었다. 수술후 생존률은 1년과 2년에서 각각 87.5%, 74.0% 였으며, alopecia 및 vulvar swelling은 각각 수술후 평균 3.4개월 및 평균 12일경에 개선되었다.

주요어 : 페렛, 부신질환, 부신절제술