

Case report

J Korean Soc Pediatr Nephrol 2014;18:111-115
DOI: <http://dx.doi.org/10.3339/jkspn.2014.18.2.111>

ISSN 1226-5292 (print)
ISSN 2234-4209 (online)

급성신우신염으로 입원 후 지속적인 고칼륨혈증과 정상 혈중 알도스테론 수치를 보인 25일 영아 1례

차의과대학교 분당차병원 소아청소년과
강유선 · 최지연 · 이준호

Yu Sun Kang, M.D.,
Ji Yeon Choi, M.D.,
and Jun Ho Lee, M.D.

Department of Pediatrics, CHA Bundang Medical Center, CHA University School of Medicine, Seongnam, KOREA

Corresponding Author: Jun Ho Lee, M.D.
Department of Pediatrics, CHA Bundang Medical Center, CHA University School of Medicine, Seongnam, KOREA
Tel: +82-31-780-5011, Fax: +82-31-780-6262
E-mail: naesusana@yahoo.co.kr

Received: 24 August 2014
Revised: 1 October 2014
Accepted: 1 October 2014

Management of a 25-day-old Male Presenting with a First Episode of Acute Pyelonephritis, and Persistent Hyperkalemia with Normal Serum Aldosterone

Hyperkalemia is often detected in young infants, particularly in association with acute pyelonephritis or a urinary tract anomaly. Cases of hyperkalemia in this population may also be due to transient pseudohypoaldosteronism, or immaturity of renal tubules in handling potassium excretion. Symptoms of hyperkalemia are non-specific, but are predominantly related to skeletal or cardiac muscle dysfunction, and can be fatal. Therefore, treatment has to be initiated immediately. Administration of fludrocortisone for hyperkalemia is appropriate in cases with hypoaldosteronism, but is challenging in young infants with hyperkalemia due to renal tubular immaturity, without pseudohypoaldosteronism. We report the case of a 25-day-old male presenting with persistent hyperkalemia with normal serum aldosterone, who was admitted with a first episode of pyelonephritis and unilateral high-grade vesicoureteral reflux. The patient was treated successfully with fludrocortisone.

Key words: Fludrocortisone, Hyperkalemia, Infant, Pyelonephritis, Vesicoureteral reflux

This is an open-access article distributed under the terms of the Creative Commons Attribution Non-Commercial License (<http://creativecommons.org/licenses/bync/3.0/>) which permits unrestricted non-commercial use, distribution, and reproduction in any medium, provided the original work is properly cited.

Introduction

Cases of secondary pseudohypoaldosteronism (PHA) in infants have been reported, and are most often associated with acute pyelonephritis (APN), or a urinary tract anomaly (UTA) with obstructive uropathy, or vesicoureteral reflux (VUR) [1-3]. Infants have immature renal tubules, such that APN or a UTA can result in a state of renal tubular unrespon-

siveness to aldosterone. This is manifested by hyponatremia, hyperkalemia, metabolic acidosis, high urinary excretion of sodium, and low urinary excretion of potassium, accompanied with an increased serum aldosterone level [4]. Early diagnosis and treatment of hyperkalemia in infants, defined as plasma potassium in excess of 5.5 mmol/L, is difficult but essential, because while the associated symptoms are non-specific, its complications, such as dysrhythmia, can be fatal. Fludrocortisone should be promptly administered for the treatment of hyperkalemia with hypoaldosteronism, but is challenging in young infants in whom immaturity of renal tubular potassium metabolism can result in hyperkalemia without PHA.

We report the case of a 25-day-old male, who presented with persistent hyperkalemia with normal serum aldosterone. The patient was admitted with a first episode of APN and unilateral high-grade VUR, and was treated successfully with fludrocortisone.

Case report

A 25-day-old male infant was admitted to our hospital with a high fever of 1 day duration. He was diagnosed with APN and sepsis, and treatment was initiated. The infant had been delivered vaginally at 38⁺⁰ weeks gestation,

weighing 3,040 grams at birth. There was no perinatal complication. Maternal medical history, obstetric history, family history, and neonatal screening tests were unremarkable. The patient's prenatal sonogram was normal.

On admission, blood pressure was 80/50 mmHg, heart rate 167 bpm, respiratory rate 40/min and body temperature 39.3°C. His weight was 4.2 kg (3rd-5th percentile) and his length was 60 cm (75th-90th percentile). On physical examination, he appeared ill, but there was no other remarkable finding. Laboratory findings at admission were as follows hemoglobin 10.6 g/dL; white blood cell count 13,360/mm³, platelets 505,000/mm³, C-reactive protein 2.39 mg/dL, total protein 5.3 g/dL, albumin 3.8 g/dL, BUN/creatinine 11.6/0.5 mg/dL, uric acid 2.5 mg/dL, total bilirubin 1.21 mg/dL, AST 17 IU/L, ALT 13 IU/L. Serum electrolyte values are shown in Table 1. His serum osmolality was 307 mOsm/kg, and venous pH was 7.435 (PCO₂ 26.3, PO₂ 98.6 HCO₃⁻ 17.3, base excess -6 mmol/L). Urinalysis showed a pH of 6.5 and a specific gravity of 1.015. The urine was positive for nitrites (+) and leukocyte esterase (2+), white blood cells were abundant (31-50/high power field). Urine was negative for protein, glucose, and occult blood. Urinary electrolytes were deranged (Table 1), and the transtubularpotassium gradient (TTKG) was low, fractional excretion of sodium (FeNa) was 0.01 (1%). However, plasma renin activity (PRA) 10.57 ng/mL/

Table 1. Descriptive Data and Biochemical Values in Blood and Urine Over Time

Hospital days (HD)*	Number of admission							
	1st		2nd		3rd		4th	
	HD1	HD 4	HD 11	HD 12	HD 18	HD 32	HD 47	HD 51
WBC (/uL)	13,360	12,190	12,680	7,380	3,980	18,090	18,130	12,240
Platelet (10 ³ /uL)	505	385	370	373	501	490	501	469
Serum BUN (mg/dL)	11.6		4.3		10.2	9.8	14	11.1
Serum Creatinine (mg/dL)	0.5		0.5		0.4	0.5	0.5	0.4
Serum Na ⁺ (mEq/dL)	139	140	140	143	138	137	137	137
Serum K ⁺ (mEq/dL)	6.3	7.0	6.4	6.2	5.4	5.2	5.3	5.0
Serum Cl ⁻ (mEq/dL)	103	104	103	105	103	103	103	103
Total CO ₂ (mEq/dL)	12.9	21.2	21.2	19.2	17.6	23.0	19.6	21.4
Urine Creatinine (mg/dL)	6.8	14	7	7.7	14	11.8	21.9	12.9
Urine Na ⁺ (mEq/dL)	21	95	29	51	41	30	43	22
Urine K ⁺ (mEq/dL)	16.1	31.6	17.1	13.8	27.4	30.1	53.8	37.1
Urine Cl ⁻ (mEq/dL)	18	77	30	27	37	33	49	31
Urine Osm/Serum Osm	1.3		0.4		0.7		1.0	
TTKG	2.0		6.3		7.6		9.7	

*Hospital day counted from the date of the first admission.

h (2.0–35.0 ng/mL/h) and serum aldosterone 90d, 6 ng/dL (5.0–132 ng/dL) were in the normal range. An electrocardiogram indicated that the patient was in normal sinus rhythm. Renal sonogram showed atrophy of the right kidney (3.1 cm pole-to-pole) and mild hydronephrosis (Society for Fetal Urology Grade 2) of the left kidney (pelvic diameter 0.6 cm) (Fig. 1a). ^{99m}Tc -dimercaptosuccinic acid (DMSA) renal scan showed a suspected focal cortical defect in the upper lateral portion of the dystrophic right kidney (relative renal uptake right: left 10.93%: 89.07%) (Fig. 1b). A voidingcystourethrogram (VCUG) showed grade V VUR in the right kidney (Fig. 1c). The results of blood culture were normal, and a single isolate of *Escherichia coli* was cultured from a urine sample collected by clean urine bag ($>10^5$ CFU/mL). Intravenous ampicillin and cefotaxime were administered at admission. Fever subsided at hospital day (HD) 2. However, the patient's discharge was delayed because of the persistent hyperkalemia, which was only temporarily responsive to standard

treatments including sodium bicarbonate (2 mEq/kg) in 0.3% dextrose saline, salbutamol inhalation, and furosemide injection (1 mEq/kg). During admission 17 α -hydroxyprogesterone (17-OHP) (11.7 ng/mL (0.22–12 ng/mL)) and cortisol 3.70 $\mu\text{g/dL}$ (2.4–22.9 $\mu\text{g/dL}$) were normal, while adrenocorticotrophic hormone (ACTH) was elevated (389.7 pg/mL (4.8–50.8 pg/mL)). An adrenal gland stimulation test performed in order to rule out secondary adrenal insufficiency was normal (Table 2). Treatment with oral fludrocortisone (Florinef 0.1 mg/day) was initiated at HD 12. The patient showed an immediate and good response, his potassium level fell, in line with the increase in urinary potassium (Table1). He was discharged successfully at HD 18. The fludrocortisone was discontinued after 5 weeks without

Table 2. ACTH Stimulation Test Results

	Cortisol ($\mu\text{g/dL}$)	17 α -hydroxyprogesterone (ng/mL)
Pre-ACTH	9.55	4.87
Post-ACTH (60 minutes)	41.97	10.16

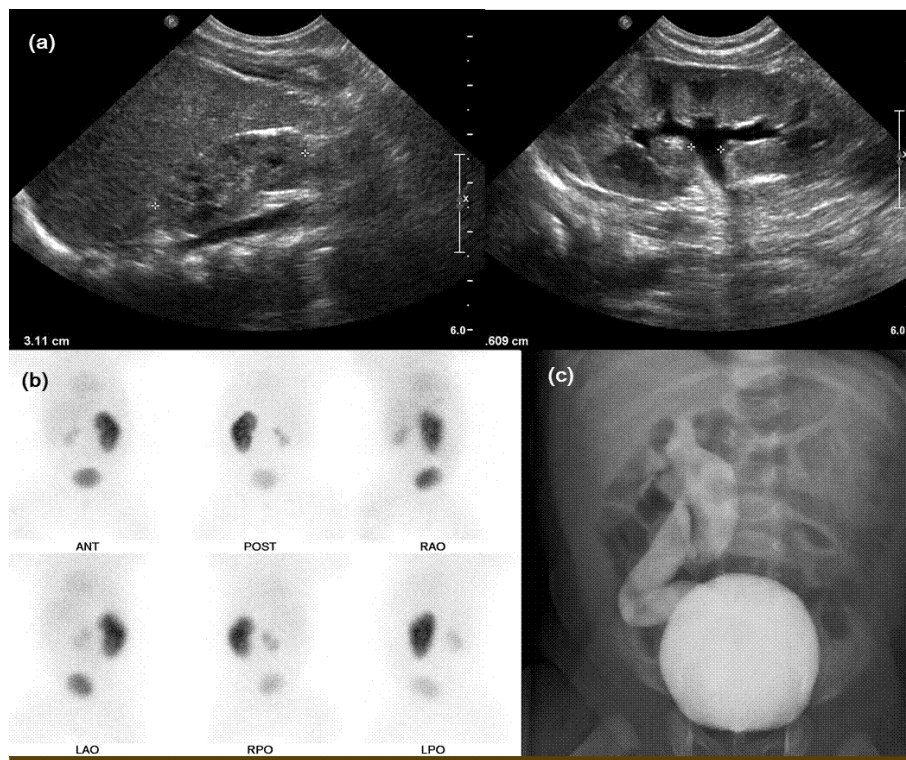


Fig. 1. (a) Renal sonogram; right kidney (atrophic) and left kidney (hydronephrosis); (b) Dysplastic right kidney on dimercaptosuccinic acid renal scan; (c) grade V vesicoureteral reflux in right kidney on voiding cystourethrogram.

any side effects. Thereafter, the patient experienced 3 further episodes of APN within 2 months, at age 60 days, 73 days, and 77 days old. Each recurrence necessitated readmission. At the age of 3 months, a neoureterocystostomy was performed. Surgical correction of VUR was not considered initially because the febrile UTI was the first episode in this early young infant, left kidney was intact on DMSA scan, and the correction of hyperkalemia was considered as preferential treatment before surgery. Recurrence of urinary tract infections (UTIs) did not recur postoperatively and to date, the patient is well with normal growth.

Discussion

The 3 major factors that contribute to tubular resistance to aldosterone are obstructive uropathy or VUR, UTI, and age [5]. Klahr suggested that ureteral obstruction or VUR leads to profound changes in renal tubular cell function. These changes include altered sodium and water handling, and a failure to dilute or concentrate the urine. Potassium exchange is also affected. Furthermore, the response of the distal tubule to hormones is impaired, which in turn leads an increased level of aldosterone [6]. Sperl et al. [7] in a retrospective study of over 300 children with APN, reported biochemical signs of aldosterone resistance (hyperkalemia and hyponatremia) in nearly 3% of the infants. This finding was not restricted to patients with a UTA. The mechanism by which metabolic imbalances arise as a result of APN is not understood. A number of studies suggest that prostaglandin, thromboxane, leukotrienes, IL-1, and endothelin, stimulated by the endotoxin of the bacteria, induce vasoconstriction. This vasoconstriction lowers glomerular filtration, and causes high urinary excretion of sodium, which results in the activation of renin-angiotensin-aldosterone system [2, 8, 9]. Melzi et al. [10] found that severe metabolic imbalances occurred only in infants younger than 3 months with a UTA and UTI. Preterm and young infants have a low tubular capacity for reabsorption of sodium and a physiologic tubular resistance to aldosterone due to

renal immaturity. This explains why derangements of electrolyte and water homeostasis occur much more easily in neonates and young infants, compared with older children [5].

Hyperkalemia is often detected when blood sampling was technically troublesome in infants or the procedure of blood sampling and its storage was not properly done. Meticulous watching the process of blood sampling and handling it in clinical laboratory through repetitive tests could make the possibility of pseudohyperkalemia be excluded in this case.

Method of measuring the appropriateness of renal K^+ excretion during disorders of serum K^+ concentration is the calculation of the transtubular K^+ concentration gradient (TTKG, $TTKG = [K^+]_{urine} / ([urine\ osmolality / blood\ osmolality] / [K^+]_{blood})$) [11]. Gil-Ruiz MA etc. [12] defined inappropriate renal response to hyperkalemia as the combination of hyperkalemia ($>5.5\text{ mmol/L}$) and a decreased TTKG of <5 . By the definition, this case showed definite inappropriate renal response to hyperkalemia.

In the present case, the patient's young age might have been a main factor contributing to the persistent hyperkalemia. We prescribed fludrocortisone in order to increase renal excretion of potassium, because the patient had a low TTKG, and was unresponsive to aldosterone.

Fludrocortisone is used in patients with hypoaldosteronism in order to maintain serum sodium and potassium balance. Fludrocortisone is a synthetic glucocorticoid, with potent mineralocorticoid activity, and moderate glucocorticoid activity. Fludrocortisone stimulates $Na^+ - K^+$ ATPase activity in the distal convoluted tubules and cortical collecting ducts of the kidney, resulting in reabsorption of sodium and secretion of potassium. In addition, potassium secretion in the gastrointestinal tract is increased [13]. The intracellular shift of potassium might also play an important role in the potassium-lowering effect. However, despite the benefits of fludrocortisone, prolonged use is associated with the development of adverse effects including hyperglycemia, adrenal suppression, growth suppression and osteoporosis [14].

The administration of fludrocortisone in the present case was challenging because, to our knowledge, there are no related reports in the literature. In conclusion, the administration of fludrocortisone was successful in the treatment of persistent hyperkalemia in a young infant without PHA who had APN accompanied with a UTI.

한글요약

요로기형 또는 급성신우신염이 있는 어린 영아에서 신세뇨관 기능 미성숙이나 일과성 가성저알도스테론혈증에 의해 고칼륨혈증이 흔하지 않게 발생할 수 있다. 고칼륨혈증은 증세가 뚜렷하지 않지만, 골격근이나 심장기능에 치명적인 영향을 줄 수 있어 즉각적인 처치를 필요로 한다. 고칼륨혈증 치료에 fludrocortisone을 적용하는 경우는 저알도스테론혈증에 해당하였으나, 혈중 알도스테론농도 변화없이 세뇨관의 칼륨 배설 기능 미성숙에 의한 고칼륨혈증에 대한 사례는 문헌고찰상 없었다. 본 증례에서는 급성신우신염으로 입원한 후 지속적인 고칼륨혈증과 정상 혈중알도스테론농도를 보인 25일 영아에서 fludrocortisone로 처치한 후 양호한 경과가 관찰되어 보고하는 바이다.

References

- 1) Kim MK, Park SE, Lee JH. Transient pseudohypoaldosteronism in an infant with vesicoureteral reflux. *Journal of the Korean Society of Pediatric Nephrology* 2012;16:54-7.
- 2) Maruyama K, Watanabe H, Onigata K. Reversible secondary pseudohypoaldosteronism due to pyelonephritis. *Pediatr Nephrol* 2002;17:1069-70.
- 3) Nandagopal R, Vaidyanathan P, Kaplowitz P. Transient pseudohypoaldosteronism due to urinary tract infection in infancy: A report of 4 cases. *Int J Pediatr Endocrinol* 2009; 2009:195728.
- 4) Geller DS. Mineralocorticoid resistance. *Clin Endocrinol* 2005; 62:513-20.
- 5) Thies KC, Boos K, Muller-Deile K, Ohrdorf W, Beushausen T, Townsend P. Ventricular flutter in a neonate--severe electrolyte imbalance caused by urinary tract infection in the presence of urinary tract malformation. *J Emerg Med* 2000; 18:47-50.
- 6) Klahr S, Pukerson ML. The pathophysiology of obstructive nephropathy: the role of vasoactive compounds in the hemodynamic and structural abnormalities of the obstructed kidney. *Am J Kidney Dis* 1994;23:219-23.
- 7) Sperl W, Guggenbichler JP, Warter T. Changes in electrolyte and acid-base equilibrium in children with acute urinary tract infections. *Pediatr Padol* 1988;23:121-8.
- 8) Bonjour JP. Interleukin-1 decreases renal sodium reabsorption: possible mechanism of endotoxin-induced natriuresis. *Am J Physiol* 1987;252:F943-F6.
- 9) Gerigk M, Glanzmann R, Rascher W, Gnehm H. Hyponatraemia and hyperkalaemia in acute pyelonephritis without urinary tract anomalies. *European Journal of Pediatrics* 1995;154: 582-4.
- 10) Melzi ML, Guez S, Sersale G, Terzi F, Secco E, Marra G, et al. Acute pyelonephritis as a cause of hyponatremia/hyperkalemia in young infants with urinary tract malformations. *The Pediatric Infectious Disease Journal* 1995;14:56-9.
- 11) West ML, Bendz O, Chen CB, Singer GG, Richardson RM, Sonnenberg H, et al. Development of a test to evaluate the transtubular potassium concentration gradient in the cortical collecting duct in vivo. *Miner Electrolyte Metab* 1986;12: 226-33.
- 12) Gil-Ruiz MA, Alcaraz AJ, Maranon RJ, Navarro N, Huidobro B, Luque A. Electrolyte disturbances in acute pyelonephritis. *Pediatr Nephrol* 2012;27:429-33.
- 13) Giebisch G. Renal potassium transport: mechanisms and regulation. *Am J Physiol* 1998;274:F817-33.
- 14) Liu D, Ahmet A, Ward L, Krishnamoorthy P, Mandelcorn ED, Leigh R, et al. A practical guide to the monitoring and management of the complications of systemic corticosteroid therapy. *Allergy Asthma Clin Immunol* 2013;9:30.