

A Case of Nonthrombotic Pulmonary Embolism after Facial Injection of Hyaluronic Acid in an Illegal Cosmetic Procedure

Jong Geol Jang, M.D., Kyung Soo Hong, M.D. and Eun Young Choi, M.D.

Division of Pulmonology and Critical Care Medicine, Department of Internal Medicine, Yeungnam University College of Medicine, Daegu, Korea

Hyaluronic acid is widely used in medical procedures, particularly in cosmetic procedures administered by physicians or nonmedical personnel. The materials used for cosmetic procedures by physicians as well as illegally by non-medical personnel can cause nonthrombotic pulmonary embolism (NTPE). We report the case of a woman with acute respiratory failure, neurologic symptoms and petechiae after an illegal procedure of hyaluronic acid dermal filler performed by an unlicensed medical practitioner 3 days before symptom onset. Although a few cases of NTPE after injection of hyaluronic acid have been reported yet, this is the first typical case showing a NTPE manifestation after the facial injection of hyaluronic acid.

Keywords: Pulmonary Embolism; Hyaluronic Acid; Cosmetics

Introduction

Hyaluronic acid is widely used in cosmetic procedures such as lip augmentation and the correction of facial wrinkles^{1,2}. Here, we report the case of 35-year-old woman who developed dyspnea 3 days after an illegal hyaluronic acid dermal injection at a hair salon. She subsequently developed a confused

mental state and petechial rash on the upper trunk, which is a typical clinical manifestation of nonthrombotic pulmonary embolism (NTPE). She was diagnosed with NTPE on the basis of her medical history and chest computed tomography (CT) results. She was fully recovered after conservative treatment. Although a few cases of NTPE after hyaluronic injection have been reported, the case with typical manifestation after facial area injection was rare.

Address for correspondence: Eun Young Choi, M.D.

Division of Pulmonology and Critical Care Medicine, Department of Internal Medicine, Yeungnam University College of Medicine, 170 Hyeonchung-ro, Nam-gu, Daegu 705-717, Korea

Phone: 82-53-640-6579, **Fax:** 82-53-623-8201

E-mail: letact@hanmail.net

Received: Apr. 17, 2014

Revised: May 19, 2014

Accepted: May 29, 2014

©It is identical to the Creative Commons Attribution Non-Commercial License (<http://creativecommons.org/licenses/by-nc/3.0/>).

Copyright © 2014

The Korean Academy of Tuberculosis and Respiratory Diseases.

All rights reserved.

Case Report

A 35-year-old woman who was previously healthy presented with abrupt onset of dyspnea and loss of consciousness for 5 minutes. Three days earlier, she received an illegal hyaluronic acid injection performed by an unlicensed medical practitioner into the dermis of the forehead and right cheek area. On physical examination, vital signs were as follows: body temperature, 36.8°C; blood pressure, 150/110 mm Hg; pulse rate, 127/min; respiratory rate, 28/min. Mental status was confused. Crackles were revealed in both lower lung fields. Routine laboratory test including liver function test and renal function test showed normal range of results. And, complete blood count

was as follows: white blood cells, 21,080/ μ L (neutrophils 91%); hemoglobin, 11 g/dL; platelets, 240,000/ μ L. Troponin I, 0.16 ng/mL (normal, 0–0.1 ng/mL); CK-MB, 0.6 ng/mL (normal, 0–3.6 ng/mL); C-reactive protein, 5.307 mg/dL (normal, 0–0.5

mg/dL); D-dimer, 1.278 μ g/mL (normal, 0–0.5 μ g/mL); and N-terminal of the prohormone brain natriuretic peptide was 9,177 pg/mL (normal, 0–124 pg/mL). Arterial blood gas analysis via 15 L O₂ reservoir bag was as follows: pH, 7.505; PCO₂, 28.6 mm Hg; PO₂, 66.1 mm Hg; HCO₃⁻, 22.4 mmol/L. Plain chest radiography showed ground glass opacity and consolidation in both lung fields (Figure 1). Contrast-enhanced chest CT showed diffuse ground glass opacity in both lungs with dilatation of the pulmonary artery and right ventricle (Figure 2).

The patient was admitted to the intensive care unit and treated with mechanical ventilation owing to worsening hypoxemia. After several days, hemorrhagic eruptions occurred in anterior chest area. She was initially administered antibiotics, corticosteroids and diuretics. Hypoxemia was gradually improved. After 5 days, the result of initial blood culture showed no growth and there was no evidence of fever. Therefore, we could exclude the septic embolism and discontinued the antibiotics. She was weaned from mechanical ventilation. At the eighth day of hospital admission, she was discharged. After one month, she was completely improved and follow-up chest CT showed improvement of the previous pulmonary lesion without fibrosis (Figure 3).

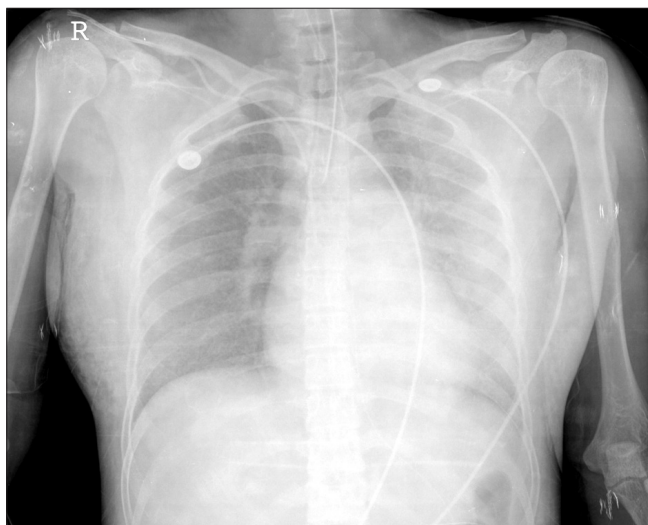

Figure 1. The plain chest radiography shows ground glass opacity and consolidation in both lung fields.

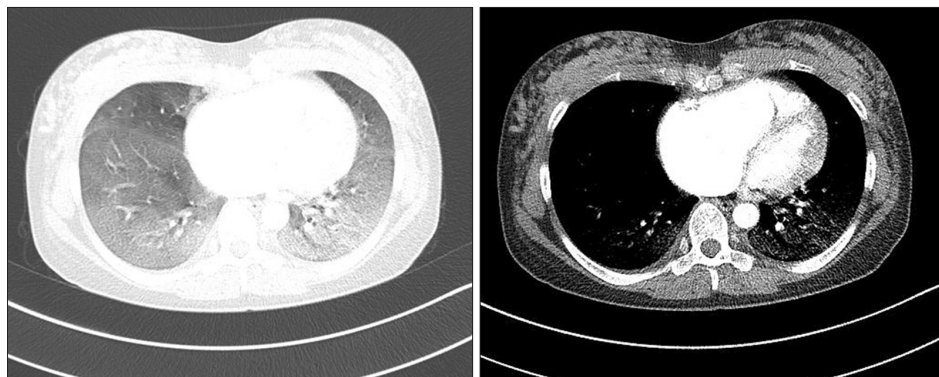


Figure 2. The contrast-enhanced chest computed tomography shows diffuse ground glass opacity in both lungs with dilatation of the pulmonary artery and right ventricle.

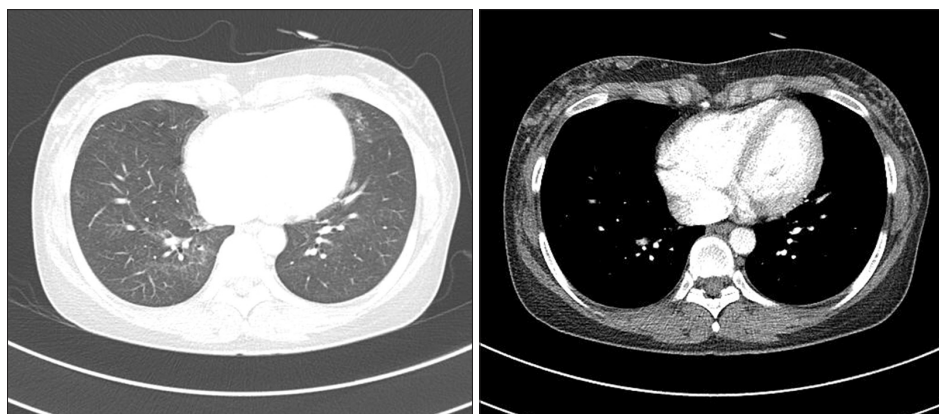


Figure 3. One month later, the contrast-enhanced chest computed tomography shows an improvement of multifocal ground glass opacity in both lungs and a decreased size of the right ventricle.

Discussion

NTPE is defined as an embolization in the pulmonary circulation that can be caused by a variety of nonthrombotic embolic agents³. Different cell types (e.g., adipocytes, hematopoietic cells, amniotic cells, trophoblasts, and tumor cells), bacteria, fungi, foreign materials and gasses in the blood-stream may form an embolism in the pulmonary circulation⁴. NTPE can occur as a result of endothelial or parenchymal injury, causing inflammatory reactions in both systemic and pulmonary circulation³.

Hyaluronic acid is approved dermal filler used to correct facial wrinkles and folds². Because the chemical structure of hyaluronic acid is conserved among all species, the potential for immunologic reactions and implant rejection is negligible. Thus, hyaluronic acid is a very suitable material for use as a dermal filler¹. Common side effects of dermal injections of hyaluronic acid include acneiform eruptions, lumps, inflammatory nodules, blue bumps (i.e., the Tyndall effect), vascular occlusion and granulomas⁵. However, rare cases of NTPE were reported after injection of hyaluronic acid. Two cases were reported pulmonary embolism after an intra-articular injection of methylprednisolone and hyaluronate^{6,7}. In that case, shortness of breath occurred after a knee injection of hyaluronic acid and multiple patchy ground glass opacities were observed bilaterally in the middle and lower lobes of the lungs on chest CT; biopsy revealed an amorphous material containing hyaluronic acid with fibrin. Park et al.² report a case of NTPE syndrome after an illegal hyaluronic acid vaginal injection³. Progressive dyspnea and decreased consciousness were observed 3 days after the injection; chest CT revealed bilateral ground glass opacity from the lower to apical zone, and biopsy confirmed a granulomatous foreign body reaction as observed in talc embolism².

This case was exhibited progressive dyspnea 3 days after hyaluronic acid dermal injection with hypoxemia, petechiae on the anterior chest wall and bilateral ground glass opacity on chest CT. In addition, chest CT showed basal dominant diffuse ground glass opacity, pulmonary artery dilatation, and cardiomegaly on the right side. Finding of this chest CT was distinguished from the finding of septic embolism which include multiple peripheral nodule, wedge-shaped peripheral lesion, cavitation of nodules, and a feeding vessel sign⁸. Also, the ground glass opacity distribution did not correspond to idiopathic interstitial pneumonia.

In the case reported by Park et al.² NTPE was believed to have occurred in the systemic circulation, because hyaluronic acid was injected to the anterior wall of vagina where extensive venous plexus exists. In addition, Bhagat et al.⁷ suggest NTPE occurs as a result of hyaluronic acid embolisms in the systemic circulation due to damage to the synovium as a result of hyaluronic acid injection. Analyzing the results of cases of various illegal silicone injections shows pulmonary silicone

embolism can occur via several mechanisms such as excessive local tissue pressure induced by large-dose and high-pressure injection, local massage by an unlicensed practitioner, migration effect, or direct intravascular injections⁹. As review of the above mentioned cases suggests the NTPE in the present patient occurred as a result of damage to facial soft tissues due to inappropriate anatomical location and injection by an unlicensed practitioner as well as the inflow of hyaluronic acid embolisms directly into the blood vessels. Although hyaluronic acid binds to endothelial cells throughout the body, it binds particularly well to the pulmonary vasculature¹⁰. The symptoms in the present case were due to mechanical obstruction caused by hyaluronic acid bound to the endothelial cells of the pulmonary vasculature. Accordingly, CT showed dilatation of the pulmonary artery and right ventricular enlargement. NTPE was diagnosed on the basis of clinical conditions and chest CT. Severe hypoxia improved after conservative treatment with mechanical ventilation, which led to rapid recovery. Follow-up chest CT revealed improvements without fibrosis, confirming the diagnosis of NTPE rather than other possibilities as a result of interstitial lung disease.

Although cases of NTPE caused by hyaluronic acid injection are occasionally reported, this is the first typical case shown to NTPE manifestation after facial injection of hyaluronic acid.

Conflicts of Interest

No potential conflict of interest relevant to this article was reported.

References

1. Matarasso SL, Carruthers JD, Jewell ML; Restylane Consensus Group. Consensus recommendations for soft-tissue augmentation with nonanimal stabilized hyaluronic acid (Restylane). *Plast Reconstr Surg* 2006;117(3 Suppl):3S-34S.
2. Park HJ, Jung KH, Kim SY, Lee JH, Jeong JY, Kim JH. Hyaluronic acid pulmonary embolism: a critical consequence of an illegal cosmetic vaginal procedure. *Thorax* 2010;65:360-1.
3. Bach AG, Restrepo CS, Abbas J, Villanueva A, Lorenzo Dus MJ, Schopf R, et al. Imaging of nonthrombotic pulmonary embolism: biological materials, nonbiological materials, and foreign bodies. *Eur J Radiol* 2013;82:e120-41.
4. Jorens PG, Van Marck E, Snoeckx A, Parizel PM. Nonthrombotic pulmonary embolism. *Eur Respir J* 2009;34:452-74.
5. Schanz S, Schippert W, Ulmer A, Rassner G, Fierlbeck G. Arterial embolization caused by injection of hyaluronic acid (Restylane). *Br J Dermatol* 2002;146:928-9.
6. Famularo G, Liberati C, Sebastiani GD, Polchi S. Pulmonary embolism after intra-articular injection of methylprednisolone and hyaluronate. *Clin Exp Rheumatol* 2001;19:355.

7. Bhagat R, Forteza RM, Calcote CB, Williams WT, Bigler SA, Dwyer TM. Pulmonary emboli from therapeutic sodium hyaluronate. *Respir Care* 2012;57:1670-3.
8. Kuhlman JE, Fishman EK, Teigen C. Pulmonary septic emboli: diagnosis with CT. *Radiology* 1990;174:211-3.
9. Price EA, Schueler H, Perper JA. Massive systemic silicone embolism: a case report and review of literature. *Am J Forensic Med Pathol* 2006;27:97-102.
10. Szczepanek K, Kieda C, Cichy J. Differential binding of hyaluronan on the surface of tissue-specific endothelial cell lines. *Acta Biochim Pol* 2008;55:35-42.