

## RESEARCH ARTICLE

# Role of Concomitant Chemoradiation in Locally Advanced Head and Neck Cancers

Savita Lasrado<sup>1\*</sup>, Kuldeep Moras<sup>1</sup>, George Jawahar Oliver Pinto<sup>1</sup>, Mahesh Bhat<sup>1</sup>, Sanath Hegde<sup>2</sup>, Brijesh Sathian<sup>3</sup>, Neil Aaron Luis<sup>4</sup>

### Abstract

Standard therapy for advanced head and neck cancer consists of a combination of surgery and radiation. However, survival of this patient population has not improved during the past 20 years. Many different multimodality treatment schedules have been proposed, and chemotherapy is often used with the intent of organ preservation. The present study was intended to establish the efficacy of concomitant chemoradiation with a single agent carboplatin in advanced head and neck cancers. The objectives were to investigate the feasibility of concomitant administration of carboplatin, monitor acute toxicity during radiotherapy, and determine subacute side effects, such as wound healing following surgery after chemoradiotherapy. A prospective study was conducted wherein a total of 40 patients with stage III and IV squamous cell carcinomas of oral cavity, oropharynx, hypopharynx and larynx were enrolled. All patients were treated with external beam radiotherapy and weekly carboplatin area under curve (AUC of 5). Radiotherapy was given in single daily fractions of 1.8-2 grays (Gy) to a total dose of 66-72 Gy. Salvage surgery was performed for any residual or recurrent locoregional disease. Neck dissection was recommended for all patients with neck disease showing less than a complete response after chemoradiation. A total of 40 patients were enrolled of whom 32 were males and 8 were females. Highest incidence of cancer was seen in the 5th-6th decades of life with a median age of 47.7 years. Oropharyngeal tumours constituted a maximum of 21 patients followed by hypopharynx in 10, larynx in 7 and oral cavity in 2. 80% of the patients had a neck node on presentation of which 40% had N2-N3 nodal status. TNM staging revealed that 58% of patients were in stage III and 43% in stage IV. Evaluation of acute toxicity revealed that 50% had grade II mucositis, 25% grade III mucositis, 2.5% grade IV mucositis. 50% of patients had grade I skin reactions, 65% of patients had grade I thrombocytopenia, and 24% of patients had grade I anaemia. After completion of treatment 65% of patients had complete response at the primary and regional sites, and 35% of patients had a partial response of whom 23% underwent neck dissection and 5% of them underwent salvage surgery at the primary site. At the end of one year there were six deaths and four recurrences and 70% were free of disease. Concurrent chemoradiation with carboplatin provided good locoregional control for locally advanced head and neck cancers. This regimen, although toxic, is tolerable with appropriate supportive intervention. Primary site conservation is possible in many patients. Chemoradiotherapy appears to have an emerging role in the primary management of head and neck cancers.

**Keywords:** Head and neck cancer - squamous cell carcinoma - radiotherapy - chemoradiation - carboplatin.

*Asian Pac J Cancer Prev*, 15 (10), 4147-4152

### Introduction

The term head and neck cancer refers to a group of biologically similar cancers originating from the upper aerodigestive tract, including the lip, oral cavity, nasal cavity, paranasal sinuses, pharynx and larynx. Head and neck cancers constitute 6% of all cancers worldwide (Vokes et al., 1993). Squamous cell carcinoma of the head and neck is one of the commonest cancers seen in developing countries, including India, constituting upto 25% of the overall cancer burden (Dinshaw et al., 2000).

Many factors interplay in the phenomenon of carcinogenesis. These include hereditary factors, hormones, ageing, immune status and background radiation. Squamous cell carcinoma is quite prevalent in India due to high consumption of tobacco, lime and betel leaves either alone or in combination with alcohol. Approximately 90% of the head and neck cancers occur after exposure to known carcinogens like tobacco and alcohol since both are known to act synergistically. Squamous cell carcinoma represents more than 90% of all head and neck cancers (Calcaterra and Juillard, 1995).

<sup>1</sup>Department of Otorhinolaryngology and Head and Neck Surgery, Father Muller Medical College, <sup>2</sup>Indian Institute of Oncology, Mangalore, India, <sup>3</sup>Department of Community Medicine, Manipal College of Medical Sciences, Manipal, Nepal, <sup>4</sup>Dental Surgeon in Private Practice, Queensland, Australia \*For correspondence: Savita\_menezes@yahoo.com

Nearly two-thirds of squamous cell carcinoma of the head and neck are in a locoregionally advanced stage at the time of presentation and diagnosis. More than 50% of the patients who die from head and neck cancer have locoregional disease as the only site of failure (Shah and Ladd, 1995).

The mode of treatment of patients with squamous cell carcinoma of the head and neck depends on the site and stage of the disease and on the overall health status of the patient. In most cases of stage I or II cancers, the single modality therapy of surgery or radiotherapy is the initial treatment of choice. Before 1980, the initial treatment of patients with locally advanced stage III or IV also would have been surgery and/or radiation therapy, a choice that also depended on the site of the disease, the resectability of the cancers, and the performance status and comorbidities of the patient (Al-Sarraf, 1998). However, because of the poor results obtained with "traditional" therapy in this latter group, especially those with stage IV disease or unresectable cancers, systemic chemotherapy was introduced in the mid 1970s as part of the combined modality treatment (Al-Sarraf, 1998).

The treatment of patients with locally advanced head and neck cancers has evolved since the introduction of combined modality treatment for these patients. In an attempt to increase local control in advanced head and neck cancers chemotherapy has been used before or after surgery and has been associated with good clinical response. Combined chemotherapy and radiation used simultaneously to get synergistic benefit against head and neck cancers has been associated with high level of response in in-operable disease. The most common drugs used are cisplatin, 5-fluorouracil, hydroxyurea and mitomycin.

The advent of concurrent chemoradiation has significantly contributed to the curability of head and neck cancers including the locoregionally advanced stages. Briefly, concurrent chemoradiotherapy attempts to capitalize on the tumour-radiosensitizing properties of chemotherapy or novel agents, in addition to potentially delivering active agents that function systemically. Concurrent chemoradiotherapy is an attractive organ-sparing approach because it achieves locoregional control without surgical resection of important anatomical structures. Concurrent chemoradiotherapy has a central role in the management of locoregionally advanced head and neck cancers and a survival benefit for this approach in comparison to radiation alone is now widely accepted (Pignon et al., 2000; Forastiere et al., 2013; Haddad et al., 2013). A meta-analysis of 63 trials concluded that chemotherapy added to locoregional treatment provided a benefit in survival rate of 4% at 2 and 5 years (Pignon et al., 2000). Treatment paradigms for head and neck carcinoma, especially for tumours involving certain sites such as the larynx and pharynx, have undergone radical change over the past decade. Preservation of function is a major endpoint of interest, and nonsurgical treatment options using chemotherapy and radiation therapy are now considered as standards of care. Hence, the present study is intended to find the efficacy of concomitant chemoradiation with a single agent carboplatin in locally

advanced head and neck cancers.

## Materials and Methods

The present study was conducted in the Department of Otorhinolaryngology, Father Muller Medical College, Mangalore, during the period August 2008 to January 2010. During this period 40 patients of either gender aged between 18-70 years who were diagnosed with squamous cell carcinoma stages III or IV with non metastatic (M0) disease were selected based on the following inclusion criteria with histologically confirmed squamous cell carcinoma of oral cavity, oropharynx, larynx or hypopharynx, and with adequate bone marrow, hepatic and renal functions.

Complete history including personal history of habits, detailed general examination and local examination including details of primary tumour, neck nodes and distant metastasis were enlisted. Patients who have undergone chemotherapy or radiation previously, and those with carcinoma of the nasopharynx, paranasal sinuses and salivary glands and patients with unknown primary of the head and neck were excluded from the study.

T and N classifications were assigned according to the staging system of the American Joint Committee on Cancer (AJCC), 6<sup>th</sup> edition, and only patients with stages III and IV, and M0 disease were eligible. All patients previously were untreated and had an Eastern Cooperative Oncology Group (ECOG) performance status of 0 to 2. Informed consent was obtained from all the patients for the study. Institutional ethical committee clearance was obtained at the first authors institution before commencement of the study. A multidisciplinary team consisting of otolaryngologist, a medical oncologist and a radiation oncologist evaluated each patient before patient enrollment. Pretreatment evaluation in all patients included a medical history, an examination under anaesthesia and biopsy, and a chest radiograph. Computed tomography (CT) scans or magnetic resonance imaging (MRI) of the involved head and neck region or other staging procedures for distant metastasis was obtained if clinically indicated. Pretreatment laboratory evaluation included a complete blood count and serum chemistry tests including urea, creatinine, calcium, phosphorous, alkaline phosphatase, aspartate aminotransferase, albumin, total protein, bilirubin, and uric acid. All patients underwent a pretreatment dental evaluation and nutritional assessment.

### Treatment plan

During the treatment, carboplatin was administered once a week at a dose of the area under the curve (AUC) 5, and was repeated for a total of five or six doses. Carboplatin was given as an infusion in 500ml 5% dextrose over one hour and two hours later was followed by radiation. Dexamethasone 4mg and ondansetron 8mg were given intravenously as pre-medication. Radiation was given in single daily fractions of 1.8 to 2 (grays) Gy, to a total dose of 66 to 72Gy. Radiotherapy was delivered 5 days a week using single daily fractions of 1.8 to 2.0Gy. Megavoltage (MeV) radiation was generated by a 6-MeV

linear accelerator. Opposed lateral fields were, in general, used with an electron-beam boost given to selected nodal regions as indicated. Patients with no neck nodes received about 50-55Gy radiation to the neck. After approximately 45Gy, patients were reevaluated. Patients with a 50% or greater decrease in the product of two perpendicular diameters of primary and secondary in the neck continued chemotherapy and completed radiotherapy to a total dose of 66-72Gy. For non-responders with resectable tumour, definitive surgery was recommended. The operation was performed 4-5 weeks after the discontinuance of the chemoradiotherapy.

For those patients who completed definitive radiation therapy, 6-12 weeks were allowed for mucosal recovery prior to a formal response analysis. This analysis included an examination under anaesthesia and biopsy when deemed appropriate by the clinical circumstances. Cervical lymph node dissection was performed in those patients undergoing primary site resection, or if any clinically palpable lymph nodes remained after radiation. Primary site surgery was not performed in those patients achieving a complete response at the primary site.

Any patient subsequently developing locoregional disease recurrence was considered for appropriate salvage surgery.

Patients were evaluated weekly toxicity, during their therapy in an effort to manage treatment-induced side effects, particularly mucositis and myelosuppression. Adverse events were assessed during the treatment and 6-12 weeks after treatment using the National Cancer Institute Common Toxicity Criteria (NCI-CTC), version 3.0. Laboratory testing (complete blood count, differential, platelet count) was carried out at least once a week and more often as indicated. Neutropenia with fever mandated hospitalization and appropriate antibiotic therapy. Nasogastric or percutaneous endoscopic gastrostomy feeding tubes were placed as needed. Tracheostomies were performed in those with significant airway compromise either at presentation or during the course of their treatment.

At the completion of therapy, patients were followed at regular and frequent intervals by all members of the multidisciplinary team. Careful clinical examination was performed at 2-3 month intervals and suspected local, regional, or distant recurrences were biopsied. Radiographic studies were performed as clinically indicated.

Complete response (CR) was defined as the disappearance of all known tumour masses lasting for 4 weeks, without the appearance of new lesions. Partial response (PR) was defined as decrease in 50% or more in sum of products of largest perpendicular diameters of all measurable lesions. Progressive disease (PD) was defined as an increase of more than 25% of all above measurements or the appearance of new lesions. Measurements obtained that were between the definitions of PR and PD were considered to be stable disease (SD).

## Results

During the period August 2008 to January 2010

forty patients with head and neck cancer who had not received previous radiotherapy or surgery and were in the locally advanced stage were enrolled in the present study and the following observations were made. There was overwhelming predominance of males constituting 80% of the study population, of the forty patients 32 were males and 8 were females. In our study group majority (35%) of the patients with head and neck cancer were in the age group of 50-59 years and 30% were in the age group 40-49 years (Table 1). The highest incidence of cancer was seen in the 5<sup>th</sup> 6<sup>th</sup> decades. The mean age at presentation was 47.7 years. In this study the youngest patient was aged 29 years and the oldest patient was aged 67 years.

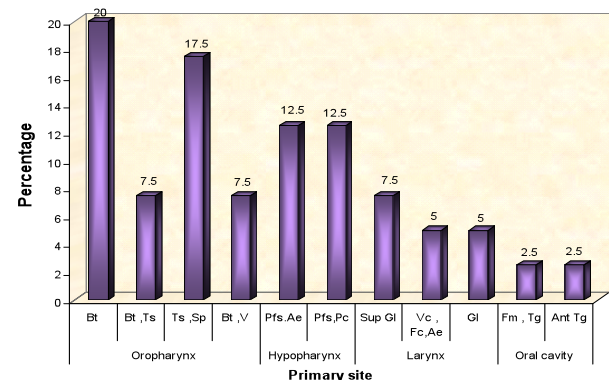
Oral hygiene was bad among 45% of the patients. Fifty five percent of the patients had smoking and alcohol abuse as contributory habits. An interpretation of the primary sites of tumour showed that oropharynx and hypopharynx encompassed the vast majority of primary sites of origin of these malignancies. 52.5% of these sites were in the oropharynx, 25% in the hypopharynx, 17.5% in the larynx, and 2.5% in the oral cavity (Figure 1). Among these primary sites, base of the tongue emerged as the leading subsite which constituted 35%, pyriform fossa in 25%, tonsil and soft palate in 17.5%. Other subsites included larynx, lateral pharyngeal walls, vallecula, floor of mouth, and post cricoid area.

In our study 52.5% of patients had their origin of tumour on the right side of median plane, 37.5% had on left side of median plane and 10% in the median plane. Midline lesions exhibited more aggressive nature and early nodal metastasis. They showed multiple level involvement and also bilateral nodal spread.

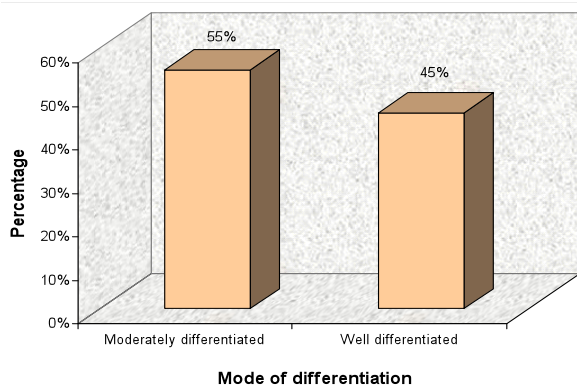
The histopathology showed that 55% were moderately differentiated and 45% were well differentiated (Figure 2). No significant difference was found in the rate of response based on grade of differentiation. Tumour staging of our

**Table 1. Age Distribution**

Age in years	No. of patients	Percent
<30	1	2.5
30-39	6	15
40-49	12	30
50-59	14	35
60-69	7	17.5
Total	40	100



**Figure 1. Tumour Sites**



**Figure 2. Mode of Differentiation**

patients was done, 47.5% of patients were with T2, 37.5% with T3, and 15% with T4. There were no patients with T1 lesion. These data do not represent the actual final staging of these tumours as they depend on the size and number of secondary nodes (N-staging). A T1 lesion could end up at stage III with N1 nodal status or stage IV with N2 nodal status.

An analysis of nodal staging showed that 80% had positive neck nodes at the time of presentation and of them 40% had N2-N3 nodal status which indicated the possibility of stage IV presentation. In the remaining 20% had no neck nodes and another 40% with N1 nodal status. The presence of neck nodes at presentation itself reduces the lifespan by 50%. Distant metastasis was not seen in any of the head and neck cancer patients studied (M0/MX).

According to AJCC 6<sup>th</sup> edition staging of head and neck cancers 57.5% of the patients were in stage III, and 42.5% were in stage IV (Figure 2). Evaluation of acute toxicity revealed that 50% had grade I mucositis, 25% grade II mucositis, 23% grade IV mucositis. 50% of patients had grade I skin reactions, 65% of patients had grade I thrombocytopenia, and 24% of patients had grade I anaemia.

The response to treatment was assessed after a period of 6-12 weeks, after the acute toxicities had settled. A total of 26 patients (65%) had a complete response to chemoradiation. The remaining 14 patients (35%) had a partial response and of the partial responders 29.5% showed complete response at the primary site. Of the partial responders 23% underwent neck dissection and 5% of them underwent salvage surgery at the primary site two patients, (5%) one with laryngeal and one pyriform fossa carcinoma who had less than a complete clinical response, underwent surgical salvage. At the end of one year there were six deaths and four recurrences and 70% of patients showed a good response to concurrent chemoradiation with carboplatin.

## Discussion

In the present study an attempt was made to elucidate the efficacy of radiotherapy with concurrent carboplatin in stage III and stage IV head and neck malignancies. The object was to investigate the feasibility of concomitant administration of carboplatin, monitoring acute toxicity during radiotherapy, and subacute side effects, such as

wound healing following surgery after chemoradiotherapy.

As a universally accepted fact, this study also emphasized the overwhelming predominance of males over females to develop malignancy of head and neck region. Out of 40 cases studied 80% were males and 20% were females with a male to female ratio of 4:1. Study by Okami et al. (2007) also observed male to female ratio of 4:1. The male predominance in head and neck cancer can be attributed to the fact that habits like tobacco smoking, alcohol and pan chewing are more prevalent among males. It has been widely approved that the cancer of head and neck regions appear more frequently in the sixth and seventh decades of life compared to younger age groups (Robert et al., 1988). In our study the highest incidence of cancer was seen in the 5<sup>th</sup>-6<sup>th</sup> decades. The mean age at presentation was 47.7 years. Smoking and alcoholism emerged as chief contributory habits in patients with head and neck cancer included in the study. An interesting observation noted in those patients was that the vast majority of them were beedi smokers, as majority of patients were from low socio-economic status who could not afford to use the more expensive varieties of tobacco. Cancer groups have proposed that in India, among the males, the tobacco related cancers are expected to be 225, 241 (42% of all sites cancers) by the year 2020 (Takiar et al., 2010).

Radiation therapy is the conventional treatment for locally advanced, nonresectable cancers of head and neck. However, therapeutic measures are poor with this treatment modality, and chemotherapy has been used in an effort to improve the therapeutic results. Concurrent administration of chemotherapy and radiotherapy is a promising approach for treating patients with locally advanced head and neck cancer. Moreover chemotherapy given as part of concurrent chemoradiation may act systemically and potentially eradicate distant micrometastases (Seiwert et al., 2007; Herman et al., 2014). Concomitant chemoradiation treatment with platinum containing regimens particularly at the treatment of unresectable head and neck cancers has been used as an effective treatment as combined therapy has proven to be superior to radiotherapy alone in terms of overall survival, disease free survival and local control (Pignon et al., 2000; Zhu et al., 2012; Baykara et al., 2013; Forastiere et al., 2013; Haddad et al., 2013). The Meta-Analysis of Chemotherapy in Head and Neck Cancer (MACH-NC) Group analysed the effect of chemotherapy on HNSCC using data from 63 randomized clinical trials between 1965 and 1993 (Pignon et al., 2000). This landmark report demonstrated a 4% 5 year overall survival benefit for patients treated with chemotherapy; including neoadjuvant, concurrent and adjuvant settings. Interestingly, the concurrent chemoradiation patients had the best results with an 8% overall survival benefit (Calcattera and Juillard, 1995).

In our study carboplatin was used as it had fewer toxic effects on renal function, less nausea and vomiting, ability to give the drug on outpatient basis, and the existence of data suggesting that the regimen has a radiosensitizing effect (Yang et al., 1995; Nam et al., 2007). Previously monthly administration of high dose of carboplatin was

widely used. Weekly administration of carboplatin during radiotherapy has been shown to be well tolerated for various advanced head and neck cancers (Eisenberger et al., 1998; Denis et al., 2004; Taguchi et al., 2009). Eisenberger reported that the weekly administration of carboplatin using 60-100mg/m<sup>2</sup> for 5 weeks, appeared to be better tolerated than a monthly schedule with the same total dosage (Eisenberger et al., 1998). A study by Eun Ji Nam comparing carboplatin and cisplatin based concurrent chemoradiotherapy in locally advanced cervical cancer patients showed Carboplatin was better tolerated than Cisplatin without compromising tumor response and survival in patients with locally advanced cervical cancer and poor general condition (Nam et al., 2013). The present study confirms that this dose schedule is not only feasible, but also safe enough to be used with better prognosis.

When compared to previous studies conducted by (Calais et al., 1999) degree of toxicity was found to be higher than with only radiotherapy. No significant nephrotoxicity or ototoxicity was found in our study as compared with cisplatin, which was reported by (Hosokawa et al., 1995; Bertino et al., 2009; Herman et al., 2014). In our study 95% of patients tolerated the treatment protocol well. One patient developed febrile neutropenia after the fifth cycle of chemotherapy, and another patient had grade 3 leucopenia. As far as acute mucosal and skin reactions were concerned, carboplatin was shown not to be a radiosensitizer for normal tissues. However, in the present study some episodes of poor wound healing following neck dissection after radiotherapy suggested that carboplatin might enhance late radiation damage to subcutaneous tissues.

Clinical evidence of residual palpable disease after chemoradiation was common and was seen in 14 patients (35%) with N+ neck disease on presentation. The neck response showed no relation to location of primary tumour. The overall regional control rate after chemoradiation was 65%, which is comparable to data already published (Calais et al., 1999). In this study, the neck control rate was excellent after treatment for patients who had nodes 3 cm or less at diagnosis. Management of patients with neck nodes 3-6 cm and more following therapy is much debated, hence a systematic neck dissection should be recommended.

Of total 40 patients only 5% had less than a complete clinical response at the primary site. The other 95% did not require primary site surgery. Hence concurrent chemoradiation proved to be efficacious in organ preserving. In this study 52.5% patients had oropharyngeal cancers. Tumours arising from soft palate and base of tongue may impede speech and swallowing, especially when they are locally advanced. Resection of a large amount of normal tissue to achieve tumour-free margins results in severe speech and swallowing dysfunction that adversely affects patients quality of life, and concurrent chemoradiation provided good locoregional control for locally advanced cancers and proved to be efficacious in organ preserving.

With a median follow up of ten months there were 4 (10%) patients with primary site recurrence. Interestingly

it was found that all these patients were the ones who continued to consume alcohol. There were 6 deaths out of which two were due to carotid blow out, which occurred after chemoradiation and surgery. Two more were due to aspiration pneumonia. At the end of one year 70% of the patients had survived with a complete response at the primary and regional sites with no evidence of metastasis. However, the study period was limited to reach definite conclusions regarding survival and late toxicity.

In conclusion, chemoradiation appears to have an emerging role in the primary management of head and neck cancers. This chemoradiation regimen combined with salvage surgery, when appropriate produces impressive locoregional control with a seemingly low rate of distant metastasis. It also has organ preservation capabilities.

Chemotherapy, while not a curative modality in treatment of head and neck cancer, has the potential to improve locoregional control, reduce distant metastasis and improve survival compared to radiation alone.

## References

- Al-Sarraf M (1988). Head and neck cancer: chemotherapy concepts. *Semin Oncol*, **15**, 70-85.
- Baykara M, Buyukberber S, Ozturk B, et al (2013). Efficacy and safety of concomitant chemoradiotherapy with cisplatin and docetaxel in patients with locally advanced squamous cell head and neck cancers. *Asian Pac J Cancer Prev*, **14**, 2557-61.
- Bertino G, Occhini A, Falco CE, et al (2009). Concurrent intra-arterial carboplatin administration and radiation therapy for treatment of advanced head and neck squamous cell carcinoma: short term results. *BMC Cancer*, **9**, 313.
- Calais G, Alfonsi M, Bardet E, et al (1999). Randomized trial of radiation therapy versus concomitant chemotherapy and radiation therapy for advanced stage oropharynx carcinoma. *J Natl Cancer Inst*, **91**, 2081-6.
- Calcaterra TC, Juillard GJ (1995). Oral cavity and hypopharynx-head and neck cancer. In: Haskell CM, Berek JS, editors. *Cancer Treatment*. WB Saunders Co: Philadelphia, .p.726-732.
- Denis F, Garaud P, Bardet E, et al (2004). Final results of the 94-01 French head and neck oncology and radiotherapy group randomized trial comparing radiotherapy alone with concomitant radiochemotherapy in advanced stage oropharynx carcinoma. *J Clin Oncol*, **22**, 69-76.
- Dinshaw KA, Rao DN, Ganesh B (2000). Hospital based cancer registry, annual report, Tata Memorial Hospital, Mumbai, India.
- Eisenberger M, Sinibaldi V, Jacobs M, Gray W (1988). Simultaneous treatment with carboplatin (NSC-241-240) and radiotherapy in advanced unresectable squamous cell carcinomas of the head and neck. *Cancer Treat Rev*, **1988**, 3-7.
- Haddad R, O'Neill A, Rabinowits G, et al (2013). Induction chemotherapy followed by concurrent chemoradiotherapy (sequential chemoradiotherapy) versus concurrent chemoradiotherapy alone in locally advanced head and neck cancer (PARADIGM): a randomised phase 3 trial. *Lancet Oncol*, **14**, 257-64.
- Herman LC, Chen L, Garnett A, et al (2014). Comparison of carboplatin-paclitaxel to docetaxel-cisplatin-5-fluorouracil induction chemotherapy followed by concurrent chemoradiation for locally advanced head and neck cancer.

- Hosokawa Y, Kamada T, Shirato H, et al (1995). Simultaneous carboplatin and radiotherapy for all stages of head and neck squamous cell carcinoma. *Clin Oncol*, **7**, 168-72.
- Mabanta SR, Mendenhall WM, Stringer SP, Cassisi NJ (1999). Salvage treatment for neck recurrence after irradiation alone for head and neck squamous cell carcinoma with clinically positive neck nodes. *Head Neck*, **21**, 591-4
- Nam EJ, Lee M, Yim GA, et al (2013). Comparison of carboplatin- and cisplatin-based concurrent chemoradiotherapy in locally advanced cervical cancer patients with morbidity risks. *Oncologist*, **18**, 843-9.
- Nguyen NP, Vos P, Smith HJ, et al (2007). Concurrent chemoradiation for locally advanced oropharyngeal cancer. *Am J Otolaryngol*, **28**, 3-8.
- Okami K, Hamano T, Takeo T, Sugimoto R, Sekine M (2007). A survey of head and neck malignancy at Tokai University Hospital. *Tokai J Exp Clin Med*, **32**, 62-6.
- Pignon JP, Bourhis J, Dornier C, Designe L (2000). Chemotherapy added to locoregional treatment for head and neck squamous-cell carcinoma: three meta-analyses of updated individual data. *Lancet*, **355**, 949-55.
- Robert JK, Benjamin GW, Cleveland OH, et al (1988). Squamous cell carcinoma of head and neck in patients 40 years of age and younger. *Laryngoscope*, 531-3.
- Seiwert TY, Salama JK, Vokes EE (2007). The concurrent chemoradiation paradigm-general principles. *Nat Clin Pract Oncol*, **4**, 86-100.
- Shah JP, Ladd W (1995). Treatment of cancer of the head and neck. *CA Cancer J Clin*, **45**, 352-68.
- Taguchi T, Tsukuda M, Mikami Y, et al (2009). Treatment results and prognostic factors for advanced squamous cell carcinoma of the head and neck treated with concurrent chemoradiotherapy. *Auris Nasus Larynx*, **36**, 199-204.
- Takiar R, Nadayil d, Nandakumar A (2010). Projections of number of cancer cases in India (2010-2020) by cancer groups. *Asian Pac J Cancer Prev*, **11**, 1045-9.
- Vokes EE, Weichselbaum RR, Lippman SM, Hong WK (1993). Head and neck cancer. *N Engl J Med*, **328**, 184-94.
- Yang LX, Douple E, Wang HJ (1995). Irradiation-enhanced binding of carboplatin to DNA. *Int J Radiat Biol*, **68**, 609-614.
- Zhu WG, Zhou K, Yu CH, et al (2012). Efficacy analysis of simplified intensity-modulated radiotherapy with high or conventional dose and concurrent chemotherapy for patients with neck and upper thoracic esophageal carcinoma. *Asian Pac J Cancer Prev*, **13**, 803-7.