

Case report

Korean J Pediatr 2014;57(4):202-205

<http://dx.doi.org/10.3345/kjp.2014.57.4.202>

pISSN 1738-1061 • eISSN 2092-7258



CrossMark
click for updates



Korean J Pediatr

Pulmonary hemorrhage in pediatric lupus anticoagulant hypoprothrombinemia syndrome

Ji Soo Kim, MD, Min Jae Kim, MD, E Young Bae, MD, Dae Chul Jeong, MD

Department of Pediatrics, The Catholic University of Korea College of Medicine, Seoul, Korea

Lupus anticoagulant-hypoprothrombinemia syndrome (LAHPS), a very rare disease that is caused by the presence of antifactor II antibodies, is usually counterbalanced by the prothrombotic effect of lupus anticoagulant (LAC). Patients with LAHPS are treated using fresh frozen plasma, steroids, immunosuppressive agents, and immunoglobulins for managing the disease and controlling hemorrhages. Notably, steroids are the important treatment for treating hypoprothrombinemia and controlling the bleeding. However, some patients suffer from severe, life-threatening hemorrhages, when factor II levels remain very low in spite of treatment with steroids. Here, we report a case of LAHPS in a 15-year-old girl who experienced pulmonary hemorrhage with rapid progression. She was referred to our hospital owing to easy bruising and prolonged bleeding. She was diagnosed with LAHPS that presented with pancytopenia, positive antinuclear antibody, prolonged prothrombin time, activated partial thromboplastin time, positive LAC antibody, and factor II deficiency. Her treatment included massive blood transfusion, high-dose methylprednisolone, vitamin K, and immunoglobulin. However, she died due to uncontrolled pulmonary hemorrhage.

Corresponding author: Dae Chul Jeong, MD
Department of Pediatrics, Seoul St. Mary's Hospital, The Catholic University of Korea College of Medicine, 222 Banpo-daero, Seocho-gu, Seoul 137-701, Korea
Tel: +82-2-2258-6180
Fax: +82-2-537-4544
E-mail: dcjeong@catholic.ac.kr

Received: 27 February, 2013

Revised: 25 May, 2013

Accepted: 13 September, 2013

Key words: Lupus anticoagulant-hypoprothrombinemia syndrome, Steroids, Immunoglobulins

Introduction

Lupus anticoagulant-hypoprothrombinemia syndrome (LAHPS) is a very rare disease associated with transient viral infections, drug reactions, antiphospholipid syndrome, systemic lupus erythematosus (SLE) and exists even in healthy individuals¹⁻³. It is caused by antifactor II antibody, which is usually counterbalanced by the prothrombotic effect of lupus anticoagulant (LAC)¹⁻³. Corticosteroid is required to control the hemorrhage and correct the hypoprothrombinemia, and is effective in many cases^{3,4}. However, some cases with fatal course showed poor response to steroid treatment¹.

We report a clinical case of a 15-year-old girl with SLE, who was diagnosed with LAHPS and died due to uncontrolled pulmonary hemorrhage caused by factor II deficiency in spite of supportive treatment including steroid and immunoglobulin.

Case report

A 15-year-old girl was admitted to the previous hospital due to easy bruising and prolonged bleeding after tooth extraction. She was easily fatigued and suffered from loss of appetite for several weeks. Laboratory data revealed pancytopenia. After several days, she was transferred to our hospital for further evaluation for pancytopenia. She had no past or family history of any bleeding disorders or connective tissue diseases.

Copyright © 2014 by The Korean Pediatric Society

This is an open-access article distributed under the terms of the Creative Commons Attribution Non-Commercial License (<http://creativecommons.org/licenses/by-nc/3.0/>) which permits unrestricted non-commercial use, distribution, and reproduction in any medium, provided the original work is properly cited.

The patient was stable in vital signs, and revealed no specific findings except for several bruises on both lower legs on physical examination. Initial laboratory tests showed a leukocyte count of 1,560/ μ L, hemoglobin 7.5 g/dL, and a platelet count 19,000 / μ L. The patient's prothrombin time (PT) was 28.6 seconds (normal values, 10.1–14.0 seconds) and 23%, international normalized ratio was 2.65, and activated partial thromboplastin time (aPTT) was more than 120 seconds (normal values, 21.0–38.0 seconds). The disseminated intravascular coagulation (DIC) profile showed that 89% of antithrombin III (normal values, 80%–120%), 0.47 mg/L of d-dimer (normal values, <0.8 mg/L) and 1.08 μ g/mL of fibrin degradation products (normal values, <5 μ g/mL), and these results suggested that she was not complicated with DIC. The patient also had proteinuria (3+) and microscopic hematuria. There were no abnormalities on her chest radiography. The bone marrow biopsy, study for autoimmune disease and factor disease were planned to find out the cause of pancytopenia and prolongation of PT and aPTT. The patient was given blood transfusion with packed red cells, fresh frozen plasmas (FFPs), and single donor platelets.

On hospital day 2, the patient developed fever and cough. The chest radiography showed mild haziness with mild left pleural effusion, and she was started on intravenous antibiotics. Peripheral blood still showed pancytopenia and there was no improvement of prolongation of PT and aPTT in spite of blood transfusion including FFP.

On hospital day 4, an antibody screening test for cold antibody and the direct Coomb's test were positive. The complement levels were C3, 18 mg/dL; C4, <1.0 mg/dL; and CH₅₀, <10 U/mL. Tests for antinuclear antibodies, antidouble stranded DNA antibodies, LAC antibodies, anticardiolipin antibodies immunoglobulin (Ig) M, SLE profile and syphilis reagin test were all positive. And

antiphospholipid antibodies IgM/G and anticardiolipin antibodies IgG were negative. Repeated complete blood count, PT and aPTT showed no significant change in spite of continuous blood products transfusion. The bone marrow biopsy was normal. We diagnosed the patient with SLE based on revised criteria of American College of Rheumatology. The patient had no other symptoms except for purpura on lower extremities, and radiographic finding showed no significant change compared to prior 2 days ago.

On hospital day 7, the patient complained of dyspnea. Moist rales were audible around all the lung fields. Follow-up x-rays showed slightly increased haziness on both lung fields. Evaluation of clotting factors revealed that the level of factor II was 3.3% (normal values, 50%–150%). We confirmed the patient with LAHPS. A 1:1 dilution of patient plasma with normal plasma partially corrected the PT and aPTT. Protein S activity was 147.4% (normal values, 65%–140%) and protein C activity, 76% (normal values, 70%–130%). We added high dose of intravenous methylprednisolone pulse therapy (20 mg/kg/day) but platelet count and prolongation of PT and aPTT did not improve. On hospital day 10, the dyspnea was aggravated due to the pulmonary hemorrhage and she was moved into the intensive care unit. Computed tomography scans for chest, abdomen and pelvis showed no thromboembolisms. Intravenous immunoglobulin (IVIG) treatment (300 mg/kg/day) had no effect for correction of PT and aPTT, but platelet count slightly increased. PT and aPTT were slightly improved after administration of IVIG for 2 days. The blood test results showed a platelet count of 78,000 / μ L, PT of 42%, and aPTT of 88.5 seconds (Fig. 1). However, levels of aspartate aminotransferase, alanine aminotransferase, blood urea nitrogen and creatinine began to increase. We increased the dose of IVIG up to 1 g/

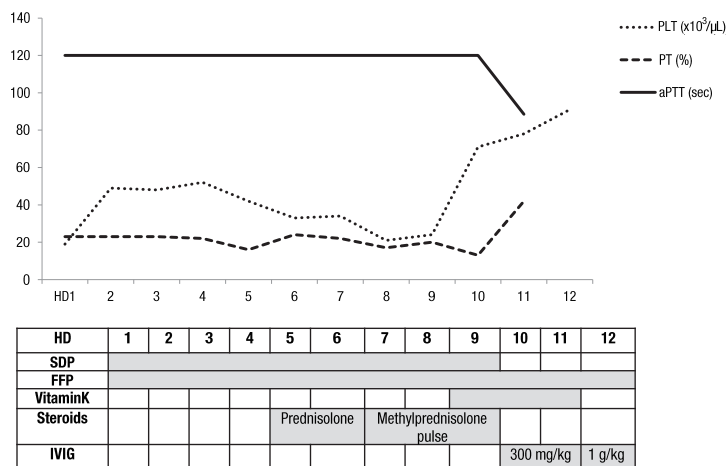


Fig. 1. Laboratory findings of the patient and the treatment provided. HD, hospital day; PLT, platelet; PT, prothrombin time; aPTT, activated partial thromboplastin time; SDP, single donor platelet; FFP, fresh frozen plasma; IVIG, intravenous immunoglobulin.

kg/day, but her chest condition deteriorated very rapidly and multiorgan failure got worse, too. Finally she required intubation and mechanical respiratory support, and died due to aggravation of the pulmonary hemorrhage on hospital day 12.

Discussion

LAC is an antiphospholipid antibody associated with hypercoagulable states and thromboembolic events¹⁻³. In most children of young age, the presence of LAC is transient, benign and postinfectious compared to autoimmune persisted type which mainly occurs in adolescence⁵. Bleeding is a rare manifestation of LAC, and when it occurs, it is nearly always due to thrombocytopenia or factor II deficiency^{2,6}. Such bleeding results from the presence of antifactor II antibody, which usually counterbalances the prothrombotic effect of LAC¹. And also, thrombosis was rare and strongly associated with persistently positive LAC⁵. LAC along with a specific nonphospholipid-dependent antiprothrombin antibody causes an acquired hypoprothrombinemia⁷.

LAPHS is a rare clinical disease. It occurs with viral infection and drug reactions in healthy individuals, or it appears mostly in young females with autoimmune disease like SLE^{1-3,6}. Increasing incidence during adolescence and the gender distribution are similar to those of SLE⁵. Seventy-four cases of LAPHS has been reported worldwide according to a literature review retrieving the related articles published between 1960 and 2011. Epidemiologic characteristics of these 74 cases shows that 43 patients (58%) were aged <15 years at disease onset⁸. The mechanism suggested that antiphospholipid antibodies bound to prothrombin in circulation accelerate clearance rather than interfere with prothrombin function⁵. Some authors suggest cross-reactivity between the antiphospholipid antibodies and phospholipid epitopes in the prothrombin molecules¹. The clinical findings are generally asymptomatic, but there can be severe hemorrhagic symptoms such as gynecologic bleeding, macroscopic hematuria, gastrointestinal bleeding, brain hematoma, diffuse muscular hematoma and venous or arterial thrombosis^{2,8}. Despite the fact that about 50% of patients develop severe bleeding, the overall prognosis is quite good, with a mortality rate of less than 5%⁸.

Treatment of factor II deficiency should be individualized, and the underlying cause should be found and treated. Administration of FFP, prothrombin complex concentrates, vitamin K are useful. However, most of cases responded successfully to corticosteroid but not to vitamin K, FFP or blood transfusion³. Most of patients previously reported in the literature have responded well to prednisolone treatment alone^{3,4}. A few cases required additional immunosuppressive drugs such as cyclophosphamide, azathioprine or rituximab because the

patients had symptom recurrences when drug therapy was tapered, but immunosuppression may not work immediately^{1,3,9}. Therefore, corticosteroid therapy is the treatment of choice for LAHPS associated with SLE^{1-4,6,8}. It decreases the clearance of the prothrombin antibody complexes and normalizes abnormal coagulation times, including those of PT, aPTT and clotting factors^{1-4,6}. IVIG treatment also has been shown to be effective in the setting of acute bleeding¹. In our patient, bleeding did not stop with steroid treatment. Coagulation studies improved significantly after administration of IVIG but the patient died because of uncontrolled pulmonary hemorrhage. We think that the administration of IVIG was started too late with an insufficient dose.

Our case shows that when bleeding occurs in SLE patients, the possibility of hypoprothrombinemia should be considered and prothrombin time and factor study should be measured³. Significant prolongation of the PT or aPTT requires further evaluation for autoantibodies against coagulation factors¹⁰. Management may require the use of intravenous steroids, immunoglobulin and immunosuppressive agents^{1,6,9}. But if factor II levels are very low (under 10%), patients may experience severe life threatening bleeding such as uncontrolled pulmonary hemorrhage. LAHPS associated with autoimmune disease should be diagnosed and managed carefully. Early treatments are thought to be helpful because severe hemorrhagic complications are common. Moreover, the rapid progression of hemorrhage can be retarded by more aggressive treatments such as immunoglobulins and immunosuppressive agents.

Conflict of interest

No potential conflict of interest relevant to this article was reported.

References

1. Taddio A, Brescia AC, Lepore L, Rose' CD. Steady improvement of prothrombin levels after cyclophosphamide therapy in pediatric lupus anticoagulant hypoprothrombinemia syndrome (LAHPS). *Clin Rheumatol* 2007;26:2167-9.
2. Chung CH, Park CY. Lupus anticoagulant-hypoprothrombinemia in healthy adult. *Korean J Intern Med* 2008;23:149-51.
3. Vivaldi P, Rossetti G, Galli M, Finazzi G. Severe bleeding due to acquired hypoprothrombinemia-lupus anticoagulant syndrome. Case report and review of literature. *Haematologica* 1997;82:345-7.
4. Hift RJ, Bird AR, Sarembock BD. Acquired hypoprothrombinemia and lupus anticoagulant: response to steroid therapy. *Br J Rheumatol* 1991;30:308-10.
5. Male C, Lechner K, Eichinger S, Kyrle PA, Kapiotis S, Wank H, et al. Clinical significance of lupus anticoagulants in children. *J Pediatr*

- 1999;134:199-205.
6. Erkan D, Bateman H, Lockshin MD. Lupus anticoagulant-hypoprothrombinemia syndrome associated with systemic lupus erythematosus: report of 2 cases and review of literature. *Lupus* 1999; 8:560-4.
 7. Knobe K, Tedgard U, Ek T, Sandstrom PE, Hillarp A. Lupus anticoagulants in two children--bleeding due to nonphospholipid-dependent antiprothrombin antibodies. *Eur J Pediatr* 2012;171: 1383-7.
 8. Mazodier K, Arnaud L, Mathian A, Costedoat-Chalumeau N, Haroche J, Frances C, et al. Lupus anticoagulant-hypoprothrombinemia syndrome: report of 8 cases and review of the literature. *Medicine (Baltimore)* 2012;91:251-60.
 9. Simel DL, St Clair EW, Adams J, Greenberg CS. Correction of hypoprothrombinemia by immunosuppressive treatment of the lupus anticoagulant-hypoprothrombinemia syndrome. *Am J Med* 1987;83:563-6.
 10. Baca V, Montiel G, Meillon L, Pizzuto J, Catalan T, Juan-Shum L, et al. Diagnosis of lupus anticoagulant in the lupus anticoagulant-hypoprothrombinemia syndrome: report of two cases and review of the literature. *Am J Hematol* 2002;71:200-7.