

## Case Report

# Ganglion of the Flexor Tendon Sheath between A1 Pulley and A2 Pulley

Kyu Hwa Jung, Hwan Jun Choi, Jun Hyuk Kim

Department of Plastic and Reconstructive Surgery, Soonchunhyang University College of Medicine, Cheonan, Korea

Received February 14, 2014

Revised March 5, 2014

Accepted April 21, 2014

Correspondence to: Hwan Jun Choi  
Department of Plastic and  
Reconstructive Surgery,  
Soonchunhyang University  
Hospital Cheonan, Soonchunhyang  
University College of Medicine, 31  
Suncheonhyang 6-gil, Dongnam-gu,  
Cheonan 330-903, Korea  
Tel: +82-41-570-2195  
Fax: +82-41-574-6133  
E-mail: medi619@hanmail.net

Few articles have been written about the flexor tendon sheath ganglion in the finger, especially, between A1 pulley and A2 pulley. We report on rare cases of flexor tendon sheath ganglion with one symptomatic and two asymptomatic. All masses were evaluated using real-time ultrasonography and well-defined anechoic cystic lesions with posterior enhancement were observed. A 17-year-old female had a small mass at the 4th metacarpophalangeal joint of her right hand, with pain and triggering. The patient underwent simple excision and a ganglion measuring 1.0×0.8 cm in size was derived from Camper's chiasm, between A1 pulley and A2 pulley. In two asymptomatic cases, ganglia measuring less than 0.5 cm in size observed. Based on our experience, real-time ultrasonography would be an excellent diagnostic modality in determining the treatment method in flexor tendon sheath ganglia, and surgical excision is recommended in symptomatic, especially triggering patients.

**Key Words:** Hand, Tendons, Ganglion cyst, Ultrasonography

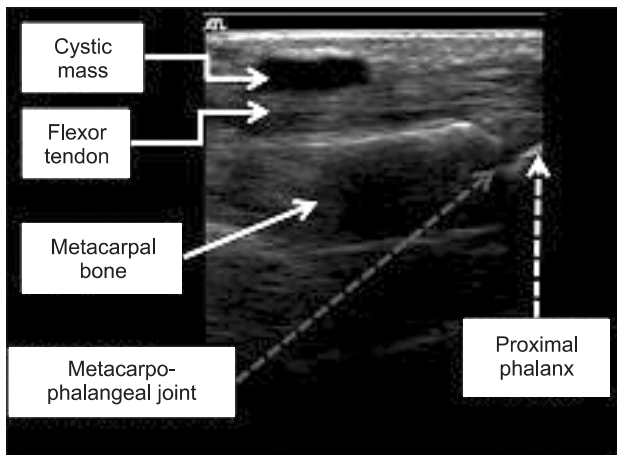
Ganglia occur in specific locations in the hand, wrist and foot. They are usually soft, solitary and asymptomatic, but cause pain and neurologic symptoms when developed near peripheral nerve region.<sup>1</sup> It is the most common soft tissue tumor of the hand, representing approximately 50% to 70% of all upper extremity masses but the exact etiology of ganglion cysts remain obscure.<sup>2</sup> The female to male ratio of ganglion in flexor tendon sheath has been reported as 2.6 to 1 and is predominant in females in their 30s and 40s' flexor tendon sheath between first annular (A1) and second annular (A2) pulleys of middle finger.<sup>3</sup> The A1 pulley is known to be involved most commonly followed by A2 pulley and the area between A1 and A2 pulley is rarely involved.<sup>2</sup> We report two cases of ganglia originated from the flexor tendon sheath in the area between A1 and A2 pulley and one case originated from Camper's chiasm.

## CASE REPORT

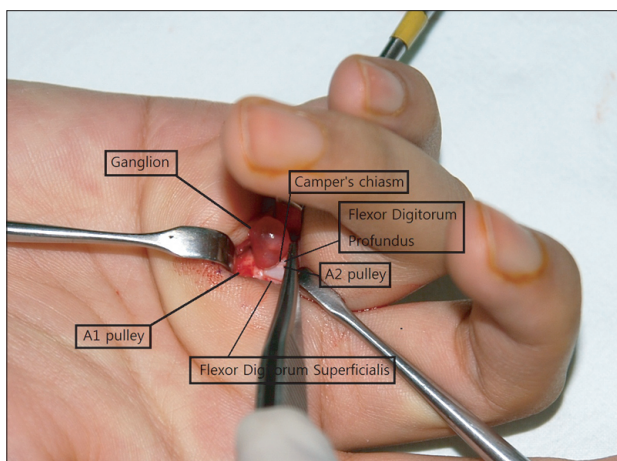
### Case 1

A 17-year-old female patient visited the hospital with sustained pain on the metacarpophalangeal (MCP) joint area of her right ring finger for few months. She was a pianist and had no medical or traumatic history. She had tenderness on her grasping motion, and mild trigger finger was observed with her flexion-extension motion of MCP joint. A 1.0×0.8 cm sized cystic mass was detected on the subcutaneous layer of MCP joint (Fig. 1). The mass was fixed during the flexion-extension movement in real-time ultrasonography and the flexor tendon sheath beneath the mass did not show any abnormal finding during the movement.

The excision of mass was done with transverse incision parallel to the palm crease. The mass was located on the Camper's chiasm between A1 and A2 pulley (Fig. 2). The mass was excised without any injuries to the surrounding



**Fig. 1.** A 17-year-old female had presented with history of mild swelling and pain at the 4th metacarpophalangeal (MCP) joint of right hand. Longitudinal ultrasonographic image obtained at the level of MCP joint shows an well-defined and thin walled anechoic cyst with posterior acoustic enhancement.

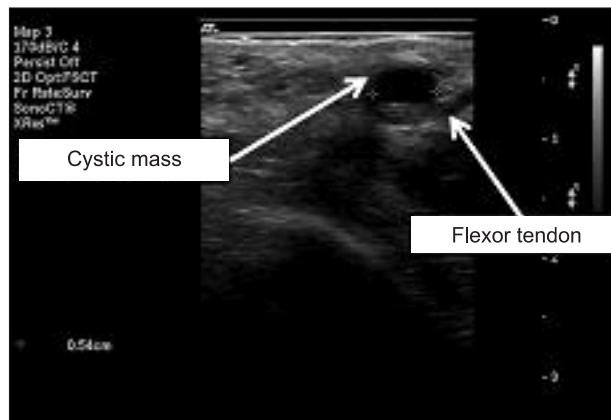


**Fig. 2.** Intraoperative findings. A ganglion of the flexor tendon sheath between the A1 and A2 pulley.

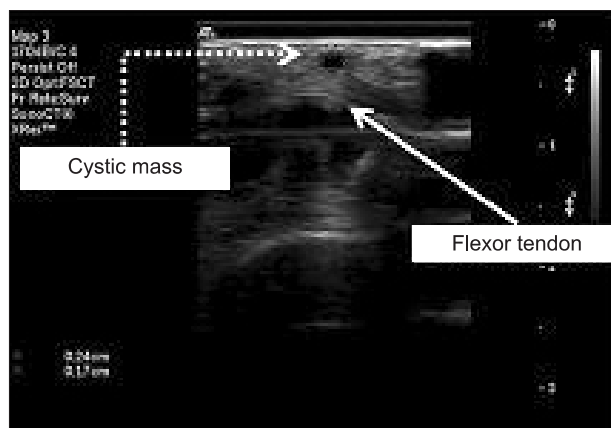
neurovascular structures. There are no complications or relapsed symptoms 3 years after the surgery so far.

### Case 2

A 36-year-old male patient had a palpable mass on the MCP joint area of his left ring finger for few months. He was a surgeon who uses his hand all day long but did not show any symptoms of pain or motion difficulties. A 0.3×0.5 cm sized cystic mass was detected between the A1 and A2 pulley near the flexor tendon sheath of 4th MCP joint in real-time ultrasonography (Fig. 3). The mass was disappeared on 4 year follow-up ultrasonography.



**Fig. 3.** Longitudinal ultrasonographic finding of a 36-year-old male patient's mass at the 4th metacarpophalangeal joint of left hand.



**Fig. 4.** Longitudinal ultrasonographic finding of a 6-month-old baby's mass at the 4th metacarpophalangeal joint of left hand.

### Case 3

A 6-month-old baby visited the hospital with his parents complaining of a soft mass palpated on 4th MCP joint area of his palm. A 0.2×0.3 cm sized cystic mass was detected between the A1 and A2 pulley of 4th MCP joint (Fig. 4). No trigger finger has been observed although an accurate physical examination was difficult to be done and we are still observing with a regular check-up.

## DISCUSSION

The ganglion of flexor tendon sheath seems to occur more commonly in young and middle-aged women with the greater prevalence in jobs using hands such as typist. The patients present with the clinical complaints of a painful,

tender, digital or palmar mass with average size of 3 to 10 mm. The etiology of the ganglion is unknown. Several theories include extrusion of synovial fluid from a defect in the joint capsule, myxoid degeneration and cyst formation in collagen connective tissue, increased production of hyaluronic acid by fibroblasts, and nonspecific proliferation of mesenchymal cells.<sup>4</sup> Nelson et al.<sup>5</sup> and others have suggested a traumatic etiology, with a preceding injury occurring in approximately half of all patients.<sup>6</sup>

The frequent occurrence of ganglion in a certain finger location can be explained with the hyperload theory. It usually occurs between the area of A1 pulley and A2 pulley with the frequency of occurrence which arises from A1 pulley to A2 and to the gap between two pulleys. The A1 pulley induces high angular load and the A2 pulley functions to prevent from bowstring effect when the power grip strength contracts.<sup>3</sup>

Although magnetic resonance imaging (MRI) is known to be the most suited noninvasive tool to detect cysts that communicate with the joint, recent study has shown that ultrasonography is very accurate for distinguishing solid from cystic lesions and diagnosing ganglia.<sup>7</sup> It is a simple diagnostic tool which is accurate for detecting location, boundary, and components of ganglion with characteristics of well-defined margins, anechoic internal echotexture with posterior acoustic enhancement, and absence of internal vascularity on power Doppler imaging.<sup>8-10</sup> Ultrasonography has several advantages over MRI: it is relatively economic, time saving, free from claustrophobia, and capable of demonstrating the lesion by dynamic real-time examination.

Most of asymptomatic ganglion on hand is treated conservatively and symptomatic ganglion on the other hand, is treated with either non-operative strategy such as direct compression, simple aspiration, steroid injection or surgery. In surgical excision, it is important to identify the connection between ganglion and joint space, and to excise this communication completely with thorough dissection to prevent recurrence.

We have experienced two cases of asymptomatic ganglia and one case of symptomatic ganglion found in MCP joint of ring finger. The fact that 6 months old baby was found to have ganglion on his finger cannot be explained by the hyperload theory from other studies, and it would be

proper to consider as congenital ganglion. Two patients with asymptomatic ganglia was sized less than 0.5 cm and had no digital triggering with full active digital range of motion in real-time ultrasonography. The symptomatic ganglion was located on Camper's chiasm where flexor digitorum profundus tendon and flexor digitorum superficialis crosses. The triggering was observed when 1.0 cm sized mass passed through the pulley.

From our experience, the real-time ultrasonography would be an excellent diagnostic tool in determining the way of treatment in flexor tendon sheath ganglia. We can not only confirm the presence of a mass and anatomic relationship with adjacent structures, but also check associated symptoms at once. Consequently, after diagnosing with real-time ultrasonography, we suggest that surgical treatment should be chosen for symptomatic ganglion especially with triggering, and conservative treatment for the asymptomatic small sized ganglion as there is possibility of spontaneous regression as we have shown in our case. Long-term follow up studies with more cases are needed about the flexor tendon sheath ganglion as the relationship between its size and symptom is not well known.

## ACKNOWLEDGEMENTS

This work was supported by the Soonchunhyang University Research Fund.

## REFERENCES

1. Herrington JL Jr, Edwards LW. Ganglion cysts arising in unusual locations. *Ann Surg* 1955;142:900-3.
2. Jebson PJ, Spencer EE Jr. Flexor tendon sheath ganglions: results of surgical excision. *Hand (N Y)* 2007;2:94-100.
3. Abe Y, Watson HK, Renaud S. Flexor tendon sheath ganglion: analysis of 128 cases. *Hand Surg* 2004;9:1-4.
4. Pendleton B, Carl B, Pollay M. Spinal extradural benign synovial or ganglion cyst: case report and review of the literature. *Neurosurgery* 1983;13:322-6.
5. Nelson CL, Sawmiller S, Phalen GS. Ganglions of the wrist and hand. *J Bone Joint Surg Am* 1972;54:1459-64.
6. al-Khawashki H, Hooper G. The distribution of fibrous flexor sheath ganglions. *J Hand Surg Br* 1997;22:226-7.
7. Teefey SA, Middleton WD, Patel V, Hildebolt CF, Boyer MI. The accuracy of high-resolution ultrasound for evaluating focal lesions of the hand and wrist. *J Hand Surg Am* 2004;29:393-9.

8. Lin CS, Wang TG, Shieh JY, Chen WS. Accuracy of sonography in the diagnosis of superficial ganglion cyst and lipoma. *J Med Ultrasound* 2009;17:107-13.
9. Päivänsalo M, Jalovaara P. Ultrasound findings of ganglions of the wrist. *Eur J Radiol* 1991;13:178-80.
10. Bianchi S, Abdelwahab IF, Zwass A, Giacomello P. Ultrasonographic evaluation of wrist ganglia. *Skeletal Radiol* 1994;23:201-3.