

## Acute Aortic Dissection in Pregnancy with the Marfan Syndrome

Si Wook Kim, M.D., Dohun Kim, M.D., Jong-Myeon Hong, M.D.

Acute aortic dissection (AAD) during pregnancy can be fatal to both the pregnant mother and the baby, particularly in patients with the Marfan syndrome. We report a case of the modified Bentall procedure in surgery for AAD in a 31-year-old pregnant woman at 24 weeks of gestation with the Marfan syndrome. The patient recovered well after the operation, but unfortunately, the fetus could not be saved.

Key words: 1. Aortic dissection  
2. Pregnancy  
3. Aortic valve surgery

### CASE REPORT

A 31-year-old woman was transferred at 24 weeks of gestation to Chungbuk National University Hospital from a local obstetric clinic because of suspicious acute aortic dissection (AAD). She had previously been diagnosed as pregnancy with Marfan's syndrome; she then underwent a routine check-up. Her chest pain had developed 3 days prior, and she was examined by transthoracic echocardiography immediately. On arriving in Chungbuk National University Hospital, the mental status of the patient was clear and her vital signs were stable: heart rate of 120 beats/min, blood pressure of 125/76 mmHg, and respiratory rate of 22 breaths/min with 96% SpO<sub>2</sub> in the room air. Urgent chest computed tomography revealed AAD (DeBakey type II) from the level of the Valsalva sinuses to the distal ascending aorta involving the right coronary orifice, without mediastinal hematoma or pleural effusion. The diameter of the ascending aorta was 52 mm at the sinotubular junction, and the annulus of the aortic valve was 33 mm (Fig. 1). On transthoracic echocardiog-

raphy, the ejection fraction was 65% and moderate aortic regurgitation was observed. The fetal sonography was normal. Emergency operation with the fetus in the uterus was decided upon. Under general anesthesia, cardiopulmonary bypass was instituted by draining blood from the right atrium and perfusion into the femoral artery. The intraoperative finding was that the thin adventitia was bearing the vertically dissected aortic wall, involving the right coronary orifice (Fig. 2). A modified Bentall procedure was performed with fetal heart monitoring simultaneously. We made an effort to maintain the blood pressure at above 80 mmHg of systolic pressure during operation while keeping the body temperature over 32°C. We were able to keep the fetal heart beating well until the second cardiac arrest with moderate hypothermia for the bleeding control of the anastomotic site of the right coronary button. The bleeding was not controllable while maintaining the heart beat because of the repeated tearing of the dissected fragile button area through suturing, and the mother's life was at risk. We controlled the bleeding site of the new right coronary orifice with an autologous pericardial patch and per-

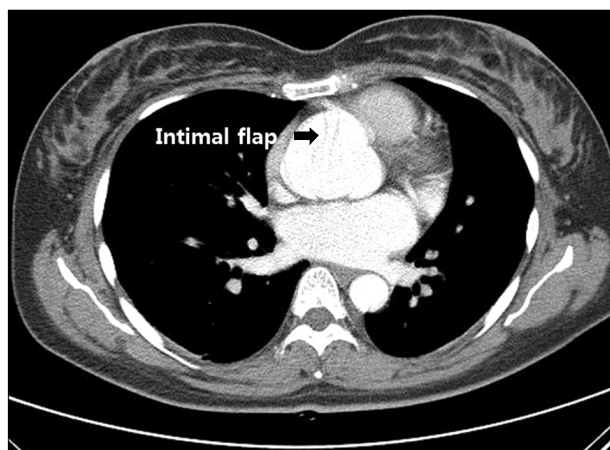
Department of Thoracic and Cardiovascular Surgery, Chungbuk National University College of Medicine

Received: January 29, 2014, Revised: March 12, 2014, Accepted: March 18, 2014, Published online: June 5, 2014

Corresponding author: Jong-Myeon Hong, Department of Thoracic and Cardiovascular Surgery, Chungbuk National University College of Medicine, 52 Naesudong-ro, Heungdeok-gu, Cheongju 361-804, Korea  
(Tel) 82-43-269-6304 (Fax) 82-43-269-6069 (E-mail) [jmhong@chungbuk.ac.kr](mailto:jmhong@chungbuk.ac.kr)

© The Korean Society for Thoracic and Cardiovascular Surgery. 2014. All right reserved.

© This is an open access article distributed under the terms of the Creative Commons Attribution Non-Commercial License (<http://creativecommons.org/licenses/by-nc/3.0>) which permits unrestricted non-commercial use, distribution, and reproduction in any medium, provided the original work is properly cited.

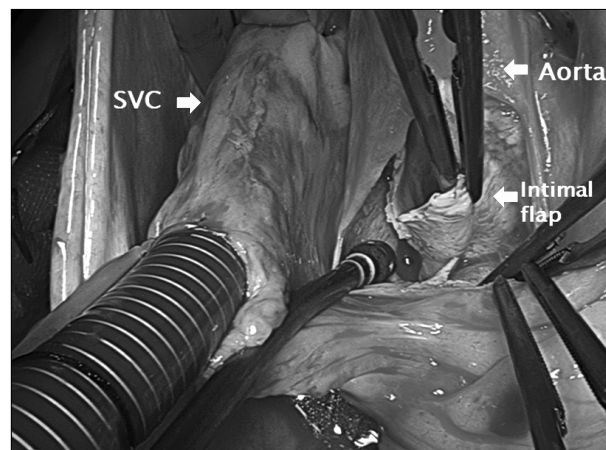


**Fig. 1.** An axial view of chest angio-computed tomography demonstrates acute aortic dissection in the proximal ascending aorta.

formed bypass grafting (ascending aorta to right coronary artery with a saphenous vein graft). After this second cardiac arrest, we could not hear the fetal heart sound. The fetus was aborted and evacuated postoperatively 4 days later. After 6 days in the intensive care unit, the patient was transferred to the general ward and discharged on postoperative day 20 uneventfully.

## DISCUSSION

Acute aortic dissection in pregnancy can occur in association with bicuspid aortic valve disease or connective tissue disease such as the Marfan syndrome. Increased cardiovascular stress by pregnancy was known as an important factor of an emergent aortic event. It is very rare but often results in significant mortality and morbidity for the mother and the fetus. Therefore, careful urgent surgery with the coordination of anesthesiology, neonatology, and obstetrics is essential. It is well known that the heart rate, stroke volume, cardiac output, and left ventricle (LV) wall mass increase during pregnancy, particularly in the third trimester period, which creates a maximally stressful condition hemodynamically. There have been some explanations suggested for the hemodynamic stresses during pregnancy, which are that the gravid uterus causes compression of the aorta and iliac arteries and increases the afterload of the LV, and some hormonal changes result in the loss of the normal function of



**Fig. 2.** Intraoperative finding reveals a dissection flap in the non-coronary and right coronary cusp area. SVC, superior vena cava.

the aortic elastic fibers [1-3].

Acute aortic dissection during pregnancy has a very low incidence of 0.4 cases per 100,000 person years within the female population in the age range of 15 to 45 years, but it can be fatal to both the pregnant woman and the baby, particularly with the Marfan patient [4,5]. Regarding the treatment of the aortic aneurysms during pregnancy, Immer et al. [5] found that aortic root enlargement of more than 4 cm or an increase in the aortic root size during pregnancy in the case of the Marfan syndrome or bicuspid aortic valve disease is associated with a considerable risk for the occurrence of type A dissection. They recommended delivery of the baby by a cesarean section, and aortic root surgery should be done a few days after delivery. Before 30 weeks of gestation, they proposed an aortic operation with the fetus in the uterus [5,6]. During the aortic operation in this situation, a high-flow, high-pressure normothermic perfusion with the use of intraoperative fetal heart beat monitoring (cardiotocography) is recommended for the fetus. Favorable results have been reported in the literature by adapting this modality of treatment for pregnant patients, keeping the fetus in the uterus [7,8]. Even though we could not save the fetal life in this case, we kept the fetal heart beating well until the second cardiac arrest with bleeding control of the anastomotic site of the right coronary button. It was not controllable while keeping the heart beating because of the repeated tearing of the

suture points, which were very fragile due to the dissected tissue. For the bleeding control of the weak area due to the dissection, bioglue injection into the false lumen could be recommended.

## CONFLICT OF INTEREST

No potential conflict of interest relevant to this article was reported.

## ACKNOWLEDGMENTS

This work was supported by the research grant of Chungbuk National University in 2012.

## REFERENCES

1. Lee SS, Jung TE, Lee DH. *Acute type II aortic dissection with severe aortic regurgitation and chronic descending aortic dissection in pregnant patient with Marfan syndrome.* Korean J Thorac Cardiovasc Surg 2012;45:404-7.
2. Hwang UD, Chung CH, Ryu YG, Lim J. *A case report of acute type II aortic dissection in a patient with Marfan's syndrome and who was 24 weeks pregnant: a case report.* Korean J Thorac Cardiovasc Surg 2007;40:508-11.
3. Vranes M, Velinovic M, Kovacevic-Kostic N, Savic D, Nikolic D, Karan R. *Pregnancy-related aortic aneurysm and dissection in patients with Marfan's syndrome: medical and surgical management during pregnancy and after delivery.* Medicina (Kaunas) 2011;47:604-6.
4. Thalmann M, Sodeck GH, Domanovits H, et al. *Acute type A aortic dissection and pregnancy: a population-based study.* Eur J Cardiothorac Surg 2011;39:e159-63.
5. Immer FF, Bansi AG, Immer-Bansi AS, et al. *Aortic dissection in pregnancy: analysis of risk factors and outcome.* Ann Thorac Surg 2003;76:309-14.
6. Barrett JM, Van Hooydonk JE, Boehm FH. *Pregnancy-related rupture of arterial aneurysms.* Obstet Gynecol Surv 1982;37:557-66.
7. Mul TF, van Herwerden LA, Cohen-Overbeek TE, Catsman-Berrevoets CE, Lotgering FK. *Hypoxic-ischemic fetal insult resulting from maternal aortic root replacement, with normal fetal heart rate at term.* Am J Obstet Gynecol 1998;179(3 Pt 1):825-7.
8. Becker RM. *Intracardiac surgery in pregnant women.* Ann Thorac Surg 1983;36:453-8.