

RESEARCH ARTICLE

Shorter Distance Between the Nodule and Capsule has Greater Risk of Cervical Lymph Node Metastasis in Papillary Thyroid Carcinoma

Qiu-Cheng Wang¹, Wen Cheng^{1*}, Xin Wen¹, Jie-Bing Li¹, Hui Jing¹, Chun-Lei Nie²

Abstract

Background: The purpose of this study was to assess the relationship between different sonographic features of papillary thyroid carcinoma (PTC) on high-frequency ultrasound and cervical lymph node metastasis (CLNM). **Materials and Methods:** We enrolled 548 patients who underwent initial surgery for PTC between May 2011 and December 2012 in our hospital at diagnosis. The sonographic features of 513 PTC nodules in 513 eligible patients, who had single PTC nodules in their thyroid glands, were retrospectively investigated. All patients with a suspect malignant nodule ($d < 0.5\text{cm}$) among multiple nodules were initially diagnosed by fine-needle aspiration biopsy (FNAB) to ascertain if the suspect nodule was PTC. The final diagnosis of all the thyroid nodules and existence of CLNM were based on postoperative pathology. Patients were divided into two groups: a positive group with CLNM (224 nodules) and a negative group without CLNM (289 nodules). The following factors were investigated: gender, age, echogenicity, echotexture, size, shape, location, margin, contour, calcification morphology, distance between the nodule and pre- or post-border of the thyroid capsule, vascularity and the differences between the two groups. **Results:** Correlation analysis showed that shorter distances between the nodule and pre- or post-border of thyroid capsule resulted in greater risk of CLNM (Spearman correlation coefficient = -0.22 , $p < 0.0001$). The significant factors in multivariate analysis were age < 45 yrs, larger size ($d > 1\text{cm}$), “wider than tall” shape, extrathyroid extension and mixed flow (internal and peripheral) ($p < 0.05$, OR = $0.406, 2.093, 0.461, 1.610, 1.322$). **Conclusions:** Significant sonographic features of PTC nodules in preoperative high-frequency ultrasound are crucial for predicting CLNM.

Keywords: Papillary thyroid carcinoma - ultrasonography features - location - cervical lymph node metastasis

Asian Pac J Cancer Prev, **15** (2), 855-860

Introduction

Papillary thyroid carcinoma (PTC), the most common malignant thyroid tumor, is generally indolent but very frequently metastasizes to the cervical lymph node (CLN) (Noguchi et al., 1970; Cooper et al., 2009). A large number of studies report that the initial lymph node is involved in 30–90% of patients, and it is revealed by pathologic examination that there were high rates of central CLNM (57.9%) and lateral CLNM (25.6%) in patients with PTC (Kupferman et al., 2004; Caron et al., 2005; Roh et al., 2009). Patients with CLNM have an increased chance of recurrence and a low survival rate (Beasley et al., 2002; Mazzaferri et al., 2003; Machens et al., 2003; Lundgren et al., 2006; Ito et al., 2009; Rotstein, 2009). Prophylactic lymph node dissection presents many controversies, prompting a search for a more formal standard provided for surgeons to follow.

Ultrasonography is considered to be the most valuable option for depicting the characteristics of thyroid nodules due to its ability to differentiate between benign and

malignant nodules (Frates et al., 2005; Frates et al., 2006; Hong et al., 2010), but the sensitivity of ultrasound in detecting CLNM is not very high (Roh et al., 2009). In recent years, preoperative ultrasonography has been reported to be an important in predicting CLNM of PTC (Ito et al., 2005; Kuna et al., 2006; González et al., 2007; Zhan et al., 2012). Improving the prediction of CLNM and understanding the correlation between the sonographic features of PTC and CLNM would have strong clinical significance. However, few is known to us about the sonographic features that significantly predict the risk of CLNM. The purpose of this study was to retrospectively investigate the predictive factors of the sonographic features of PTC nodules and their correlation with CLNM.

Materials and Methods

An appropriate institutional review board approved the experiment, and that informed consent was obtained from the subjects and from parents. Permission was obtained from the hospital to review the patients' medical records

¹Department of Cancer Hospital Ultrasound, ²Department of Cancer Hospital Thyroid Surgery, University of Harbin Medical, Harbin, China *For correspondence: chengwen69@yahoo.com

including images and data. We enrolled 548 patients who underwent initial surgery for PTC at diagnosis between May 2011 and December 2012 in our hospital. Patients with multiple and suspect malignant nodules were initially diagnosed by fine-needle aspiration biopsy (FNAB) to ascertain if the suspect nodule is PTC. The postoperative pathology diagnosis of nodules and CLN was regarded as gold standard. The sonographic features of 513 PTC nodules in 513 patients, who had single PTC nodule in thyroid gland, were retrospectively investigated finally. Patients with multiple malignant thyroid nodules and/or with other pathological diagnoses (follicular or medullary carcinoma, et al) were excluded from our investigation. The 513 eligible patients consisted of 81 men and 432 women with a mean age of 43.42 years (range of 15-79 years). The total number of PTC nodules was 513, with a mean diameter of 1.12cm (range of 0.1-5.6 cm).

The thyroid surgical approach was based on sonographic exam results and intraoperative frozen pathology results of the thyroid nodules and lymph nodes. All 513 patients underwent thyroidectomy or lobectomy. Prophylactic central neck dissection was performed on all patients and those with suspicious positive lateral LNM by intraoperative evaluation received a lateral neck lymph nodes dissection. The thyroid gland and neck were studied by preoperative ultrasonography and Color Doppler examination. The sonographic features of PTC nodules were analyzed and finally diagnosed by two or three radiologists.

All patients underwent routine preoperative thyroid examination using ultrasound (PHILIPS HDI 5000; Philips Medical Systems, Bothell, WA) with a probe frequency of 7-15 MHz and an 8–15 MHz linear array transducer (Acuson Sequoia; Siemens Medical Solutions, Mountain View, CA). All patients received a routine preoperative thyroid ultrasound with assessment of the sonographic features of the thyroid nodules. Patients were placed in the supine position, and the anterior area of the neck was fully exposed. The entire thyroid gland and lesions were scanned in transverse and longitudinal ultrasonographic plans. Sonographic features were valued according to the followed aspects: echogenicity, echo structure, size, shape, location, margin, contour, calcification morphology, distance between the nodule and pre- or post- border of the thyroid capsule and vascularity of the thyroid nodules. 1) Echogenicity was classified as hypo-, iso-, or hyperechoic. Echogenicity of the thyroid nodule was compared with submandibular, muscle or thyroid gland. 2) Echotexture was classified as solid or with cystic element(s). 3) The tumor maximal diameter was classified as ≤ 1 cm or > 1 cm. 4) The tumor shape was classified as “taller than wide” or “wider than tall”. A “taller than wide” shape was defined as a ratio of ≥ 1 , while the other was < 1 , calculated by dividing the anteroposterior diameter by the transverse diameter. 5) The location was defined as upper, middle or lower pole. 6) Nodules were classified as located in the right gland or isthmus near to right gland, left gland or isthmus near to left gland. 7) The margin was classified as regular, blurred or spicular. 8) The contour was classified as non-, macro- or micro-lobular. 9) Calcification morphology was classified as none, single micro- or multimicrocalcification

($d \leq 2$ mm), macrocalcification ($d > 2$ mm). 10) The distance between the nodule and pre- or post-border of the thyroid capsule was defined as an extrathyroid extension and $D < 0.1$ cm, $D = 0.1$ cm, $D = 0.2$ cm, $D = 0.3$ cm, or $D > 0.3$ cm. 11) Vascularity was defined as none, internal, peripheral or mixed flow (with both internal and peripheral flow).

The diagnostic sonographic features of suspected malignant thyroid nodules included hypoechoic lesions, “taller than wide” shape, blurred or spicular margin, micro-lobular contour, single or multi- microcalcification, with both internal and peripheral flow and extrathyroid extension with capsule being invaded or an interrupted and discontinuous echogenicity of a capsule. Patients with suspect malignant nodule ($d < 0.5$ cm) among multiple nodules were initially diagnosed by fine-needle aspiration biopsy (FNAB) in order to ascertain if the suspect nodules among the multiple nodules were PTC and be favorable of the retrospective investigation. The ultrasonography of neck was also performed, but it was only a reminder for surgery but not a final judgment criteria. Postoperative histopathologic was regarded as the “gold standard” to finally determine if a thyroid nodule was PTC and the existence of CLNM. The above eleven aspects as well as patients’ age and gender were all considered in the statistical analysis to find out which features and relationship with CLNM.

Statistical analysis was performed with SPSS version 17.0. Spearman correlation analysis was used to showed correlation with the distance between the nodule and thyroid capsule and CLNM. χ^2 analysis was used to evaluate for all the factors. For nodules located in upper, middle or lower pole and its relationship with CLNM, partition of χ^2 statistics analysis was used. For multivariate analysis, multivariate logistic regression analysis was employed. P values < 0.05 or < 0.017 were considered statistically significant.

Results

Table 1 presents the spearman correlation analysis for the factor distance between the PTC nodules and the pre- or post-border of thyroid capsule for predicting CLNM. Shorter distances between the nodule and the pre- or post-border of the thyroid capsule results in a greater risk of CLNM (Spearman correlation coefficient= -0.22 , $p < 0.0001$).

In the 513 total cases, 224 cases were found with CLNM (46 men and 178 women), yet 289 were found without CLNM (35 men and 254 women) (Table 2). For age less than 45yrs, 150 cases were with CLNM (54.3%, 150/276). For people older than 45yrs, 74 cases were with CLNM (31.2%, 74/237) (Table 2). It was concluded in table 2 that men as well as patients younger than 45yrs also showed a significant correlation with CLNM.

The differences between positive group and negative group and theirs relationship with sonographic features were investigated. Table 2 showed that tumor size larger than 1cm, micro-calcifications, “wider than tall” tumors and mixed flow were all significantly more frequent in positive group ($p < 0.05$) than in negative group. That is, univariate analysis showed that the above factors

Table 1. Correlation Between Distance Between the PTC Nodules and Pre- or Post- Border of Thyroid Capsule and the Two Groups

| Correlation feature | (-) | (+) | % | Spearman correlation coefficient | <i>p</i> |
|---|-----|-----|--------------|----------------------------------|----------|
| Distance between the nodule and pre- or post- border of thyroid capsule | | | | -0.22 | <0.0001 |
| 0cm and Extrathyroid extension (+) | 60 | 83 | 58.0(83/143) | | |
| Extrathyroid extension (-)and <0.1cm | 96 | 78 | 44.8(78/174) | | |
| About 0.1cm | 31 | 17 | 35.4(17/48) | | |
| About 0.2cm | 41 | 21 | 33.9(21/62) | | |
| About 0.3cm | 30 | 19 | 38.8(19/49) | | |
| >0.3cm | 31 | 6 | 16.2(6/37) | | |

(+) stand for positive group: patients with CLNM; (-) stand for negative group: patients without CLNM

Table 2. Relationship Between the Two Groups and Various Features of PTC Patients

| Feature | (-) | (+) | % | <i>p</i> |
|--------------------------|-----|-----|---------------|----------|
| Gender | | | | 0.009 |
| Female | 254 | 178 | 41.2(178/432) | |
| Male | 35 | 46 | 56.8(46/81) | |
| Age | | | | <0.001 |
| <45 | 126 | 150 | 54.3(150/276) | |
| ≥45 | 163 | 74 | 31.2(74/237) | |
| Tumor size | | | | <0.001 |
| ≤1 | 208 | 93 | 30.9(93/301) | |
| >1 | 81 | 131 | 61.8(131/212) | |
| Calcification morphology | | | | <0.001 |
| None | 110 | 56 | 33.7(56/166) | |
| Single micro | 43 | 27 | 38.6(27/70) | |
| Multi- micro | 104 | 123 | 54.2(123/227) | |
| Macro | 32 | 18 | 36.0(18/50) | |
| Vascularity | | | | <0.001 |
| None | 126 | 52 | 29.2(52/178) | |
| Internal | 33 | 23 | 41.1(23/56) | |
| Peripheral | 89 | 69 | 43.7(69/158) | |
| Mixed | 141 | 80 | 66.1(80/121) | |
| Shape | | | | <0.001 |
| Taller than wide | 142 | 60 | 29.7(60/202) | |
| Wider than tall | 147 | 164 | 52.7(164/311) | |

Table 3. Multivariate Logistic Analysis for Factors Predicting CLNM in PTC Patients

| Factors | λ^2 | <i>p</i> | OR | 95%CI |
|------------------------------|-------------|----------|-------|--------------|
| Age <45 yrs | 20.51 | <0.0001 | 0.406 | 0.275, 0.600 |
| Larger size (<i>d</i> >1cm) | 11.242 | 0.0008 | 2.093 | 1.359, 3.224 |
| Wider than tall | 14.118 | 0.0002 | 0.461 | 0.308, 0.691 |
| Extrathyroid extension | 4.392 | 0.036 | 1.61 | 1.031, 2.515 |
| Mixed flow | 9.343 | 0.0022 | 1.322 | 1.105, 1.581 |

have independently relationship with CLNM. However, echogenicity, margin, contour, echotexture and location of tumors did not reach statistical significance between the two groups (*p*=0.159, 0.206, 0.086, 0.309, 0.444, *p*>0.05). Nodules located in right gland and left gland were respectively 274 and 239. Nodules located in right gland with CLNM were 109 (45.6%, 109/239) and nodules located in left gland with CLNM were 115 (42.0%, 115/274). It also shows that PTC nodules located in right or left gland have no significant differences in CLNM (*p*=0.408).

Additionally, We found that a tumor size less than 1cm was correlated with “taller than wide” than tumors larger than 1cm (143/301 vs. 59/301; 47.5% vs. 27.8%, *p*<0.001).

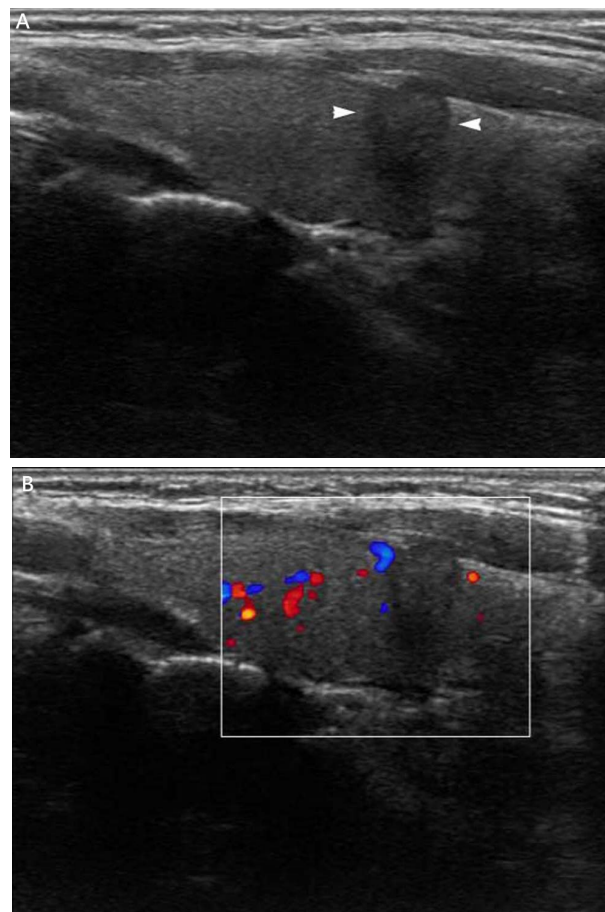


Figure 1. A: A 42-year-old man with solid-type nodule in the right thyroid gland (arrowhead). The tumor size was 7.5x8.3mm and sonographic feature showed spicular margins, “taller than wide” shape and extrathyroid extension. B. Peripheral flows were showed on color Doppler flow imaging (CDFI). The final diagnosis of postoperative pathology was PTC with multiple CLNM

It also revealed that tumor shape had the tendency of “wider than tall” with tumor growing, than is, larger size (*d*>1cm) may shows more frequently “wider than tall” shape than smaller size (*d*<1).

Although there was no significance between PTC nodules located in upper, middle or lower pole of thyroid gland and CLNM, there was relationship with central CLNM. Eleven (34.3%, 11/32) and 46 (63.0%, 46/73) PTC nodules located in the upper and middle poles respectively, metastasized to the central lymph node. The number of PTC nodes in the lower pole that metastasize

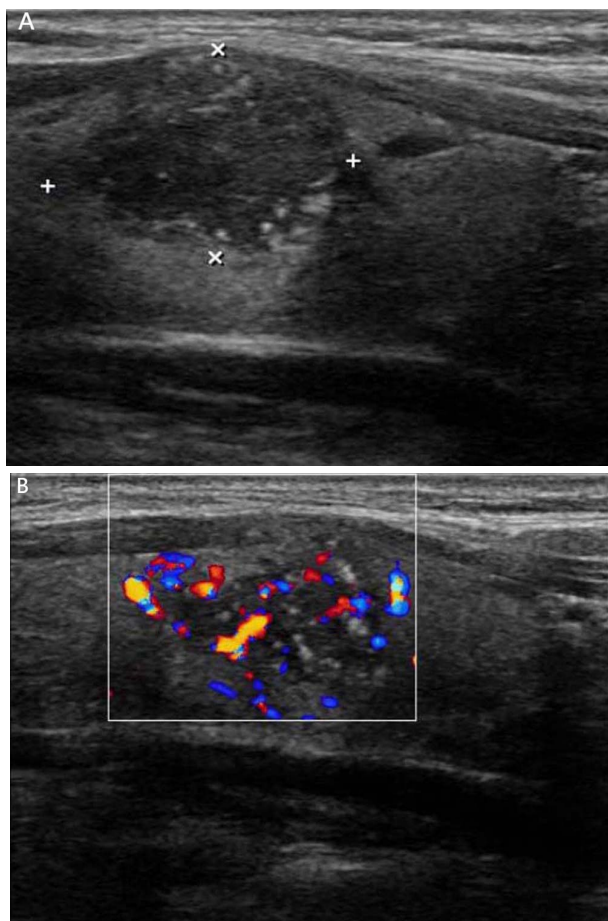


Figure 2. A: Symptomatic 28-year-old man with a 20.5x14.6mm solid-type mass in the right thyroid gland. The multi-microcalcification, “wider than tall” shape, interrupted and discontinuous echogenicity of the thyroid capsule were obvious on sonographic feature. B: There were internal and peripheral flow on CDFI. The final diagnosis of postoperative pathology was PTC with multiple CLNM

to the central lymph node was 46 (69.7%, 46/66). There were significant differences in the central CLNM between tumors located in the upper pole and in either middle or lower poles; the latter was significantly higher than the former ($p=0.007$, <0.01 , $p<0.017$). However, there were no significant differences in the central LNM between the groups with tumors located in the middle and lower poles ($p>0.017$).

Table 3 shows multivariate logistic regression analysis for factors predicting CLNM in PTC. The result showed that age <45 yrs, larger size ($d>1$ cm), wider than tall, extrathyroid extension and mixed flow (internal and peripheral) ($p<0.05$, OR=0.406, 2.093, 0.461, 1.610, 1.322) (Figure 1, 2) were risk factors of CLNM.

Discussion

The rate of preoperative ultrasonography in detecting non-palpable CLNM is not very high. It is because the complex structures in the central neck, the trachea with swallowed gasses, clavicle and sternum may make it difficult for ultrasonography to detect CLNM. In addition, the size of metastasizing lymph nodes is too small, which can easily be hid by thyroid gland and multifocal or

huge nodules. Due to the earlier metastasizing stage, the organization structure of macroscopic metastasizing lymph node can only be detected by histopathologic examination, the echotexture of which is still normal on sonogram. However, ultrasonography of thyroid nodules presently is a useful technique for differentiating or even diagnosing thyroid pathology and may be still very effective in predicting lymph node metastasis and distinguishing between tumor stages (Shimura H et al., 2005; Tae HJ et al., 2007; Kwak JY et al., 2008; Joo JY et al., 2012; Ito Y et al., 2013; Kim KE et al., 2013). High-frequency ultrasound can allow for the diagnosis of solid nodules smaller than 3mm and describe the sonographic features of nodules exactly. Therefore, it is preferable for radiologists to attempt to depict sonographic features exactly and particularly and to find out the relationship between the two. This study used ultrasonography to determine which sonographic features were associated with CLNM.

Being closer to the thyroid capsule increases the risk of CLNM there were for the nodules. Correlation analysis showed that shorter distances between the nodule and pre- or post-border of thyroid capsule resulted in greater risk of CLNM (Spearman correlation coefficient=-0.22, $p<0.0001$). Furthermore, according the p -value and odds ratio of table 3, extrathyroid extension is the second most related to CLNM. Extrathyroid extension has been widely considered to have a high risk of CLNM (Kwak et al., 2008; Choi et al., 2012; Joo et al., 2012; Patron et al., 2012; Zhan et al., 2012; Ito et al., 2013). Closer proximity to the capsule will offer more chances for tumors to touch those lymphatic vessels, thus contributing to metastasis of cancer cells along the lymphatic tubes. Therefore, when the PTC nodule is much closer to the capsule, the observation of a capsule being invaded or an interrupted and discontinuous echogenicity of a capsule happened, the more possible of CLNM should be reminded.

A total of 513 patients were investigated in this study. Of these patients, 56.8% (46/81) of men and 41.2% (178/432) of women as well as 54.3% (150/276) of those patients younger than 45 yrs and 31.2% (74/237) of those older than 45 yrs that were observed with CLNM. Numerous authors have also noted that younger patients are more likely to have CLNM than older subjects (Ahuja et al., 1991; Tisell et al., 1996; Lombardi et al., 2010; Vriens et al., 2011). Other authors suggest that the male gender has a tendency towards node metastasis (Besic et al., 2009; So et al., 2010). Therefore, male gender and younger than 45 yrs with suspicious thyroid nodules should be paid more attentions on the CLN during the operation.

It was reported that tumor size is the strongest predictor of LCNM (Ito et al., 2013). In this study, tumor size do has most relationship with CLNM according the result of logistic regression analysis ($p=0.0008$, OR=2.093). It showed that tumor shape had the tendency of “wider than tall” with tumor growing. Multivariate analysis revealed that tumor size larger than 1cm together with “wider than tall” shape were risk factors of CLNM.

A “taller than wide” shape in thyroid nodules is an independent factor and possibly the best one for predicting malignancy (Alexander et al., 2004; Cappelli et al., 2005;

Moon et al., 2010). But, it was reported that there was no significant difference in nodule shape (ratio \geq 1 vs. <1) between the positive and negative groups (Zhan et al., 2012). However, this finding showed that the “wider than tall” shape had a statistical relationship with CLNM ($p=0.0002$, OR=0.461). The possible reasons are as follows: 1) Corresponding with prior studies and this study, micro-carcinomas ($d\leq 1$ cm) preferred “taller than wide” more than macro-carcinomas ($d> 1$ cm) (Moon et al., 2008; Choi et al., 2012). Tumors larger than 1cm tended to grow along with the transverse axis, which would change the shape from “taller than wide” into the other. Simultaneously, tumor size larger than 1cm was also a significant predictor for CLNM (Zhan et al., 2012; Ito et al., 2013). 2) The “wider than tall” shape indicates that the orientation of the long the axis of tumor is parallel to the thyroid capsule. Thyroid capsules are divided into two layers; the inner layer is a connective tissue that is very close to the thyroid tissue. The inner thin layer can form several fiber bundles deep-inserted into the glands intraparenchymal, within which there is a large number of blood and lymphatic vessels. This arrangement increases the likelihood of contract with the thyroid capsule, thus, a greater chances of extrathyroid extent for tumors and CLNM would result (Joo et al., 2012; Zhan et al., 2012; Ito et al., 2013).

There are also several limitations of this study, including its retrospective design. Because CT was not performed, patients without suspicion lateral CLNM did not undergo prophylactic lateral neck dissection, yet they may be with occult or skip lateral CLNM. Furthermore, as a single institution study, there may be selection bias. Moreover, the number of patients was not large enough. To overcome these drawbacks, a multi-institution study would be more representative, and a larger number of cases would be collected with purpose henceforth; more studies should be performed.

In conclusion, this study suggests that preoperative thyroid ultrasonography can be used in depicting PTC to predict lymph node metastasis to provide more information and clinical reference for surgical program development. Larger size, younger age, male gender, multifocal microcalcification, “wider than tall” tumors, extrathyroid extension and mixed flow were significantly more frequent in the metastatic group than in the non-metastatic group. Careful examination of lymph nodes with thyroid nodules including the above expressions might be necessary.

Acknowledgements

First and foremost, all authors have made contributions significantly, and all authors agree with the content of the manuscript. I would like to show my deepest gratitude to Dr. Wen Cheng, a respectable, responsible and resourceful scholar, who has provided valuable guidance in every stage of the writing of this manuscript. His keen and vigorous academic observation enlightens me not only in this investigation but also in my future study. I shall extend my thanks to all the teachers in department of thyroid surgery for their kindness and help.

Last but not least, thanks to Miss Wen and Miss Li for their valuable discussion of the statistics.

References

- Ahuja S, Ernst H, Lenz K (1991) Papillary thyroid carcinoma: occurrence and types of lymph node metastases. *J Endocrinol Invest*, **14**, 543-9.
- Alexander EK, Marqusee E, Orcutt J, et al (2004) Thyroid nodule shape and prediction of malignancy. *Thyroid*, **14**, 953-8.
- Beasley NJ, Lee J, Eski S, Walfish P, Witterick I, Freeman JL (2002) Impact of nodal metastases on prognosis in patients with well-differentiated thyroid cancer. *Arch Otolaryngol Head Neck Surg*, **128**, 825-8.
- Basic N, Zgajnar J, Hocevar M, Petric R (2009) Extent of thyroidectomy and lymphadenectomy in 254 patients with papillary thyroid microcarcinoma: a single-institution experience. *Ann Surg Oncol*, **16**, 920-8.
- Caron NR, Clark OH (2005) Papillary thyroid cancer: surgical management of lymph node metastases. *Curr Treat Options Oncol*, **6**, 311-22.
- Cappelli C, Pirola I, Cumetti D, et al. (2005) Is the anteroposterior and transverse diameter ratio of nonpalpable thyroid nodules a sonographic criteria for recommending fine-needle aspiration cytology? *Clin Endocrinol*, **63**, 689-93.
- Cooper DS, Doherty GM, Haugen BR, et al. (2009) Revised American Thyroid Association management guidelines for patients with thyroid nodules and differentiated thyroid cancer. *Thyroid*, **19**, 1167-214.
- Choi Y, Park KJ, Ryu S, et al. (2012) Papillary thyroid carcinoma involving cervical neck lymph nodes: correlations with lymphangiogenesis and ultrasound features. *Endocrine J*, **59**, 941-8.
- Frates MC, Benson CB, Charboneau JW, et al. (2005) Management of thyroid nodules detected at US: Society of Radiologists in Ultrasound consensus conference statement. *Radiology*, **237**, 794-800.
- Frates MC, Benson CB, Doubilet PM, et al. (2006) Prevalence and distribution of carcinoma in patients with solitary and multiple thyroid nodules on sonography. *J Clin Endocrinol Metab*, **91**, 3411-17.
- González HE, Cruz F, O'Brien A, et al. (2007) Impact of preoperative ultrasonographic staging of the neck in papillary thyroid carcinoma. *Arch Otolaryngol Head Neck Surg*, **133**, 1258-62.
- Hong YJ, Son EJ, Kim EK, Kwak JY, Hong SW, Chang HS (2010) Positive predictive values of sonographic features of solid thyroid nodule. *Clin Imaging* **34**:127-133
- Ito Y, Tomoda C, Uruno T, et al. (2005) Ultrasonographically and anatomopathologically detectable node metastases in the lateral compartment as indicators of worse relapse-free survival in patients with papillary thyroid carcinoma. *World J Surg*, **29**, 917-20.
- Ito Y, Fukushima M, Tomoda C, et al. (2009) Prognosis of patients with papillary thyroid carcinoma having clinically apparent metastasis to the lateral compartment. *Endocr J*, **56**, 759-66.
- Ito Y, Fukushima M, Higashiyama T, et al. (2013) Tumor size is the strongest predictor of microscopic lymph node recurrence of N0 papillary thyroid carcinoma. *Endocr J*, **60**, 113-7.
- Joo JY, Park JY, Yoon YH, et al. (2012) Prediction of occult central lymph node metastasis in papillary thyroid carcinoma by preoperative BRAF analysis using fine-needle aspiration biopsy: a prospective study. *J Clin Endocrinol Metab*, **97**, 3996-4003.
- Kupferman ME, Patterson M, Mandel SJ, et al. (2004) Patterns of lateral neck metastasis in papillary thyroid carcinoma.

- Arch Otolaryngol Head Neck Surg*, **130**, 857-60.
- Kuna SK, Bracic I, Tesic V, et al. (2006) Ultrasonographic differentiation of benign from malignant neck lymphadenopathy in thyroid cancer. *J Ultrasound Med*, **25**, 1531-7.
- Kwak JY, Kim EK, Youk JH, et al. (2008) Extrathyroid extension of well-differentiated papillary thyroid microcarcinoma on US. *Thyroid*, **18**, 609-14.
- Kim KE, Kim EK, Yoon JH, et al. (2013) Preoperative prediction of central lymph node metastasis in thyroid papillary microcarcinoma using clinicopathologic and sonographic features. *World J Surg*, **37**, 385-91.
- Lundgren CI, Hall P, Dickman PW, et al. (2006) Clinically significant prognostic factors for differentiated thyroid carcinoma: a population-based, nested case-control study. *Cancer*, **10**, 524-31.
- Lombardi CP, Bellantone R, De Crea C, et al. (2010) Papillary thyroid microcarcinoma: extrathyroidal extension, lymph node metastases, and risk factors for recurrence in a high prevalence of goiter area. *World J Surg*, **34**, 1214-21.
- Mazzaferrri EL, Jhiang SM. (1994) Long-term impact of initial surgical and medical therapy on papillary and follicular thyroid cancer. *Am J Med*, **97**, 418-28.
- Machens A, Hinze R, Thomusch O, et al (2003) Pattern of nodal metastasis for primary and reoperative thyroid cancer. *World J Surg*, **26**, 22-8.
- Moon WJ, Jung SL, Lee JH, et al (2008) Benign and Malignant Thyroid Nodules: US differentiation--Multicenter Retrospective Study. *Radiology*, **247**, 762-70.
- Moon HJ, Kwak JY, Kim MJ, et al (2010) Can vascularity at power Doppler US help predict thyroid malignancy? *Radiology*, **255**, 260-9.
- Noguchi S, Noguchi A, Murakami N (1970) Papillary carcinoma of the thyroid. I. Developing pattern of metastasis. *Cancer*, **26**, 1053-60.
- Patron V, Hitier M, Bedfert C, et al (2012) Predictive factors for lateral occult lymph node metastasis in papillary thyroid carcinoma. *Eur Arch Otorhinolaryngol*, **270**, 2095-100.
- Roh JL, Park JY, Kim JM, et al (2009) Use of preoperative ultrasonography as guidance for neck dissection in patients with papillary thyroid carcinoma. *J Surg Oncol*, **99**, 28-31.
- Rotstein L (2009) The role of lymphadenectomy in the management of papillary carcinoma of the thyroid. *J Surg Oncol*, **99**, 186-8.
- Shimura H, Haraguchi K, Hiejima Y, et al. (2005) Distinct diagnostic criteria for ultrasonographic examination of papillary thyroid carcinoma: a multicenter study. *Thyroid*, **15**, 251-8.
- So YK, Son YI, Hong SD, et al (2010) Subclinical lymph node metastasis in papillary thyroid microcarcinoma: a study of 551 resections. *Surgery*, **148**, 526-31.
- Tae HJ, Lim DJ, Baek KH, et al (2007) Diagnostic value of ultrasonography to distinguish between benign and malignant lesions in the management of thyroid nodules. *Thyroid*, **17**, 461-6.
- Tisell LE, Nilsson B, Mölne J, et al (1996) Improved survival of patients with papillary thyroid cancer after surgical microdissection. *World J Surg*, **20**, 854-9.
- Vriens MR, Moses W, et al (2011) Clinical and molecular features of papillary thyroid cancer in adolescents and young adults. *Cancer*, **117**, 259-67.
- Zhan WW, Zhou P, Zhou JQ, et al (2012) Differences in sonographic features of papillary thyroid carcinoma between neck lymph node metastatic and non-metastatic groups. *J Ultrasound Med*, **31**, 915-20.