

# The Manufacture of Custom Made 3D Titanium Implant for Skull Reconstruction

Hyung Rok Cho, M.D.<sup>1</sup>, In Sik Yun, M.D., Ph.D.<sup>2</sup>, Kyu Won Shim, M.D., Ph.D.<sup>3</sup>, Tai Suk Roh, M.D., Ph.D.<sup>2</sup>, Yong Oock Kim, M.D., Ph.D.<sup>1</sup>

<sup>1</sup>Department of Plastic & Reconstructive Surgery, Institute for Human Tissue Restoration, Yonsei University College of Medicine, Seoul, Korea

<sup>2</sup>Department of Plastic & Reconstructive Surgery, Gangnam Severance Hospital, Yonsei University College of Medicine, Seoul, Korea

<sup>3</sup>Department of Neurosurgery, Yonsei University College of Medicine, Seoul, Korea

Nowadays, with advanced 3D printing techniques, the custom-made implant can be manufactured for the patient. Especially in skull reconstruction, it is difficult to design the implant due to complicated geometry. In large defect, an autograft is inappropriate to cover the defect due to donor morbidity. We present the process of manufacturing the 3D custom-made implant for skull reconstruction. There was one patient with skull defect repaired using custom-made 3D titanium implant in the plastic and reconstructive surgery department. The patient had defect of the left parieto-temporal area after craniectomy due to traumatic subdural hematoma. Custom-made 3D titanium implants were manufactured by Medyssey Co., Ltd. using 3D CT data, Mimics software and an EBM (Electron Beam Melting) machine. The engineer and surgeon reviewed several different designs and simulated a mock surgery on 3D skull model. During the operation, the custom-made implant was fit to the defect properly without dead space. The operative site healed without any specific complications. In skull reconstruction, autograft has been the treatment of choice. However, it is not always available and depends on the size of defect and donor morbidity. As 3D printing technique has been advanced, it is useful to manufacture custom-made implant for skull reconstruction.

**Key Words** Skull reconstruction · Custom-made implant.

**Received:** July 5, 2014 / **Revised:** July 11, 2014 / **Accepted:** July 15, 2014

**Address for correspondence:** In Sik Yun, M.D.

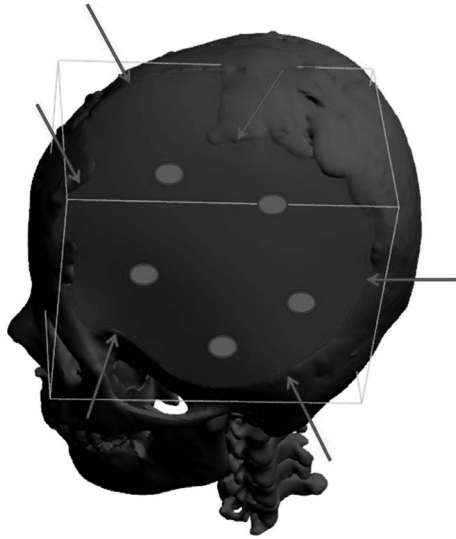
Department of Plastic & Reconstructive Surgery, Gangnam Severance Hospital, 211 Eonju-ro, Seoul, Korea

**Tel:** 02-2019-3423, **Fax:** 02-577-4914, **E-mail:** eqatom@yuhs.ac


## Introduction

The reconstruction of large calvarial defects is a necessary challenge for the plastic surgeon. Calvarial reconstruction should provide not only biomechanical stability but also cerebral protection. It is well known that an autologous bone is the best choice of treatment, but sometimes it cannot be used, especially in cases of large defects. Medical imaging has been developed and computer programming have allowed computer-assisted designed implants, which are fit to the defect without an error.<sup>1-3</sup> In this report, we present our experience of the process of the manufacturing custom-made 3D titanium implant.

In 2014, there was one patient with skull defect reconstructed by using custom-made 3D titanium implant. Custom-made 3D titanium implant was manufactured by Medyssey Co., Ltd. using 3D CT data, Mimics software, and an EBM (Electron Beam Melting) machine. CT was scanned with 1mm thickness and the data was investigated from the bone part of axial, sagittal and coronal plane. After then, 3D image was produced and implant was designed for the defect (Fig. 1). In designing process, the manufacturer and surgeon discussed the position of fixation, the amount of porosity and the figure of implant. When the manufacturing of the 3D implant was completed, the surgeon simulated the operation with it to the patient's rapid prototyping (RP) model (Fig. 2).



**Fig. 1.** 3D implant design process. 3D reconstruction of data was performed and implant was designed.



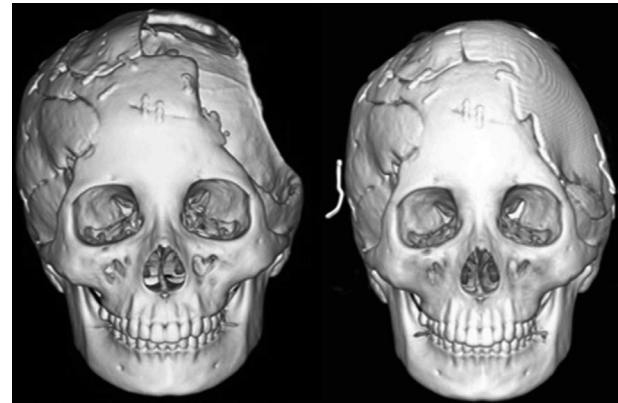
**Fig. 2.** Custom-made 3D titanium implants were manufactured by EBM (Electron Beam Melting) machine.

## Case Report

During the operation, we were able to confirm the custom-made 3D implant was exact fit for the skull defect without leaving any dead spaces. There was no complication on the operative wound and the depressed scalp was recovered. Patient satisfied with their result and postoperative facial CT was evaluated to confirm the position of implant.

### Case 1

The patient was a 21-year-old female with a calvarial defect in the left parieto-temporal area. She had a traffic accident and epidural hemorrhage was found. Craniectomy and cranioplasty with MedPor® was done. However, the implant had been removed due to infection. The defect size was 15×15 (cm<sup>2</sup>) and reconstruction was done with 3D titanium mesh. The postoperative



**Fig. 3.** Case 1. Preoperative 3D facial CT (Left), Postoperative 3D facial CT scan (Right).

follow-up was two months without complications (Fig. 3).

## Discussion

We reconstructed one case of calvarial defect successfully with custom-made 3D titanium implant. Although it was just one case and we did not look at the long term follow-up, custom-made implants can be considered a good option for skull reconstruction. The advantages such as the short operating time, no required special surgical techniques, and no donor site morbidity were well known.

In calvarial reconstructions, autograft was widely used among the many kinds of grafts. It is good for an osteoconduction.<sup>4</sup> However, it cannot be used in large defects and can cause donor site morbidity. Also, its result depends on the harvesting technique and the incidence rate of bone resorption ranges from 3% to 12%.<sup>5-7</sup> When resorption occurs, secondary operation is inevitable to compensate for the alteration.<sup>8,9</sup>

Titanium is strong enough to resist secondary trauma while providing maximal stability. Furthermore, it generally causes less inflammation, bonds with surrounding mineralized bone and has a biocompatibility.<sup>10-12</sup> However, due to its hardness, it is necessary to prefabricate the implant using computer-assisted design and manufacturing. A major concern in calvarial reconstruction has been the complex geometry which can affect preoperative planning and aesthetic outcome.<sup>13</sup> With advanced technology, computer-assisted designed titanium implants were introduced.<sup>14</sup> In our cases, the implants exactly fit the defect and properly covered the defect area without dead space.

This study has limitations, such as its small sample size and early follow-up. However, there was no complication and the patient was satisfied with their outcome functionally and aesthetically.

## Conclusion

Short operation time, exactly fitness to the defect and cosmetic outcome are advantages of this 3D printing method. In these aspects, custom-made 3D implants can be one of the best options for skull reconstruction.

## REFERENCES

1. Ono, I., Tateshita, T., Satou, M., Sasaki, T., Matsumoto, M. and Kodama, N. Treatment of large complex cranial bone defects by using hydroxyapatite ceramic implants. *Plast. Reconstr. Surg.* 1997; 104: 339
2. Eppley, B. L., Kilgo, M., and Coleman, J. J. Cranial reconstruction with computer-generated hard-tissue replacement patient-matched implants: Indications, surgical technique, and long-term follow-up. *Plast. Reconstr. Surg.* 2002;109: 864
3. D'Urso, P. S., Earwaker, W. J., Barker, T. M., M. J. Redmond, R. G. Thompson, D. J. Effeney, F. H. Tomlinson. Custom cranioplasty using stereolithography and acrylic. *Br. J. Plast. Surg.* 2000; 53: 200
4. Uwe Spetzger, Vassilios Vougioukas, Jorg schipper. Materials and techniques for osseous skull reconstruction. *Minimally Invasive Therapy.* 2010;19:110-121
5. Aarabi B, Hesdorffer DC, Ahn ES, Aresco C, Scalea TM, Eisenberg HM. Outcome following decompressive craniectomy for malignant swelling due to severe head injury. *J Neurosurg* 2006;104:469
6. Figaji AA, Fieggen AG, Peter JC: Early decompressive craniotomy in children with severe traumatic brain injury. *Childs Nerv Syst* 2003; 19:666
7. Kan P, Amini A, Hansen K, White GL Jr, Brockmeyer DL, Walker ML, Kestle JR. Outcomes after decompressive craniectomy for severe traumatic brain injury in children. *J Neurosurg* 2006;105:337
8. Moreira-Gonzalez A, Jackson IT, Miyawaki T, et al: Clinical outcome in cranioplasty: Critical review in long-term followup. *J Craniofac Surg* 2003;14:144
9. Grant GA, Jolley M, Ellenbogen RG, Roberts TS, Gruss JR, Loeser JD. Failure of autologous bone-assisted cranioplasty following decompressive craniectomy in children and adolescents. *J Neurosurg* 2004;100:163
10. Blake GB, MacFarlane MR, Hinton JW. Titanium in reconstruction of the skull and face. *Br J Plast Surg.* 1990;43:528–35.
11. Raza SM, Thai QA, Pradilla G, Tamargo RJ. Frontozygomatic titanium cranioplasty in frontosphenotemporal pterional craniotomy. *Neurosurgery* 2008;62:262–5.
12. Peter C. Neligan, Geoffrey C. Gurtner, *Plastic Surgery*, 3rd ed. New York: ELSEVIER; 2013. Vol 1,p787
13. Holck, D. E., Boyd, E. M., Hg, J., and Mauffray, R. O. Benefits of stereolithography in orbital reconstruction. *Ophthalmology* 106: 1214, 1999.
14. Winder, J., Cooke, R. S., Gray, J., Fannin, T., and Fegan, T. Medical rapid prototyping and 3D CT in the manufacturer of custom made cranial titanium plates. *J. Med. Eng. Tech.*1999; 23: 26