



A modified technique for extraoral cementation of implant retained restorations for preventing excess cement around the margins

Emir Yuzbasioglu*

Department of Prosthodontics, School of Dentistry, Istanbul Medipol University, Istanbul, Turkey

The major drawback of cement-retained restorations is the extrusion of the excess cement into the peri-implant sulcus, with subsequent complications. Insufficient removal of the excess cement may initiate a local inflammatory process, which may lead to implant failure. This article presents a method of controlling cement flow on implant abutments, minimizing the excess cement around implant-retained restorations. [*J Adv Prosthodont 2014;6:146-9*]

KEY WORDS: Excess cement; Cement retained restorations; Peri-implant disease

INTRODUCTION

The introduction of osseointegration and the use of endosseous implants provide alternative treatment options to clinicians for all indications of edentulism.¹ Implant-supported, fixed restorations are usually classified as screw- or cement-retained.^{2,3} The advantage of screw-retained restorations is the combination of a rigid connection between the restoration-abutment complex and its retrievability. However, these restorations are usually more expensive than cement-retained restorations because of the use of extra components and laboratory costs.⁴ Cement-retained restorations were introduced to compensate for problems of screw loosening and the lack of esthetics of screw-retained restorations.⁴ The lack of fastening screws in cement-retained restorations reduces the possibility of preload stress and screw loosening.⁵ The major advantages of cement-retained

restorations are the passive fit of frameworks, enhanced esthetics resulting from lack of screw access holes, and reduced complexity of laboratory procedures and chair-side time.⁶⁻⁸ The disadvantages of cement-retained restorations include the requirement for extra time for cementation, removal of residual excess cement, limited design possibilities for superstructure, and the reduced possibility for modifying treatment in case of periimplantitis.⁹

The existence of residual excess cement in peri-implant sulcus is a common complication of cement-retained implant prostheses.^{10,11} If there is excess cement located in the soft tissue deeper than 3 mm, it might be difficult to observe and remove. Insufficient removal of excess cement may result in swelling, soreness, exudation or bleeding on probing, and can initiate a local inflammatory process, which is evidence of peri-implant disease and can ultimately lead to implant failure.¹²⁻¹⁴ Moreover, removal of excess cement may cause scratching and gouging on the implant surfaces when plastic and metal scalers are used.¹⁵ Several authors have reported on techniques regarding procedures used to assist in minimizing residual excess cement extrusion.¹⁶⁻¹⁸

This article describes a method of controlling cement flow, using stock or custom implant abutments, when cement-retained implant-supported restorations are utilized. The method can be used easily and quickly at chair-side by the use of daily restorative and laboratory materials. The use of die spacers results in a uniform space between the crown restoration and the implant abutment.

Corresponding author:
Emir Yuzbasioglu
Department of Prosthodontics, School of Dentistry, Istanbul Medipol University, Istanbul, Turkey
Ataturk Bulvari No:27, Unkapani, 34083, Fatih, Istanbul, Turkey
Tel. 90 212 453 49 53; e-mail, eyuzbasioglu@medipol.edu.tr
Received December 23, 2013 / Last Revision March 10, 2014 / Accepted March 24, 2014

© 2014 The Korean Academy of Prosthodontics
This is an Open Access article distributed under the terms of the Creative Commons Attribution Non-Commercial License (<http://creativecommons.org/licenses/by-nc/3.0>) which permits unrestricted non-commercial use, distribution, and reproduction in any medium, provided the original work is properly cited.

TECHNIQUE

Check the marginal fit of the crown restoration to the implant analog on the dental model.

Apply die spacer into the intaglio surface of the crown restoration (Fig. 1A) according to the manufacturer's recommendations (Siladent Die Spacer 12 μ m Gold, Dr. Böhme & Schöps GmbH, Germany).

Repeat applying the die spacer until the desired cement film thickness is achieved (application of the die spacer 3-4 times forms a film thickness of approximately 45-50 μ m).

The die spacer must cover all intaglio surface of crown restoration (Fig. 1B, Fig. 1C).

Completely fill the crown restoration with a bis-acrylic temporary restorative material (Luxatemp Plus, DMG Chemisch-Pharmazeutische Fabrik GmbH, Germany) and put a retention pin (Bredent GmbH & Co. KG, Germany) with a smaller diameter tip into the uncured material to form a handle (Fig. 1D) and secure the retention pin until the bis-acrylic material is cured.

Remove the crown restoration and check any discrepan-

cies between the implant abutment and the bis-acrylic abutment. Check that there are no voids on the duplicate abutment, and that the finish line has been duplicated accurately (Fig. 1E, Fig. 1F).

Clean the intaglio surface of the crown restoration with air and check any residual die spacer.

Mix a desired luting agent (Temp Bond NE, KerrHawe S.A., Switzerland) and apply to the intaglio surface of the crown restoration (Fig. 2A, Fig. 2B)

Place the crown gently onto the bis-acrylic abutment and wipe off the excess cement with a cotton swab (Fig. 2C).

Remove the crown restoration from the bis-acrylic abutment. Note that there is a residual cement layer on the bis-acrylic abutment (Fig. 2D).

If there is a lack of cement layer, line the intaglio surface of the crown restoration with a thin layer of extra luting agent.

Place the implant restoration onto the implant abutment intraorally. There should be little or no excess cement.

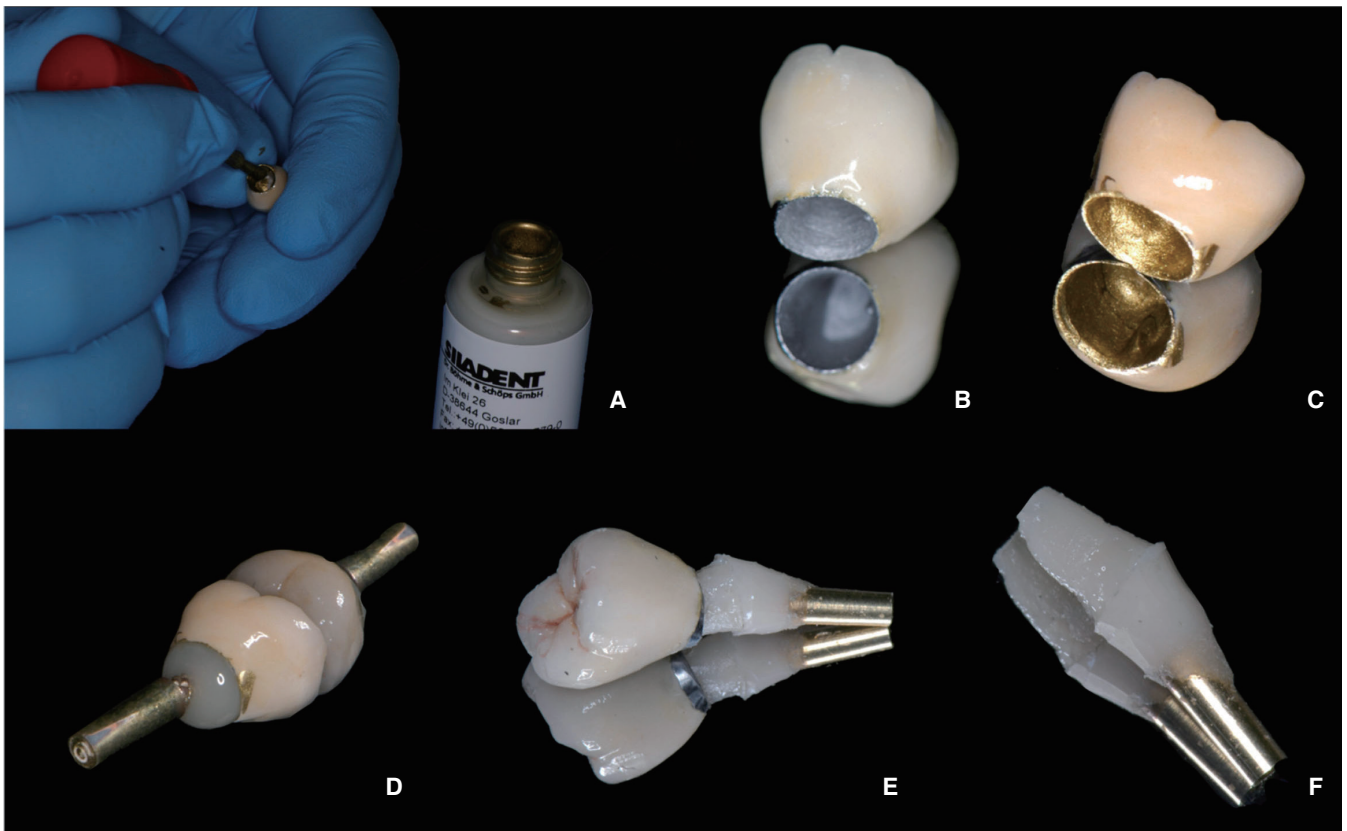


Fig. 1. (A) Application of die spacer into intaglio surface of crown restoration, (B) The crown restoration before and (C) after die spacer application, (D) Crown restoration was filled with a small amount of bis-acrylic temporary restorative material, (E) Check if the finish line has been duplicated accurately and (F) any discrepancies with the crown restorations.

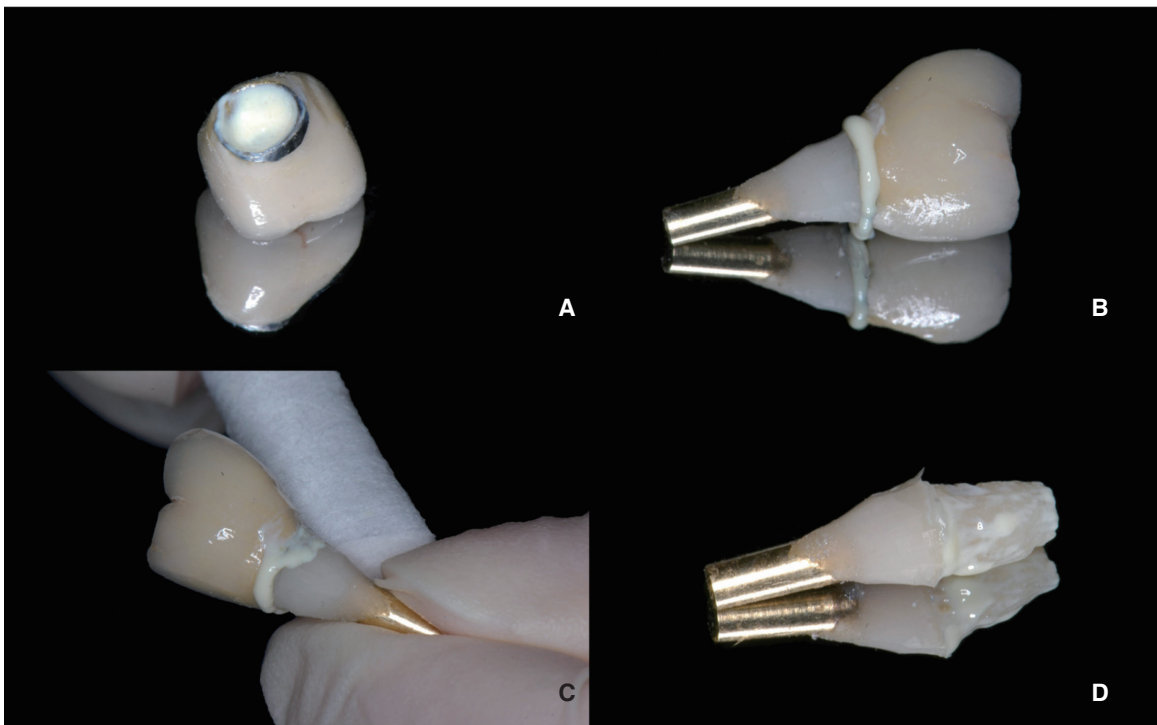


Fig. 2. (A) Crown restoration filled with small amount of cement, (B) Note the flow of Excess cement around the margin, (C) Wipe off the excess cement with a cotton swab, (D) Note residual cement layer on the bis-acrylic abutment.

SUMMARY

This article presents a method of minimizing the excess cement around implant-retained restorations. The advantage of the technique is allowing the control of cement flow by using a custom-made duplicate abutment that can be fabricated quickly, easily, and economically at the time of implant abutment/crown insertion.¹⁶ The major benefit of extraoral cementation is to allow the indirect removal of excess cement around the margins.

This clinical procedure is extremely important for avoiding the potential of peri-implant disease caused by residual cement left in the gingival sulcus. It is important not to form an oversized cement space when duplicating the implant abutment. The use of a die spacer provides a space of approximately 50 μm , which represents the ideal cement space, and may be used for both custom and pre-fabricated abutments.

The disadvantage of the technique is that it is a time-consuming procedure for routine clinical processes. Dumbrigue *et al.*¹⁶ stated that when the extraoral cementation technique is preferred, the luting agent must have a longer working time. When a custom abutment is to be used, the dental laboratory may be instructed to make an abutment analog using an acrylic resin, but this is time consuming for the technician and involves additional laboratory costs.¹⁸

REFERENCES

1. Brånemark PI, Zarb GA, Albrektsson T. Tissue-Integrated Prosthesis: Osseointegration in Clinical Dentistry. Chicago; Quintessence Publishing; 1985.
2. Wannfors K, Smedberg JI. A prospective clinical evaluation of different single-tooth restoration designs on osseointegrated implants. A 3-year follow-up of Brånemark implants. *Clin Oral Implants Res* 1999;10:453-8.
3. Eckert SE, Wollan PC. Retrospective review of 1170 endosseous implants placed in partially edentulous jaws. *J Prosthet Dent* 1998;79:415-21.
4. Avivi-Arber L, Zarb GA. Clinical effectiveness of implant-supported single-tooth replacement: the Toronto Study. *Int J Oral Maxillofac Implants* 1996;11:311-21.
5. Michalakis KX, Hirayama H, Garefis PD. Cement-retained versus screw-retained implant restorations: a critical review. *Int J Oral Maxillofac Implants* 2003;18:719-28.
6. Hebel KS, Gajjar RC. Cement-retained versus screw-retained implant restorations: achieving optimal occlusion and esthetics in implant dentistry. *J Prosthet Dent* 1997;77:28-35.
7. Jones JD, Kaiser DA. A new gingival retraction impression system for a one-stage root-form implant. *J Prosthet Dent* 1998;80:371-3.
8. Misch CE. Contemporary implant dentistry. 2nd ed. St. Louis; MO; Mosby-Year Book Inc; 1999. p. 549-73.
9. Breeding LC, Dixon DL, Bogacki MT, Tietge JD. Use of luting

- ing agents with an implant system: Part I. *J Prosthet Dent* 1992;68:737-41.
10. Quirynen M, De Soete M, van Steenberghe D. Infectious risks for oral implants: a review of the literature. *Clin Oral Implants Res* 2002;13:1-19.
 11. Lee A, Okayasu K, Wang HL. Screw- versus cement-retained implant restorations: current concepts. *Implant Dent* 2010; 19:8-15.
 12. Pauletto N, Lahiffe BJ, Walton JN. Complications associated with excess cement around crowns on osseointegrated implants: a clinical report. *Int J Oral Maxillofac Implants* 1999; 14:865-8.
 13. Gapski R, Neugeboren N, Pomeranz AZ, Reissner MW. Endosseous implant failure influenced by crown cementation: a clinical case report. *Int J Oral Maxillofac Implants* 2008;23:943-6.
 14. Wilson TG Jr. The positive relationship between excess cement and peri-implant disease: a prospective clinical endoscopic study. *J Periodontol* 2009;80:1388-92.
 15. Agar JR, Cameron SM, Hughbanks JC, Parker MH. Cement removal from restorations luted to titanium abutments with simulated subgingival margins. *J Prosthet Dent* 1997;78:43-7.
 16. Dumbrigue HB, Abanomi AA, Cheng LL. Techniques to minimize excess luting agent in cement-retained implant restorations. *J Prosthet Dent* 2002;87:112-4.
 17. Schwedhelm ER, Lepe X, Aw TC. A crown venting technique for the cementation of implant-supported crowns. *J Prosthet Dent* 2003;89:89-90.
 18. Wadhvani C, Piñeyro A. Technique for controlling the cement for an implant crown. *J Prosthet Dent* 2009;102:57-8.