

## Massive Hemoptysis Caused by Atypical Behcet's Disease

Won-Young Lee, M.D., Choi Se Hoon, M.D., Hyeong Ryul Kim, M.D.

Pulmonary and/or bronchial aneurysm with systemic thrombophlebitis can be seen in the case of both Behcet's disease and Hughes-Stovin syndrome. These two diseases may be indistinguishable since the clinical, radiological, and histopathological findings are similar in both cases. In particular, from the perspective of pulmonary involvement, hemoptysis is the leading cause of death in both conditions and is followed by aneurysmal rupture. Here, we report a case in which surgical resection was performed for a patient presenting recurrent hemoptysis as an atypical presentation of Behcet's disease.

Key words: 1. Pulmonary artery  
2. Aneurysm  
3. Behcet disease  
4. Hughes-Stovin syndrome

### CASE REPORT

A 19-year-old female presented with recurrent hemoptysis and oral ulceration. Her first experience of hemoptysis had been 2 years earlier; she was admitted to a local hospital at that time. Bronchofiberscopy revealed diffuse alveolar hemorrhage; however, there were no specific findings for the cause of hemoptysis. The patient was diagnosed with Behcet's disease (BD) since she had oral ulcers and erythematous skin lesions. Medical treatment including prednisolone and azathioprine was started.

Two years later, she presented with hemoptysis and went through an additional bronchofiberscopic exam. The exam revealed a hyperemic nodular lesion within the anterior basal segmental bronchus of the right lower lobe (RLL). Biopsy failed because of the little bleeding that occurred when the nodule was touched. The patient was discharged with the same medication after conservative treatment. However, the

patient experienced another episode of hemoptysis and was referred to Seoul Asan Medical Center emergency room.

A rheumatologist and an ophthalmologist were consulted for a differential diagnosis between BD and Hughes-Stovin syndrome (HSS). Further, since these two conditions have a strong predilection for the male gender, a gynecologist examined the patient for thoracic endometriosis.

The patient's physical examination showed oral ulcers but no evidence of genital ulcers, uveitis, and skin lesions. According to her past history, she had had no skin lesions since 2 years earlier, and hemoptysis occurred without any association with her menstrual cycle. Chest computed tomography showed residual ground-glass opacity in RLL due to aspirated blood, but no definite endobronchial lesion or vascular abnormality were observed as the cause of hemoptysis. Chest X-ray showed no specific findings. The patient's blood test was normal except for a mild elevation of the erythrocyte sedimentation rate (29 mm/hr). For the differential diagnosis,

Department of Thoracic and Cardiovascular Surgery, Asan Medical Center, University of Ulsan College of Medicine

Received: August 14, 2013, Revised: October 14, 2013, Accepted: October 15, 2013

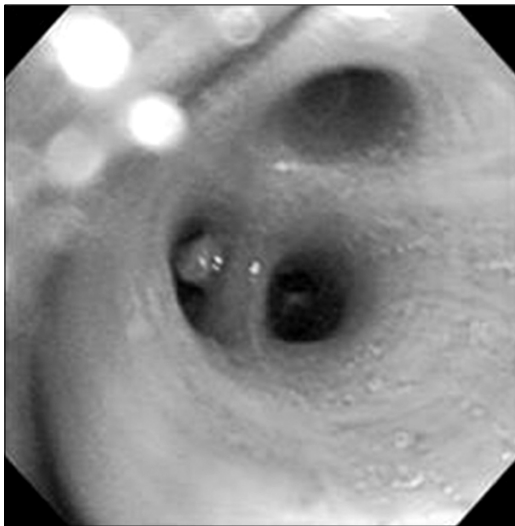
Corresponding author: Hyeong Ryul Kim, Department of Thoracic and Cardiovascular Surgery, Asan Medical Center, University of Ulsan College of Medicine, 88 Olympic-ro 43-gil, Songpa-gu, Seoul 138-736, Korea  
(Tel) 82-2-3010-3580 (Fax) 82-2-3010-6966 (E-mail) scena@dreamwiz.com

© The Korean Society for Thoracic and Cardiovascular Surgery. 2014. All right reserved.

© This is an open access article distributed under the terms of the Creative Commons Attribution Non-Commercial License (<http://creativecommons.org/licenses/by-nc/3.0>) which permits unrestricted non-commercial use, distribution, and reproduction in any medium, provided the original work is properly cited.

anti-nuclear antibody, rheumatoid factor, serum complement levels (C3 and C4), and anti-neutrophil cytoplasmic antibodies (c-ANCA and p-ANCA) were tested; all of them showed negative results.

Elective bronchofiberscopy was scheduled in the operation room. During the exam, a small polyp was observed at the anterior basal segmental bronchus of the RLL and excisional biopsy was proceeded (Fig. 1). After the excisional biopsy using laser, active bleeding occurred; therefore, emergent surgical resection was decided upon.



**Fig. 1.** Bronchofiberscopic image shows a small polyp at the anterior basal segmental bronchus of right lower lobe.

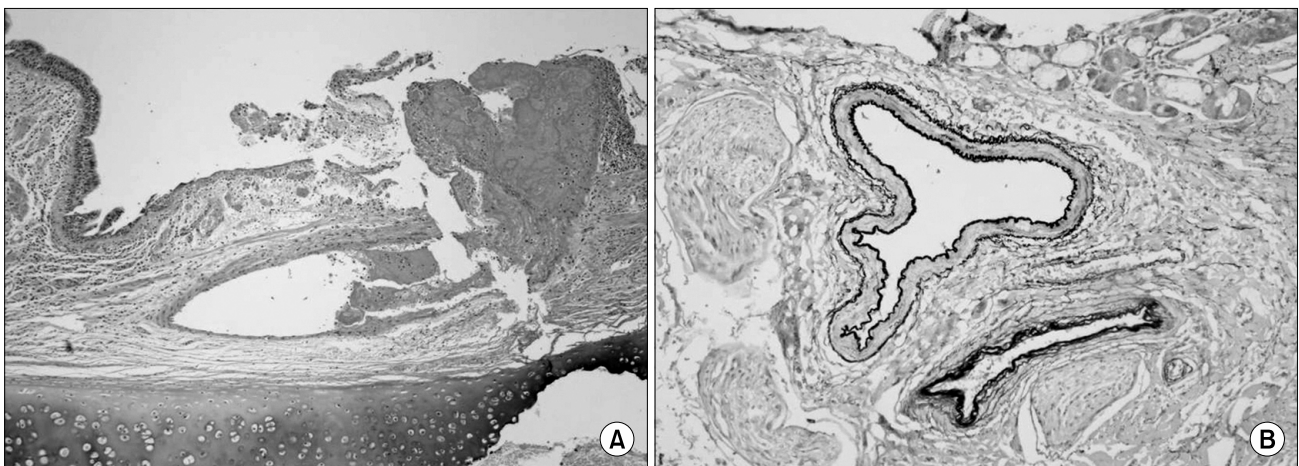
Basal segmentectomy of the RLL was performed using video-assisted thoracoscopic surgery. After transection of the basal segmental bronchus, intraoperative bronchoscopy showed no bleeding focus in the endobronchial area.

The patient's postoperative course was uneventful. Chest tube drainage was removed on postoperative day 3, and the patient was discharged the next day with 5 mg/day of oral prednisolone. Pathological examination revealed abnormally dilated vascular structures in the bronchial submucosa with rupture (Fig. 2). Considering pulmonary aneurysm, an oral ulcer with no evidence of systemic thrombosis, we diagnosed this patient as an atypical presentation of BD.

## DISCUSSION

Pulmonary involvement of BD and HSS is characterized by thrombophlebitis and pulmonary aneurysm. To distinguish HSS from BD, physical examination and close observation are important. Specific features to BD are known to be oral ulcers, recurrent genital ulceration, eye lesions, skin lesions, and a positive pathergy test. However, thus far, the diagnostic criteria for HSS have not been formally established as the etiology of HSS is still unclear and only a few cases of the disease have been reported [1]. Therefore, HSS is diagnosed if a patient presents with a combination of aneurysm and thrombosis without any specific features of BD [1].

However, other clinical features are not specific since



**Fig. 2.** Pathological examination. (A) The specimen shows ruptured vascular structures (H&E,  $\times 40$ ). (B) Abnormally dilated vein and artery in the bronchial submucosa (Elastic stain,  $\times 100$ ).

thrombophlebitis and aneurysm can occur anywhere, including in the hepatic artery, iliac artery, vena cava, cardiac chambers, femoral vein, iliac vein, and dural sinuses [2]. The patients may present cough, dyspnea, pulmonary hypertension, intracranial hypertension, fever, chills, chest pain, and hemoptysis [1,3]. Laboratory findings are also not specific. The blood tests can show leukocytosis, elevated C-reactive protein, erythrocyte sedimentation rate, and anemia when hemoptysis or aneurysmal rupture occurs. Radiologic evaluations, including chest X-ray and chest computed tomography, could be useful only in few patients with large aneurysms. Conventional angiography is regarded as a gold standard of pulmonary artery aneurysms [2]. However, when the patient has thrombosis in the vena cava and has a high risk of aneurysmal rupture, angiography should not be performed. Bronchoscopy might be useful in patients who present hemoptysis with bronchial artery aneurysm, and a Doppler ultrasound of extremities is important for evaluating the presence of deep venous thrombosis.

Some patients, however, do not meet the international classification criteria for BD, as in this case. They may be indistinguishable from patients with HSS since the radiological and histopathological findings are similar. Further, the final clinical stage in both conditions is aneurysmal rupture with massive hemoptysis, which leads to a high mortality rate [4]. Therefore, HSS is suggested as an atypical manifestation of BD.

Considering the histopathological findings, the medical management is similar in both diseases: steroids alone or in combination with immunosuppressants [5]. However, a standard treatment of HSS has not been established because of its unknown etiology. Surgical treatments are performed when massive hemoptysis originates from one segment or one lung. Lobectomy or pneumonectomy could be performed to remove

the aneurysm [1,3]. However, in cases of extensive bilateral multiple aneurysms, operative treatments might be associated with high mortality and morbidity rates [1]. For these patients, transcatheter arterial embolization or immunosuppressive therapy might be an option [3].

To conclude, BD and HSS are rare diseases that might be indistinguishable. Both diseases, however, are associated with high mortality because of the massive hemoptysis in the final stage. Therefore, early diagnosis and immediate surgical resection are crucial for prevention of disastrous complication and mortality. Further, as in this case, the surgical team should be well prepared since an invasive evaluation might cause unexpected complications when the patient is suspicious of pulmonary or bronchial artery aneurysm.

#### CONFLICT OF INTEREST

No potential conflict of interest relevant to this article was reported.

#### REFERENCES

1. Khalid U, Saleem T. *Hughes-Stovin syndrome*. Orphanet J Rare Dis 2011;6:15.
2. Kim JT, Oh TY, Chang WH. *Rare case of multiple pulmonary artery aneurysms with caval thrombosis: Hughes-Stovin syndrome*. Eur J Cardiothorac Surg 2007;31:561-2.
3. Lee J, Noh JW, Hwang JW, et al. *Successful cyclophosphamide therapy with complete resolution of pulmonary artery aneurysm in Hughes-Stovin syndrome patient*. Clin Rheumatol 2008;27:1455-8.
4. Al-Jahdali H. *Massive hemoptysis and deep venous thrombosis presenting in a woman with Hughes-Stovin syndrome: a case report*. J Med Case Rep 2010;4:109.
5. Choh NA, Jehangir M, Mir KM, Kuchay S, Wani NA. *Hughes-Stovin syndrome: a rare cause of hemoptysis*. Lung India 2011;28:285-6.