

## Endovascular Revascularization for the Obstruction after Patch Angioplasty in Buerger's Disease

Hee Jae Jun, M.D.

Surgical revascularization for patients with Buerger's disease is possible only in a few cases, due to the diffuse segmental involvement and the lack of distal runoff vessels available for bypass surgery. We encountered a case of resting pain in the right foot, coldness with dysesthesia, and cyanosis on the right 1st toe. The patient was treated with an endovascular intervention after vein patch angioplasty failed due to an inflammatory reaction of Buerger's disease. We suggest that an endovascular procedure can be an effective treatment, even in addition to more conservative and surgical management, in patients with Buerger's disease and critical limb ischemia.

Key words: 1. Thromboangiitis obliterans  
2. Revascularization  
3. Angioplasty

### CASE REPORT

Total tobacco cessation is the only treatment that improves the symptoms and reduces the risk of amputation in Buerger's disease. Other forms of treatment are not well established or have unfavorable results. Surgical revascularization is often ineffective because the distal target vessels are often involved in this diffuse segmental disease. Calcium channel blockers, anticoagulants, thrombolytics, prostaglandin analogs, sympathectomy, adrenalectomy, spinal cord stimulators, omental transfers, and stem cell treatment have all been tried with limited success in decreasing rest pain and avoiding amputation. We report a case of an interventional endovascular procedure for revascularization.

A 28-year-old male had been suffering from acute right foot pain at rest and coldness with dysesthesia, cyanosis on the right 1st toe, and claudication for 3 weeks. The ankle-brachial

pressure index (ABI) was 0.6 on the right leg. As he was a heavy smoker, the patient's hands and feet were usually cold, and the symptoms became severe when he was exposed to a cold environment. He was free of other diseases, including autoimmune disease, hypercoagulable state, and diabetes mellitus. Hematological laboratory findings and renal function tests were normal. Computerized tomography (CT) angiography showed segmental obstructions of the below-knee popliteal artery, which showed intraluminal thrombosis, and in the posterior tibial artery. The anterior tibial artery was obstructed (Fig. 1). We decided to operate because of the severity of the symptoms and the short segmental obstruction with thrombus. The wall of the popliteal artery had an adhesion and had thickened. The intima of the popliteal artery had also thickened due to inflammatory changes. We performed endarterectomy and vein patch angioplasty of the obstructed popliteal artery with the greater saphenous vein. A Fogarty

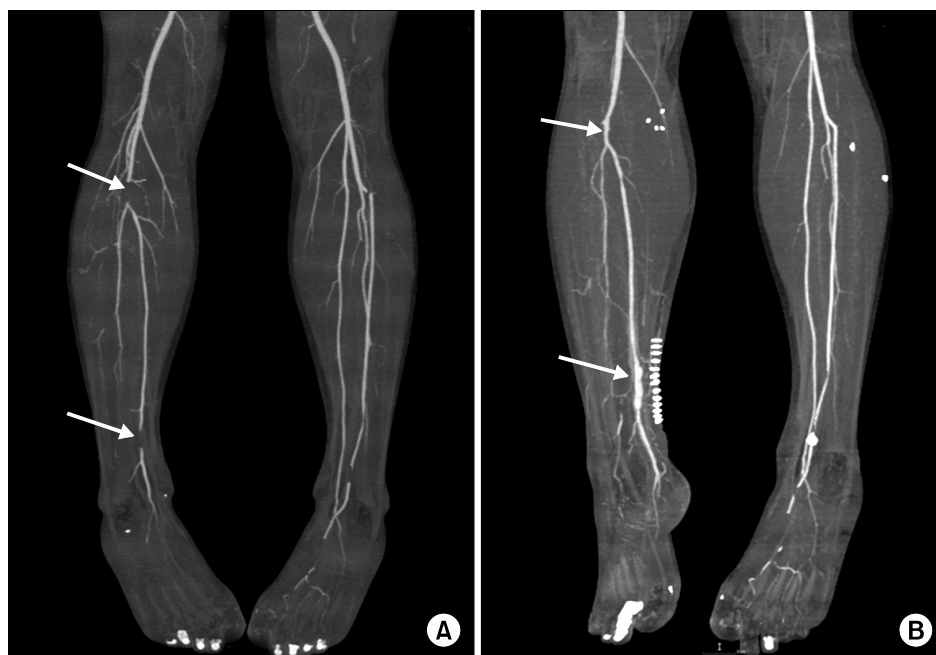Department of Thoracic and Cardiovascular Surgery, Inje University Haeundae Paik Hospital, Inje University College of Medicine

Received: December 5, 2013, Revised: January 5, 2014, Accepted: January 16, 2014

Corresponding author: Hee Jae Jun, Department of Thoracic and Cardiovascular Surgery, Inje University Haeundae Paik Hospital, Inje University College of Medicine, 875 Haeun-daero, Haeundae-gu, Busan 612-862, Korea  
(Tel) 82-51-797-3131 (Fax) 82-51-797-3101 (E-mail) cs523@dreamwiz.com

© The Korean Society for Thoracic and Cardiovascular Surgery. 2014. All right reserved.

© This is an open access article distributed under the terms of the Creative Commons Attribution Non-Commercial License (<http://creativecommons.org/licenses/by-nc/3.0>) which permits unrestricted non-commercial use, distribution, and reproduction in any medium, provided the original work is properly cited.



**Fig. 1.** (A) Computerized tomography (CT) angiography shows segmental obstructions of the below-knee right popliteal artery and posterior tibial artery (arrow). The anterior tibial artery is obstructed in this image. (B) CT angiography shows good patency of the segmental obstructions of the below-knee right popliteal artery and patch angioplasty of the right posterior tibial artery after surgery (arrow).

catheter was not passed under the obstruction of the posterior tibial artery. However, the arteriotomy site was closed with patch angioplasty because of the occurrence of a large amount of back bleeding. After the first operation, the patient's symptoms did not improve and the patient requested reoperation to alleviate the symptoms. The blood vessel had surrounding coalescence with an inflammatory reaction. We performed vein patch angioplasty in the segmental obstruction of the posterior tibial artery 2 weeks after the first operation. Because of the thick intima and fibrosis, endarterectomy was not possible. After the operation, the patient's symptoms improved and he was discharged on postoperative day 15. His ABI was 1.0.

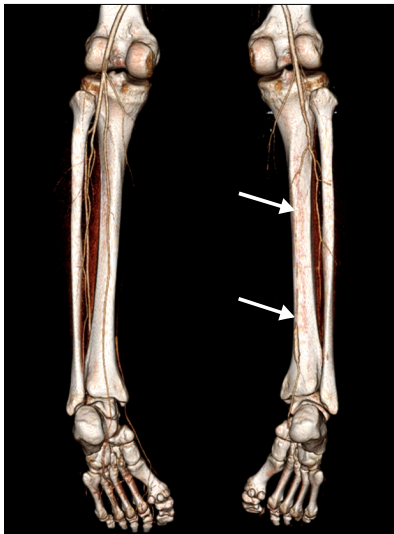
In the histopathological examination, segmentally resected and serially sectioned popliteal arteries showed subacute stages of Buerger's disease. The lumen was near-totally or totally occluded by organized thrombi that presented as recanalized vessels. Remarkable chronic inflammatory cells such as lymphocytes and plasma cells were observed in the recanalized vessel wall with less inflammation in the walls of the blood vessels.

The symptoms recurred, and the patient was re-hospitalized after 3 months. CT angiography showed diffuse posterior tibial artery obstructions in the patch angioplasty of the posterior tibial artery in the upper direction (Fig. 2). A pre-proce-

dural angiogram showed severe stenosis in the upper part of the vein patch angioplasty of the posterior tibial artery. The possibility of stenosis and obstruction always exists in the blood vessels of patients with Buerger's disease due to inflammatory reactions. Angioplasty of the posterior tibial artery was performed using a balloon catheter (4-40 mm, Ever-Cross; ev3 Endovascular Inc., Plymouth, MN, USA). Angiography after this procedure demonstrated a good final angiographic result and the absence of critical stenosis. Improved blood circulation was observed in the CT angiography performed after 1 year (Fig. 3). The patient recovered completely with no further complications or symptoms. This patient quit smoking from before the first operation until the time of this report. For 2 months after the endovascular procedure, warfarin was used. From after the first operation until the present, aspirin and clopidogrel (Plavix) have been used.

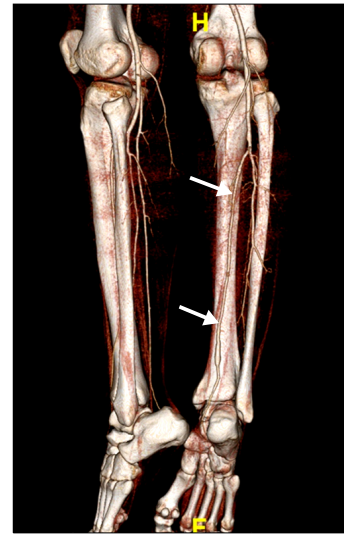
## DISCUSSION

Buerger's disease is defined as a nonatherosclerotic segmental disease that is characterized by occlusive, inflammatory, and thrombotic changes. Several different criteria, such as those suggested by Shionoya [1] and Olin [2], have been proposed for the diagnosis of Buerger's disease. Our



**Fig. 2.** Computerized tomography angiography shows diffuse obstruction in an anastomosis site of patch angioplasty of the right posterior tibial artery (arrow).

case met all of the diagnostic criteria. Typical angiographic findings were distal vessel disease with no presence of arterial wall calcification and the development of a rich typical subcutaneous network of collaterals, usually referred to as corkscrew collaterals [3]. Tobacco use, in any of its forms, plays a central role in the pathogenesis and progression of the condition [4]. Clinical presentation usually begins with ischemia of the distal small arteries and veins of the legs, arms, feet, and hands, which is manifested by claudication of the corresponding extremities [2]. Progression of the disease is typically characterized by calf claudication and, eventually, ischemic pain at rest. Ischemic ulcerations on the toes, feet, or fingers may develop. Superinfection often occurs, and the lesions progress toward necrosis and distal gangrene. The prognosis for patients with Buerger's disease with respect to limb loss is significantly worse than that for patients with either atherosclerosis or the various forms of necrotizing immune arteritis [2,4]. At present, the only proven strategy to prevent the progression of the disease and avoid amputation, in some cases, is the complete discontinuation of cigarette smoking or any other use of tobacco in any form [5]. Nevertheless, many patients continue to have a very poor quality of life owing to the persistence of symptoms such as intermittent claudication, Raynaud's phenomenon, or even



**Fig. 3.** Post-interventional computerized tomography angiography shows improved blood circulation in the right posterior tibial artery (arrow).

amputations [4,5]. The risk of amputation is highly correlated with continuing to smoke; the amputation rate varies from 42% to 5% at the Cleveland Clinic Foundation according to tobacco use [3]. At the end of a 5-year follow-up, the median prevalence of amputation in patients with Buerger's disease, based on the most recently reported series, is reported to be as high as 24.4% for minor amputations and 8.6% for major amputations, for a total amputation rate of 33% for patients treated conservatively [3].

Surgical revascularization for patients with Buerger's disease is possible only in a few cases, as a result of diffuse distal involvement with no distal runoff vessels available for bypass surgery [6,7]. Consequently, surgical procedures are technically challenging, with very low feasibility and patency rates.

Endovascular treatment for Buerger's disease is not generally reported in the medical literature as either feasible or effective. Graziani et al. [8] reported that an endovascular procedure is safe, technically feasible, and effective, independent of the continued or non-use of tobacco, which leads us to argue that the procedure alone achieved these high rates of clinical success, the decreased rates of amputation, and the maintenance of clinical improvement during midterm follow-up periods. Although the physiopathology of

the disease is characterized by the presence of inflammation arteritis and associated thrombosis, this did not preclude or affect the results of the primary angioplasty of the treated lesions.

In our case, the patient was suspected of having a subacute form of Buerger's disease on the basis of the microscopic findings. It seems that inflammatory changes in blood vessel obstruction were in progress after the patient underwent patch angioplasty of the segmental obstruction. We resolved this by endovascular intervention, and we have been observing the patient's progress for about a year, but no strictures or other abnormalities have been found.

Finally, although tobacco cessation is one of the most important steps for a significant reduction in disease progression, we believe that an endovascular procedure can be an effective treatment, even in addition to more conservative and surgical management, in patients with Buerger's disease and critical limb ischemia.

#### CONFLICT OF INTEREST

No potential conflict of interest relevant to this article was

reported.

#### REFERENCES

1. Shionoya S. *Diagnostic criteria of Buerger's disease*. Int J Cardiol 1998;66 Suppl 1:S243-5.
2. Olin JW. *Thromboangiitis obliterans (Buerger's disease)*. N Engl J Med 2000;343:864-9.
3. Puechal X, Fiessinger JN. *Thromboangiitis obliterans or Buerger's disease: challenges for the rheumatologist*. Rheumatology (Oxford) 2007;46:192-9.
4. Arkkila PE. *Thromboangiitis obliterans (Buerger's disease)*. Orphanet J Rare Dis 2006;1:14.
5. Corelli F. *Buerger's disease: cigarette smoker disease may always be cured by medical therapy alone: uselessness of operative treatment*. J Cardiovasc Surg (Torino) 1973;14: 28-36.
6. Dilege S, Aksoy M, Kayabali M, Genc FA, Senturk M, Baktiroglu S. *Vascular reconstruction in Buerger's disease: is it feasible?* Surg Today 2002;32:1042-7.
7. Bozkurt AK, Besirli K, Koksall C, et al. *Surgical treatment of Buerger's disease*. Vascular 2004;12:192-7.
8. Graziani L, Morelli L, Parini F, et al. *Clinical outcome after extended endovascular recanalization in Buerger's disease in 20 consecutive cases*. Ann Vasc Surg 2012;26:387-95.