Korean J Thorac Cardiovasc Surg 2014;47:163-166 □ Case Report □
ISSN: 2233-601X (Print) ISSN: 2093-6516 (Online) http://dx.doi.org/10.5090/kjtcs.2014.47.2.163

Hybrid Technique to Correct Cerebral Malperfusion Following Repair of a Type A Aortic Dissection

Seon Hee Kim, M.D.[1], Seunghwan Song, M.D.[1], Sang-pil Kim, M.D.[1], Jonggeun Lee, M.D.[1], Han Cheol Lee, M.D.[2], Eun Soo Kim, M.D.[3]

A 49-year-old man with drowsy mentality was diagnosed with acute type A aortic dissection; he underwent an emergency operation. When selective antegrade cerebral perfusion was initiated, the right regional cerebral oxygen saturation (rSO_2) decreased as compared to the left one. Adequate blood flow was perfused through the branch of the artificial graft, after distal anastomosis, but the right rSO_2 did not recover. Angiography revealed another intimal tear on the right common carotid artery. A stent was then inserted. The right rSO_2 promptly increased to the same level as that of the left one. The patient was discharged without any neurologic complications.

Key words: 1. Aortic dissection
2. Cerebral angiography
3. Stents

CASE REPORT

A 49-year-old man was admitted to Pusan National University Hospital with complaints of squeezing chest pain and drowsy mentality. His systolic blood pressure was 70 mmHg, and his heart rate was 120 bpm. Computed tomography revealed acute type A aortic dissection (ATAAD) that involved the aortic arch and the descending thoracic aorta (Fig. 1). An emergency operation was performed. Regional cerebral oxygen saturation (rSO_2) was monitored upon arrival at the operation room, and it was maintained during surgery using an Invos system (Somanetics, Troy, MI, USA) (Fig. 2). The arterial perfusion line was placed on the right subclavian artery that appeared to be visually normal. After initiating cardiopulmonary bypass (CPB), adequate blood flow was obtained, and the patient's vital signs stabilized. After aortic cross clamping, the ascending aorta and the aortic valve were observed through aortotomy. An intimal tear was located in the ascending aorta, and the coaptation of the aortic valve was good. When the blood temperature fell to 27°C, the aortic cross clamp was released. Ascending and hemiarch replacement was planned because the visible arch and the descending aorta were intact. Selective antegrade cerebral perfusion (SACP) was initiated through all three arch vessels. The proximal innominate artery was clamped, and perfusion catheters were inserted into the left carotid and left subclavian arteries. The cerebral blood flow rate was maintained at approximately 600 mL/min. Then, the right rSO_2 decreased abruptly, and it did not recover as compared to the left one. Despite declamping and rechecking the inside of the in-

[1]Department of Thoracic and Cardiovascular Surgery, [2]Division of Cardiology, Departments of Internal Medicine, and [3]Department of Anesthesiology and Pain Medicine, Medical Research Institute, Pusan National University Hospital, Pusan National University School of Medicine
Received: August 5, 2013, Revised: October 10, 2013, Accepted: October 11, 2013
Corresponding author: Seunghwan Song, Department of Thoracic and Cardiovascular Surgery, Medical Research Institute, Pusan National University Hospital, Pusan National University School of Medicine, 179 Gudeok-ro, Seo-gu, Busan 602-739, Korea
(Tel) 82-51-240-7267 (Fax) 82-51-243-9389 (E-mail) song77.sh@gmail.com
ⓒ The Korean Society for Thoracic and Cardiovascular Surgery. 2014. All right reserved.
ⓒⓒ This is an open access article distributed under the terms of the Creative Commons Attribution Non-Commercial License (http://creativecommons.org/licenses/by-nc/3.0) which permits unrestricted non-commercial use, distribution, and reproduction in any medium, provided the original work is properly cited.

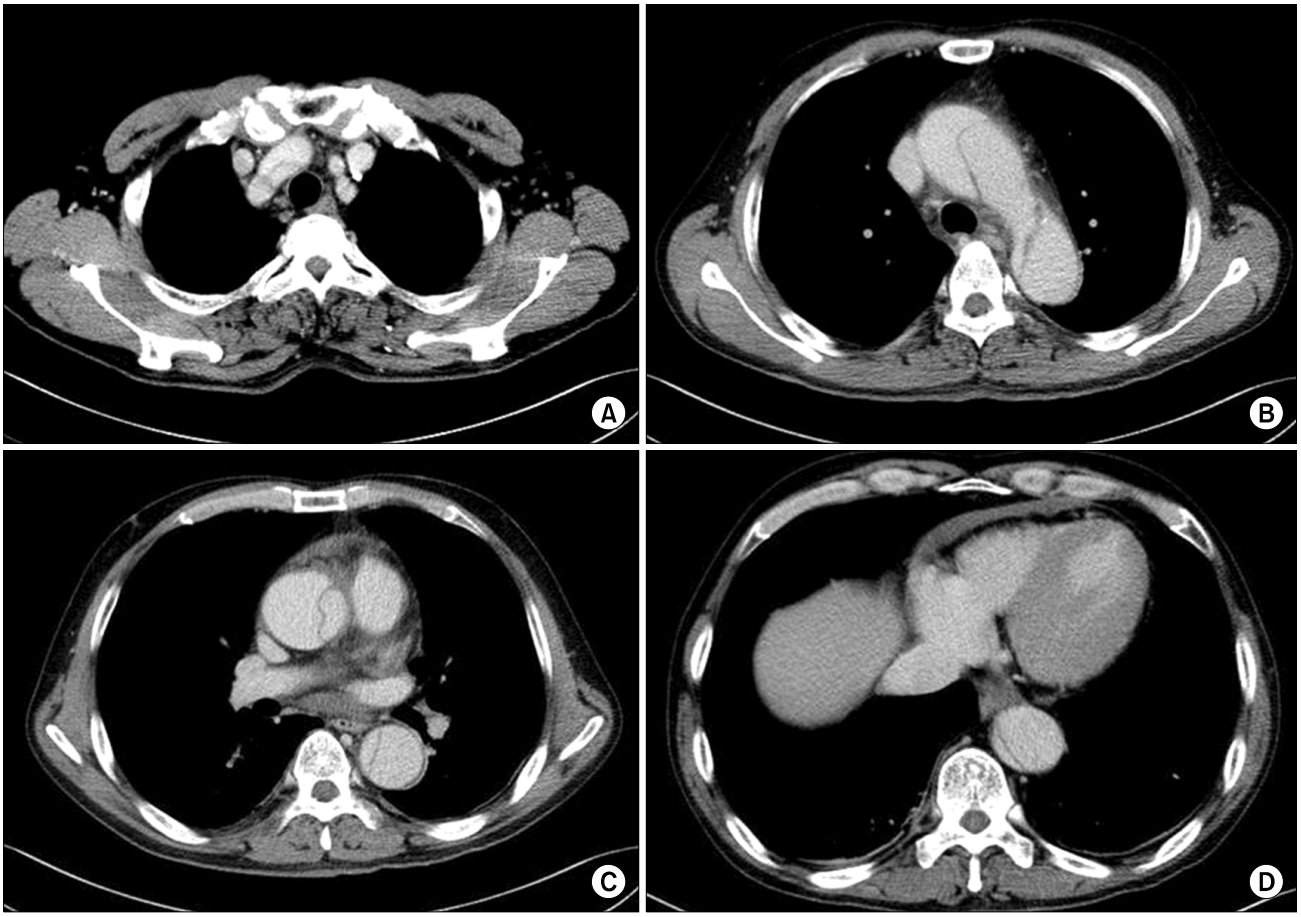

Fig. 1. Preoperative computed tomography revealed aortic dissection involving (A) the innominate artery, (B) aortic arch, and (C) ascending and descending thoracic aorta. (D) Pericardial hemorrhage was shown at the level of diaphragm.

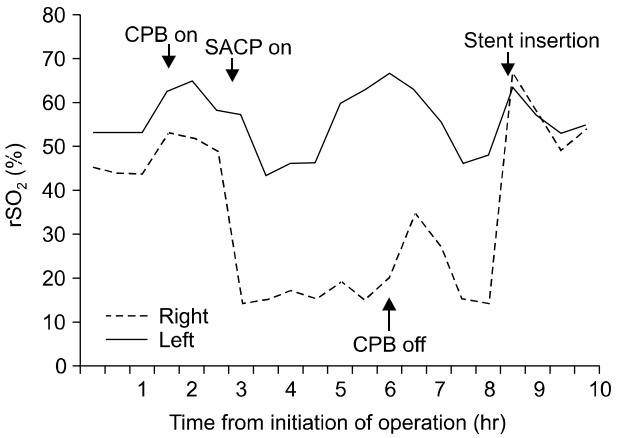

Fig. 2. The serial changes of right and left regional cerebral oxygen saturation are presented. rSO_2, regional cerebral oxygen saturation; CPB, cardiopulmonary bypass; SACP, selective antegrade cerebral perfusion.

nominate artery, we found no luminal problem. As dynamic carotid artery obstruction was suspected, the operation was continued because such obstructions usually resolve after operation. Although the distal aortic anastomosis was completed and an adequate amount of blood flow to the branch of artificial graft was restarted, the right rSO_2 did not increase. Diagnostic angiography was planned for blood flow assessment. We transferred the patient to the catheterization laboratory for angiography immediately after the operation. Another intimal tear on the proximal right common carotid artery, which was obstructing the blood flow, was identified using angiography. A 12×80 mm SMART Control Nitinol Stent System (Cordis Co., Bridgewater, NJ, USA) was inserted into the right common carotid artery (Fig. 3). The right rSO_2 promptly recovered to the same level as the left one. The total bypass time, aortic cross clamp time, and selective

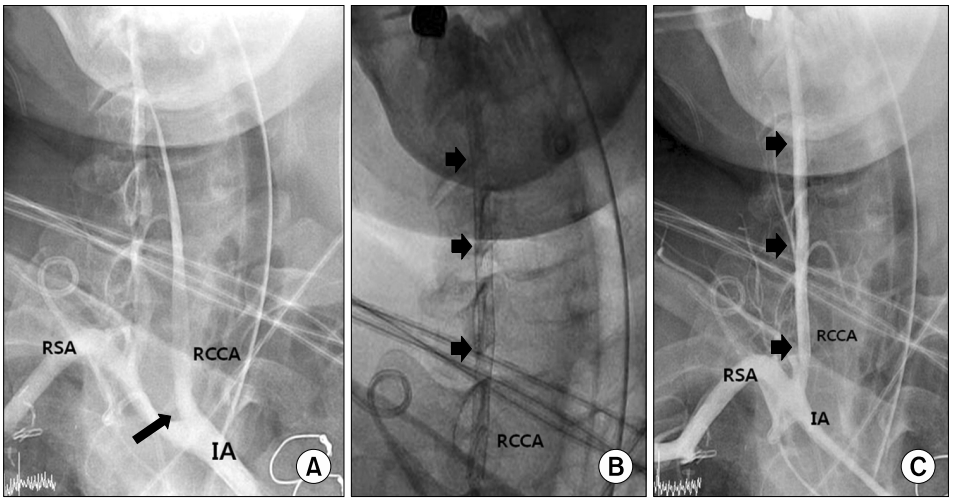

Fig. 3. (A) A patent IA and RSA but obstructed RCCA were revealed by angiography. An intimal tear occurred at the IA bifurcation site (arrow). (B) An angiograph revealed a well-deployed stent graft (arrow) in the RCCA. (C) Flow recovered in the RCCA (arrows) after stent insertion. IA, innominate artery; RSA, right subclavian artery; RCCA, right common carotid artery.

antegrade cerebral perfusion time were 227, 191, and 85 minutes, respectively. The patient was extubated on postoperative day 2 and discharged on postoperative day 13 without neurologic deficit.

DISCUSSION

Despite advances in surgical techniques, the mortality rates of ATAAD have remained high in patients with brain malperfusion. Occlusion of the aortic arch vessels, which is propagated from the dissected aorta, commonly leads to neurological deficit [1]. The main factor causing malperfusion is the dynamic obstruction of the false lumen or hypotension itself. In most cases, this can be relieved by restoring sufficient true luminal blood flow via surgery.

In the present case, we described a patient who had ATAAD and a right carotid artery tear. The patient was treated via stent placement at the time of the surgery, using a hybrid technique. There are three important points to understand from this case.

First, whenever the patient's condition is acceptable, evaluations of the aortic arch vessels are essential for selecting the arterial approach for cardiopulmonary bypass in ATAAD involving the aortic arch. A previous study elucidated when the malperfusion occurs: 1) pre-surgery malperfusion, 2) malperfusion at the institution of cardiopulmonary bypass, 3) malperfusion occurring after aortic cross clamping, and 4) malperfusion postdistal aortic anastomotic construction [2]. Clamping the innominate artery for SACP may have caused injuries such as intimal tear and dissection, resulting in a reduction of carotid blood flow. This speculation is consistent with the fact that rSO_2 dramatically decreased when SACP was initiated. Malperfusion, at the beginning of CPB, can be generated not only by retrograde perfusion via the femoral artery but also by antegrade perfusion via the subclavian artery. Therefore, precise radiographic evaluation should be performed to ensure adequate cerebral blood flow. If rSO_2 drops at the time of CPB initiation, surgeons should promptly change the arterial cannulation site.

Second, rSO_2 monitoring is a very reliable method to detect brain malperfusion. In addition, it is important to initiate monitoring before anesthetic induction to detect problems by observing serial saturation changes. Near-infrared spectroscopy (NIRS) provides continuous rSO_2 monitoring and is a simple noninvasive method for monitoring cerebral perfusion. NIRS-guided SACP allows a safe approach to aortic arch surgery, and a unilateral progressive discrepancy in rSO_2 indicates the occurrence of brain malperfusion. It is recommended that additional perfusion should be addressed immediately, when major hemispheric discrepancies appear [2,3]. In our case, rSO_2 did not recover at the end of the surgery. Thus, we immediately performed confirmatory angiography.

Third, if rSO_2 drops without any apparent anatomic or procedural reason, diagnostic angiography, as a hybrid technique, is strongly recommended. As for the discrepancy in rSO_2 in our case, even though aortic replacement was completed, we

ascertained the luminal integrity of the innominate artery and suspected insufficient brain perfusion due to dissection or re-dissection of the carotid artery. Angiography is needed to confirm the status of the carotid artery lumen. In our case, we found a tear on the right common carotid artery and achieved rSO_2 recovery through prompt carotid stent placement. After an open arterial stenosis, sufficient brain perfusion was restored, and no postoperative neurological symptoms developed. There are several published experiences with acute carotid revascularization in ATAAD cases involving the aortic arch vessels. In these cases, carotid stent placement was performed to recanalize the artery or seal an intimal flap, and a high success rate was achieved [4,5].

In summary, in ATAAD patients with decreased mentality, preoperative evaluation of the aortic arch vessels, continuous monitoring of rSO_2, and the use of a hybrid technique that involves confirmatory angiography for detected problems will reduce neurologic complications from brain malperfusion. In addition, if a hybrid operation room is available, surgeons can save additional time in finding and fixing vascular complications

CONFLICT OF INTEREST

No potential conflict of interest relevant to this article was reported.

ACKNOWLEDGMENTS

This work was supported by clinical research grant from Pusan National University Hospital 2013.

REFERENCES

1. Tanaka H, Okada K, Yamashita T, Morimoto Y, Kawanishi Y, Okita Y. *Surgical results of acute aortic dissection complicated with cerebral malperfusion*. Ann Thorac Surg 2005; 80:72-6.
2. Harrington DK, Ranasinghe AM, Shah A, Oelofse T, Bonser RS. *Recommendations for haemodynamic and neurological monitoring in repair of acute type a aortic dissection*. Anesthesiol Res Pract 2011;2011:949034.
3. Harrer M, Waldenberger FR, Weiss G, et al. *Aortic arch surgery using bilateral antegrade selective cerebral perfusion in combination with near-infrared spectroscopy*. Eur J Cardiothorac Surg 2010;38:561-7.
4. Lentini S, Tancredi F, Benedetto F, Gaeta R. *Type A aortic dissection involving the carotid arteries: carotid stenting during open aortic arch surgery*. Interact Cardiovasc Thorac Surg 2009;8:157-9.
5. Roseborough GS, Murphy KP, Barker PB, Sussman M. *Correction of symptomatic cerebral malperfusion due to acute type I aortic dissection by transcarotid stenting of the innominate and carotid arteries*. J Vasc Surg 2006;44:1091-6.