

Arch Reconstruction with Autologous Pulmonary Artery Patch in Interrupted Aortic Arch

Won-Young Lee, M.D., Jeong-Jun Park, M.D.

Various surgical techniques have been developed for the repair of an interrupted aortic arch. However, tension and Gothic arch formation at the anastomotic site have remained major problems for these techniques: Excessive tension causes arch stenosis and left main bronchus compression, and Gothic arch configuration is related to cardiovascular complications. To resolve these problems, we adopted a modified surgical technique of distal aortic arch augmentation using an autologous main pulmonary artery patch. The descending aorta was then anastomosed to the augmented aortic arch in an end-to-side manner. Here, we report two cases of interrupted aortic arch that were repaired using this technique.

Key words: 1. Interrupted aortic arch
2. Main pulmonary artery patch
3. Gothic arch

CASE REPORT

Two patients were referred for an operation. They were diagnosed with an interrupted aortic arch (IAA) with ventricular septal defect (VSD) by echocardiography. Computed tomography (CT) was reviewed for further evaluation and operational planning. Prostaglandin therapy was applied, but mechanical ventilation was not required.

The two patients underwent one-stage repair on days 10 and 18. One weighed 2.82 kg and was diagnosed with type A IAA with VSD. The distance between the ascending and the descending aortic segments was 17 mm. The other one weighed 2.88 kg and was diagnosed with type B IAA with VSD. The distance between the ascending and the descending aortic segments was 21 mm. Subaortic narrowing was seen in both patients owing to mild posterior malalignment of the

conal septum.

Both underwent nonemergency repair using cardiopulmonary bypass (CPB) under moderate hypothermia (26°C) with selective cerebral perfusion of the innominate artery using a 3.5-mm Gore-tex vascular graft shunt. This shunt, with SVC and IVC cannulation, was used as a single aortic cannula for CPB. The flow rate was 100 to 150 mL/kg/min to maintain the right radial artery pressure of 45 to 70 mmHg and diminished to 55% to 60% during selective cerebral perfusion, which was monitored using near-infrared spectroscopy. The hematocrit level was maintained above 24%, and the alpha-stat method was used for blood gas management.

A patch was harvested from the anterior wall of the main pulmonary artery (MPA) after the complete resection of the ductus arteriosus. The descending aorta was mobilized for the second and the third pairs of intercostal arteries, and both

Department of Thoracic and Cardiovascular Surgery, Asan Medical Center, University of Ulsan College of Medicine

Received: August 5, 2013, Revised: October 14, 2013, Accepted: October 15, 2013

Corresponding author: Jeong-Jun Park, Department of Thoracic and Cardiovascular Surgery, Asan Medical Center, University of Ulsan College of Medicine, 88 Olympic-ro 43-gil, Songpa-gu, Seoul 138-736, Korea
(Tel) 82-2-3010-3587 (Fax) 82-2-3010-6811 (E-mail) pkjj@amc.seoul.kr

© The Korean Society for Thoracic and Cardiovascular Surgery. 2014. All right reserved.

© This is an open access article distributed under the terms of the Creative Commons Attribution Non-Commercial License (<http://creativecommons.org/licenses/by-nc/3.0>) which permits unrestricted non-commercial use, distribution, and reproduction in any medium, provided the original work is properly cited.

pulmonary arteries were dissected to each hilar area. An incision was made at the lesser curvature of the aortic arch to the lateral aspect of the arch vessel and augmented with the harvested MPA patch by a continuous 7-0 polypropylene suture. The descending aorta was then anastomosed to the augmented aortic arch in an end-to-side manner after making an incision at the pulmonary artery patch (Fig. 1).

For completing the aortic arch reconstruction, a Dacron patch was used for VSD closure through an incision of the right ventricle. To prevent the left ventricle outflow tract obstruction (LVOTO), we positioned the stitches with respect to

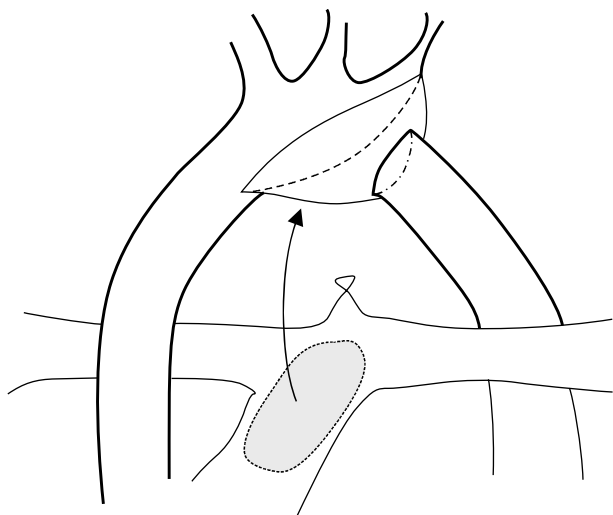


Fig. 1. Schematic representation of aortic arch repair using pulmonary autograft patch augmentation.

the apical portion of the VSD patch on the left side of the conal septum [1].

The MPA was reconstructed with glutaraldehyde-fixed autologous pericardium with smooth CPB weaning. Each cardiopulmonary bypass time was 196 and 159 minutes, the cross-clamp time was 103 and 100 minutes, and the selective cerebral perfusion time was 29 and 38 minutes, respectively. The lactate level was less than 4.5 mmol/L during CPB support with no end organ damage, including acute renal failure. Peritoneal dialysis was not required since the urination was more than 1 mL/kg/hr after adequate lower body perfusion.

Delayed sternal closure was performed on postoperative days 1 and 3. Extubation was possible 3 to 4 days after sternal closure, and the patient was discharged after general care. Follow-up CT and echocardiography results were reviewed before discharge (Figs. 2, 3). Both patients did not show left main bronchus obstruction and LVOTO.

DISCUSSION

Surgical outcomes in the repair of IAA have been improved by perioperative management and accumulated surgical experience [2]. However, interventions and additional surgical procedures are still required frequently to resolve the complications, including bronchial compression, anastomosis site stenosis, subaortic stenosis, and Gothic arch configuration [3,4].

Mobilization of the descending aorta allows direct anasto-

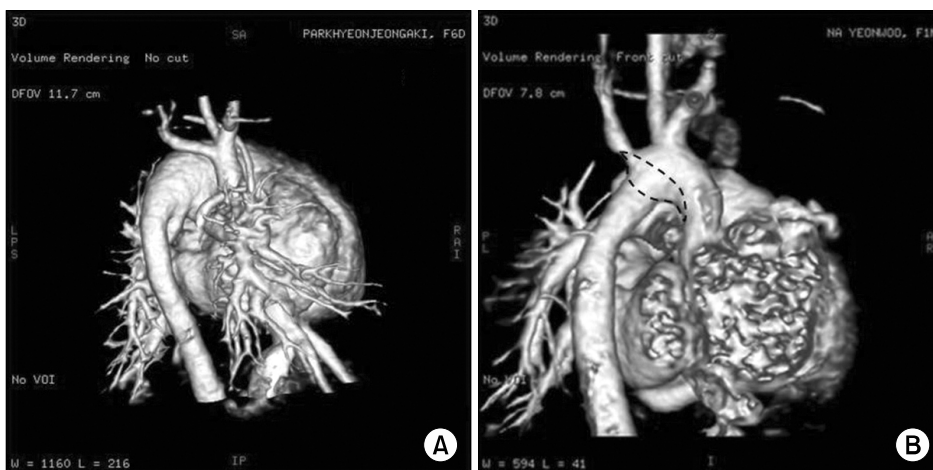

Fig. 2. (A) Preoperative computed tomography (CT) image shows a longer distance between the ascending and the descending aorta than that in the case of the usual type A interrupted aortic arch. (B) Postoperative CT image of type A interrupted aortic arch. The dotted line shows that the main pulmonary artery patch augmentation and the smooth arch configuration were achieved.

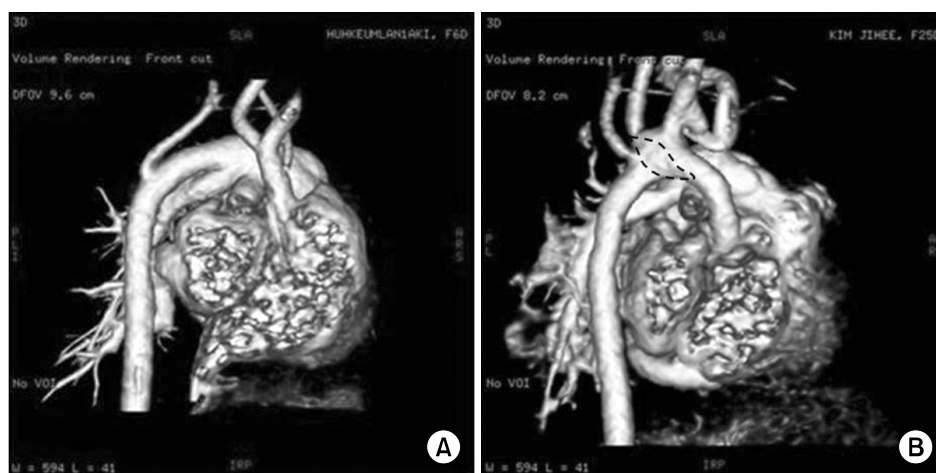


Fig. 3. (A) Preoperative computed tomography (CT) image. (B) Postoperative CT image of type B interrupted aortic arch. The dotted line shows that the main pulmonary artery patch augmentation and the smooth arch configuration were achieved.

mosis to the ascending aorta in most cases; however, tension at the anastomosis site can cause complications, particularly when anastomosis between the ascending and the descending aorta requires a long distance [5]. Bronchial compression, an unusual complication caused by the excessive tension between the two aortic components, is a risk factor for atelectasis, pneumonia, and prolonged mechanical ventilation. To resolve the compressed bronchus, aortopexy is considered after the primary operation [3,5].

Restenosis of the anastomosis site is also caused by the tension between the two aortic components after the surgical repair of IAA. Balloon angioplasty is a method of choice; however, surgical correction may be required since long-term data are still minimal and not free from complications [5].

Recent studies show that ‘Gothic’-shaped aortic arch geometry is an independent contributor to both resting and exercise-induced hypertension [6]. Further, long-term follow up studies have shown that the high pressure and turbulence of the angular portion cause inelasticity and increase the intima-media thickness of the aortic wall that leads to aortic aneurysm and aortic dissection [4].

Since these complications are mostly associated with surgical and anatomic factors, various surgical techniques have been developed to repair IAA without anastomosis site tension and Gothic arch configuration [4,5,7]. A prosthetic tube was introduced with the aim of tension-free anastomosis; however, it was abandoned as an alternative since reoperation was inevitable owing to restenosis. A Neville tube, an autologous tube created by rolling up the pulmonary artery patch,

was introduced by Bergoend et al. [4] based on the idea of growth potential, which has disadvantages since two suture lines are necessary and increase the risk of anastomotic stenosis. The use of a carotid or subclavian vessel as an autologous conduit has also been presented as an ideal solution; however, it is controversial because of the possibility of neurologic sequelae or growth disturbances [3].

Aortic arch reconstruction with MPA patch augmentation was introduced by Roussin et al. [5], which has benefits in the case of tension-free anastomosis and growth potential. The anastomosis is performed in an end-to-end manner, and full length between the aortic segments is required as the descending thoracic aorta partially attaches directly to the ascending aorta.

Our modified technique requires less length than the previous technique because the MPA patch is placed between the aortic components. Therefore, this technique is useful when aortic segments are at full length for anastomosis and when complications are predicted by the tension at the anastomosis site and the configuration of the Gothic arch.

In conclusion, this modified technique is expected to reduce the risks of complications in the surgical repair of IAA by preventing the tension between the anastomosis sites with a better arch configuration. However, long-term follow-up with echocardiogram and chest CT is required for arch configurations, aneurysmal change, restenosis, airway compression, and LVOTO. A large number of studies should also be reviewed to support the results.

CONFLICT OF INTEREST

No potential conflict of interest relevant to this article was reported.

REFERENCES

1. Luciani GB, Ackerman RJ, Chang AC, Wells WJ, Starnes VA. *One-stage repair of interrupted aortic arch, ventricular septal defect, and subaortic obstruction in the neonate: a novel approach.* J Thorac Cardiovasc Surg 1996;111:348-58.
2. Mishra PK. *Management strategies for interrupted aortic arch with associated anomalies.* Eur J Cardiothorac Surg 2009;35:569-76.
3. Brown JW, Ruzmetov M, Okada Y, Vijay P, Rodefeld MD, Turrentine MW. *Outcomes in patients with interrupted aortic arch and associated anomalies: a 20-year experience.* Eur J Cardiothorac Surg 2006;29:666-73.
4. Bergoend E, Bouissou A, Paoli F, Rouillet-Renoleau N, Duchalais A, Neville P. *A new technique for interrupted aortic arch repair: the Neville tube.* Ann Thorac Surg 2010;90:1375-6.
5. Roussin R, Belli E, Lacour-Gayet F, et al. *Aortic arch reconstruction with pulmonary autograft patch aortoplasty.* J Thorac Cardiovasc Surg 2002;123:443-8.
6. Ou P, Mousseaux E, Celermajer DS, et al. *Aortic arch shape deformation after coarctation surgery: effect on blood pressure response.* J Thorac Cardiovasc Surg 2006;132:1105-11.
7. Tlaskal T, Hucin B, Hruda J, et al. *Results of primary and two-stage repair of interrupted aortic arch.* Eur J Cardiothorac Surg 1998;14:235-42.