

## Surgery for Partial Anomalous Pulmonary Venous Connections: Modification of the Warden Procedure with a Right Atrial Appendage Flap

Chilsung Kim, M.D., Yang Hyun Cho, M.D., Mina Lee, M.D., Ji-Hyuk Yang, M.D., Tae-Gook Jun, M.D., Jin Young Song, M.D., June Huh, M.D., I-seok Kang, M.D.

**Background:** Surgical repair of a partial anomalous pulmonary venous connection (PAPVC) to the superior vena cava (SVC) may be complicated by sinus node dysfunction or SVC obstruction. We modified the Warden procedure by using a right atrial auricular flap to decrease the occurrence of these complications. **Methods:** Between February 2005 and July 2012, 10 consecutive patients underwent a modified Warden procedure to correct PAPVC. The median patient age was 5.7 years. Eight patients (80%) had an atrial septal defect. To surgically correct the PAPVC, we made a U-shaped incision on the right atrial appendage and sutured the flap to the posterior wall of the SVC. The anterior wall was reconstructed with various patch materials. **Results:** No early or late deaths occurred, nor did any patient require early or late reoperation for SVC or pulmonary venous obstruction. No new arrhythmias appeared during follow-up, which was complete in all patients (mean, 29.5 months). **Conclusion:** Our modification of the Warden procedure seems to be effective and safe. This technique may lower the risk of SVC obstruction, pulmonary venous obstruction, and sinus dysfunction.

Key words: 1. Congenital heart disease (CHD)  
2. Partial anomalous pulmonary venous connection (PAPVC)  
3. Modified Warden procedure

### INTRODUCTION

Partial anomalous pulmonary venous connection (PAPVC) is an anomaly in which some but not all pulmonary veins connect to the right atrium or its tributaries as opposed to the left atrium [1]. The most common type of PAPVC is related to a sinus venosus malformation; the right upper and middle pulmonary veins connect to the superior vena cava (SVC) or cavoatrial junction, and a sinus venosus-type atrial septal defect (ASD) is present in 90% of the patients [2]. The ideal surgical correction of SVC-connected PAPVC creates a nor-

mal physiological flow with separate pulmonary and systemic venous pathways, while avoiding complications such as sinus node dysfunction [3]. Various surgical techniques have been described for the correction of PAPVC that connects to the SVC. Conventional repair, which creates a pulmonary venous pathway with one or two patches, carries the risk of pulmonary venous obstruction, SVC stenosis, and sinus node dysfunction [3,5,6]. In the Warden procedure, reported in 1984, the SVC is divided, and the cephalic SVC is anastomosed to the right atrial (RA) appendage, while the caudal SVC serves as a pulmonary drainage conduit [3]. This procedure has been

Departments of <sup>1</sup>Thoracic and Cardiovascular Surgery and <sup>2</sup>Pediatrics, Samsung Medical Center, Sungkyunkwan University School of Medicine  
Received: September 5, 2013, Revised: October 13, 2013, Accepted: October 15, 2013

Corresponding author: Tae-Gook Jun, Department of Thoracic and Cardiovascular Surgery, Samsung Medical Center, Sungkyunkwan University School of Medicine, 81 Irwon-ro, Gangnam-gu, Seoul 135-710, Korea  
(Tel) 82-2-3410-3484 (Fax) 82-2-3410-0089 (E-mail) [tg.jun@samsung.com](mailto:tg.jun@samsung.com)

© The Korean Society for Thoracic and Cardiovascular Surgery. 2014. All rights reserved.

© This is an open access article distributed under the terms of the Creative Commons Attribution Non-Commercial License (<http://creativecommons.org/licenses/by-nc/3.0>) which permits unrestricted non-commercial use, distribution, and reproduction in any medium, provided the original work is properly cited.

**Table 1.** Preoperative characteristics

Characteristic	Value
APV	
RUPV only	8 (80)
More than RUPV	2 (20)
Drainage of APV	
SVC	8 (80)
SVC-right atrium junction	2 (20)
Atrial septal defect	
Sinus venosus	7 (70)
Secundum	0
Patent foramen ovale	1 (10)
Intact atrial septum	2 (20)
Associated anomaly	
Persistent left SVC	4 (40)
Double outlet right ventricle (TOF type)	1 (10)
D-Transposition of great artery with ventricular septal defect	1 (10)

Values are presented as number (%).

APV, anomalous pulmonary vein; RUPV, right upper pulmonary vein; SVC, superior vena cava.

widely used for surgically correcting PAPVC, which connects to the SVC. Although the Warden procedure has been effective in decreasing the risk of SVC or pulmonary venous obstruction, there have been a few complications after the Warden procedure, including pulmonary venous obstruction, SVC obstruction, and sinus node dysfunction [8,10,13].

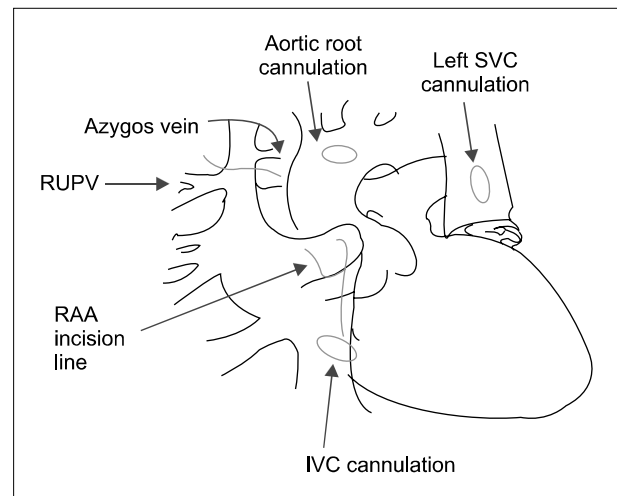
We have modified the Warden procedure by using a RA wall flap along with patch augmentation with autologous or bovine pericardium. In this report, we review the early and mid-term outcomes in patients with PAPVC connecting to the SVC treated using our modified Warden procedure.

## METHODS

### 1) Patient characteristics

The permission to retrospectively review medical records was obtained from the institutional review board of Samsung Medical Center. The need for individual consent for the study was waived.

From February 2005 to July 2012, 10 patients at Samsung Medical Center were treated with a modified Warden procedure for PAPVC connecting to the SVC. Diagnoses were performed using echocardiography or computed tomography.



**Fig. 1.** After standard cardiopulmonary bypass and cardioplegic arrest, we made a long U-shaped incision on the RAA and a longitudinal incision towards the IVC. The auricular flap was made to reach the posterior wall of the divided SVC. The longitudinal incision was made for the anterior patch and intracardiac repair. SVC, superior vena cava; RUPV, right upper pulmonary vein; RAA, right atrial auricle; IVC, inferior vena cava.

Cardiac catheterization was performed in three patients for evaluating the associated anomalies and pulmonary hypertension (Table 1).

Follow-up data were obtained through medical record reviews, referring cardiologists, or direct telephone contact with patients. The median follow-up duration was 29.5 months (range, 6.6 to 83.7 months). Electrocardiogram (EKG) and echocardiographic data were available for all patients. The categorical variables are presented as frequencies (%), and the numerical data are expressed as median values with ranges.

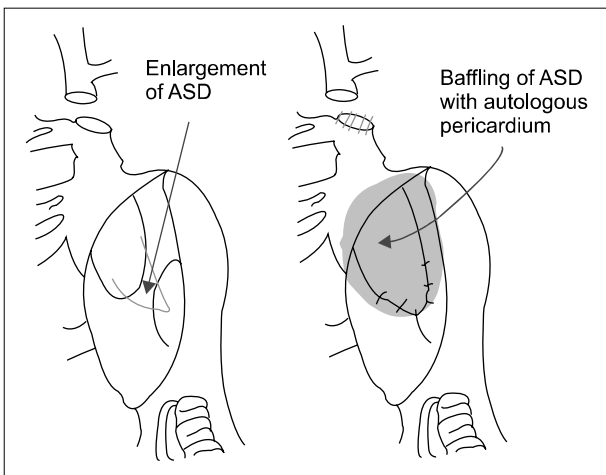
### 2) Operative technique

After standard median sternotomy, a large pericardial patch was harvested and treated with a 0.6% glutaraldehyde solution. The SVC was dissected circumferentially from the SVC-RA junction to the level of the innominate vein. The azygos vein was divided. Cardiopulmonary bypass was established by cannulation of the ascending aorta, inferior vena cava, and innominate vein. If the patient had a persistent left SVC (four patients), the left SVC was directly cannulated (Fig. 1). Using moderate hypothermia, we achieved cardiac arrest with intermittent antegrade cold-blood cardioplegia.

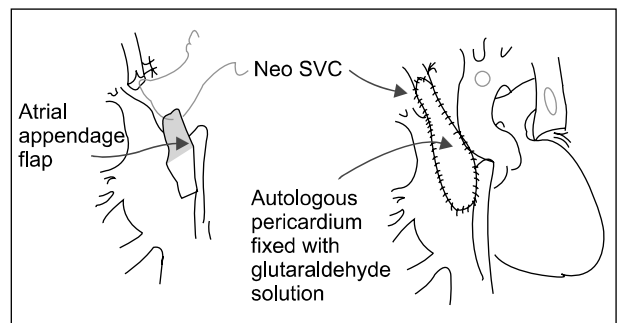
The SVC was divided just above the uppermost insertion of the anomalous pulmonary vein. The end of the proximal SVC was closed directly, and it served as a conduit for pulmonary venous drainage. Just below the oblique incision along the atrioventricular groove, another small longitudinal incision was made to create the atrial flap at the right atrial auricle (RAA) (Fig. 1). An autologous or bovine pericardial patch was sutured to the margin of the ASD on the SVC orifice to create a pulmonary venous pathway (Fig. 2). In the absence of an ASD, a large ASD was created in the fossa ovalis area and the sinus portion. If a small ASD was present, it was enlarged for creating a non-restrictive pulmonary

blood flow pathway. A RA flap was prepared for the posterior wall of the neo-SVC. The pectinate muscle in the RAA was resected to create a smooth atrial flap. This atrial flap was anastomosed to the distal end of the SVC for reconstructing the posterior SVC wall. The anterior wall of the neo-SVC was reconstructed with a generous autologous patch or with prosthetic materials (Fig. 3). We used 5-0 or 6-0 polypropylene suture for the reconstruction. Details of the surgical techniques employed herein are presented in Table 2.

Surgical correction of the associated cardiovascular anomalies was performed before or after the modified Warden procedure, as needed. Concomitant procedures included tricuspid annuloplasty in two patients, a modified Cox maze procedure in one patient, right ventricle-pulmonary artery conduit change in one patient, and subaortic muscle resection in one patient. The mean cardiopulmonary bypass time was



**Fig. 2.** The proximal end of the divided SVC was closed directly; it served as a conduit for pulmonary venous drainage to the left atrium through the ASD. To reconstruct the pulmonary venous pathway, the ASD was enlarged or newly created, and baffling from the SVC orifice to the ASD was performed using patch materials. SVC, superior vena cava; ASD, atrial septal defect.



**Fig. 3.** The distal end of the transected SVC was opened anteriorly and then, anastomosed to the edge of the right atrial auricle pedicle flap. This served as a posterior wall of the neo-SVC. The anterior wall of the neo-SVC was reconstructed with a large piece of patch. SVC, superior vena cava.

**Table 2.** Operative techniques and material used

Pathway	Procedure and materials	Patients (n=10)
Atrial septal defect	Extension	6
	Creation	3
	Left untouched	1
Pulmonary venous pathway (baffling)	Autologous pericardium	8
	Bovine pericardium	2
Systemic venous pathway (anterior wall augmentation)	Bovine pericardium	6
	Autologous pericardium	2
	Pulmonary artery homograft	1
	Iliac vein homograft	1

**Table 3.** Summary of latest F/U data

Patient	Age (yr)	Sex	Symptoms	EKG	Echocardiogram	F/U (mo)
1	31.9	F	None	NSR	No SVC or PV obstruction	76.8
2	1.1	F	None	NSR	No SVC or PV obstruction	83.7
3	5.0	F	None	NSR	No SVC or PV obstruction	80.4
4	35.5	M	None	NSR	No SVC or PV obstruction	29.9
5	6.3	M	None	NSR	No SVC or PV obstruction	31.6
6	4.7	M	None	NSR	No SVC or PV obstruction	29.2
7	58.1	F	None	NSR	No SVC or PV obstruction	20.1
8	50.0	M	None	NSR	No SVC or PV obstruction	16.6
9	1.2	F	None	NSR	No SVC or PV obstruction	6.6
10	1.0	F	None	NSR	SVC flow velocity (1.3 m/sec)	8.3

F/U, follow-up duration; EKG, electrocardiogram; NSR, normal sinus rhythm; SVC, superior vena cava; PV, pulmonary valve.

148.4±88.6 minutes, and the mean aortic cross-clamping time was 102.4±72.5 minutes.

## RESULTS

There were 6 female and 4 male patients. The median age at the time of surgery was 5.7 years (range, 1.0 to 58.1 years). All patients had PAPVC to the SVC or near the SVC-right atrium junction. In eight patients, pulmonary veins from segments confined to the right upper lobe were connected to the SVC. In the remaining two patients, veins from segments in addition to the right upper lobe were involved. Seven patients had the sinus venosus-type ASD (70%), two patients (20%) had an intact atrial septum, and one patient (10%) had patent foramen ovale. The associated cardiovascular anomalies included persistent left SVC in four patients, transposition of great arteries with ventricular septal defect in one patient, and double outlet of the right ventricle in one patient. Preoperative EKG showed normal sinus rhythm in eight patients, 1st degree atrioventricular block in one patient, and chronic atrial fibrillation in one patient.

We observed no early mortality, early reoperation, or surgical morbidities. At last follow-up, all patients were asymptomatic and had normal sinus rhythm on the EKG. All patients underwent postoperative echocardiogram. Nine patients had normal flow in the SVC, with unobstructed drainage of the pulmonary veins to the left atrium. In one patient, the SVC flow velocity was slightly increased (1.3 m/sec, estimated pressure gradient=6.76 mmHg), but there was no clinical evi-

dence of SVC obstruction (Table 3).

The eight patients with normal sinus rhythms did not develop any arrhythmias post-surgery. The PR interval of the patient with 1st degree AV block normalized after surgery. Chronic atrial fibrillation converted to a normal sinus rhythm after the Cox maze procedure. Thus, there were no new arrhythmias after surgery. No patient required re-operation or re-intervention for systemic or venous pathway stenosis at the last follow-up.

## DISCUSSION

Multiple surgical techniques have been previously reported for repairing PAPVC. The classic ones include intra-atrial baffling using one or two patches and repair with a RA flap. Warden et al. suggested a novel technique for connections of anomalous pulmonary veins [3]. The Warden procedure transfers the SVC to the RA appendage, while redirecting an anomalous pulmonary venous flow to the left atrium by using a single patch. This procedure essentially prevents the anatomical obstruction of the intracardiac blood flow. However, stenosis at the SVC-RA junction has been reported. Gustafson et al. [4] reported only one patient with SVC obstruction and sick sinus syndrome postoperatively in a series of 40 patients who underwent the Warden procedure. However, SVC obstruction developed two years after the Warden procedure in one patient from among a series of five patients, as reported by Stewart et al. [7]. This was attributed to a technical problem resulting from failure to excise all the trabeculations, as

reported by Warden et al. [3].

The potential causes of stenosis are trabeculations on the RA appendage or tension at the RA-SVC junction. Said et al. [13] suggested the use of vascular grafts between the SVC and the RA to decrease tension at the anastomosis. However, this modification may not be appropriate in pediatric patients because it may become too small as the child grows. Therefore, we modified the Warden procedure using an RAA flap and an autologous pericardium.

The technique called 'RA wall pedicled flap technique' has been described and clinically used by a few surgeons [10-12]. Nakahira et al. [12] used a pedicled autologous pericardial flap for anterior augmentation of cavoatrial anastomosis with the expectation of a sufficient channel and tension-free anastomosis growth potential. However, they did not use the 'RA wall pedicled flap technique.' Park et al. [10] reported the use of a modified Warden procedure in 9 cases, with the techniques used in three of these cases being seemingly similar to our technique, for tension-free anastomosis between the cephalic end of the SVC and the RA appendage where the anomalous pulmonary vein enters the more cephalic portion of the SVC. Tao et al. [11] reported that one patient from among their series underwent a similar modification as our patients did. In this study, we described the treatment of 10 patients with the same surgical technique, as well as their early and mid-term clinical outcomes.

As expected, we have not been required to perform any re-operation or re-intervention for obstruction or stenosis in the cardiac venous circulation. The tension-free anastomosis may decrease the risk of postoperative bleeding and thromboembolism. Therefore, this technique has become the standard procedure for surgical correction of PAPVC at our institution.

Sinus node dysfunction is a serious complication after the 1-patch or 2-patch technique, in which the incisions are placed close to the sinus node or its arterial supply [5-7,9]. No sinus node dysfunction was detected in any of the 11 patients from among a series undergoing the Warden procedure reported by Gaynor et al. [8]. Stewart et al. [7] did not report sinus node dysfunction in any of the 5 patients in their series who underwent the Warden procedure. Our modification was similarly associated with a low incidence of sinus node dys-

function, and no patients in our series newly developed arrhythmia during follow-up.

We believe that our technique may improve the classic Warden procedure in some ways. It always provides a wide tension-free anastomosis; there is no single circular suture line causing late stenosis; and patients do not need anti-coagulation because of a widely patent pathway and low rate of atrial arrhythmia. Therefore, our modified technique can be a viable option for surgically correcting PAPVC in both pediatric patients and adults. Our study is limited by our experience and the retrospective nature of this chart review. Because PAPVC is a rare situation, multi-institutional studies may be necessary. Our modification requires more complex suture lines than those in the original Warden procedure or other previous modifications. This may lead to technical difficulties, a steeper learning curve, or higher chances of bleeding. However, we believe that most experienced congenital cardiac surgeons are familiar with even such a complex suture. In addition, we did not experience any technical errors or postoperative bleeding. Thus, we believe that this is a readily reproducible technique.

In conclusion, the Warden procedure using the RA auricular flap and a biological patch for PAPVC treatment was correlated with satisfactory early and mid-term outcomes. Because this modification may decrease the risk of SVC obstruction and other possible complications associated with the Warden procedure, it can be considered a viable option in both pediatric and adult patients for surgically correcting PAPVC.

## CONFLICT OF INTEREST

No potential conflict of interest relevant to this article was reported.

## REFERENCES

1. Hijji T, Fukushige J, Hara T. *Diagnosis and management of partial anomalous pulmonary venous connection: a review of 28 pediatric cases.* Cardiology 1998;89:148-51.
2. Kyger ER 3rd, Frazier OH, Cooley DA, et al. *Sinus venosus atrial septal defect: early and late results following closure in 109 patients.* Ann Thorac Surg 1978;25:44-50.

3. Warden HE, Gustafson RA, Tarnay TJ, Neal WA. *An alternative method for repair of partial anomalous pulmonary venous connection to the superior vena cava.* Ann Thorac Surg 1984;38:601-5.
4. Gustafson RA, Warden HE, Murray GF. *Partial anomalous pulmonary venous connection to the superior vena cava.* Ann Thorac Surg 1995;60(6 Suppl):S614-7.
5. Trusler GA, Kazenelson G, Freedom RM, Williams WG, Rowe RD. *Late results following repair of partial anomalous pulmonary venous connection with sinus venosus atrial septal defect.* J Thorac Cardiovasc Surg 1980;79:776-81.
6. Stewart S, Alexson C, Manning J. *Early and late results of repair of partial anomalous pulmonary venous connection to the superior vena cava with a pericardial baffle.* Ann Thorac Surg 1986;41:498-501.
7. Stewart RD, Bailliard F, Kelle AM, Backer CL, Young L, Mavroudis C. *Evolving surgical strategy for sinus venosus atrial septal defect: effect on sinus node function and late venous obstruction.* Ann Thorac Surg 2007;84:1651-5.
8. Gaynor JW, Burch M, Dollery C, Sullivan ID, Deanfield JE, Elliott MJ. *Repair of anomalous pulmonary venous connection to the superior vena cava.* Ann Thorac Surg 1995; 59:1471-5.
9. Nicholson IA, Chard RB, Nunn GR, Cartmill TB. *Transcaval repair of the sinus venosus syndrome.* J Thorac Cardiovasc Surg 2000;119(4 Pt 1):741-4.
10. Park CS, Kwak JG, Lee C, et al. *Partial anomalous pulmonary venous connection to the superior vena cava: the outcome after the Warden procedure.* Eur J Cardiothorac Surg 2012;41:261-5.
11. Tao K, Pan W, Lin K, et al. *Modified cavoatrial anastomosis in Warden procedure.* Ann Thorac Surg 2010;89:2047-8.
12. Nakahira A, Yagihara T, Kagisaki K, et al. *Partial anomalous pulmonary venous connection to the superior vena cava.* Ann Thorac Surg 2006;82:978-82.
13. Said SM, Burkhart HM, Dearani JA, et al. *Outcome of caval division techniques for partial anomalous pulmonary venous connections to the superior vena cava.* Ann Thorac Surg 2011;92:980-4.