

단순절제술 이후 견봉쇄골 낭종에 합병된 무균성 누공 - 증례보고 및 문헌고찰 -

국립중앙의료원 관절센터 정형외과학교실

손민수 · 백덕인 · 이경학

Complicated AC Joint Cyst with Aseptic Fistula Secondary to Simple Excision - A Case Report and Review of Literature -

Min Soo Shon, M.D., Duck In Baek, M.D., Kyung Hag Lee, M.D.

Department of Orthopedic Surgery, Center for Joint Surgery, National Medical Center, Seoul, South Korea

Acromioclavicular (AC) joint cyst is an uncommon presentation around the shoulder joint that is usually associated with chronic rotator cuff pathology and degenerative AC joint arthritis. Understanding the underlying pathophysiology of the shoulder joint is essential for appropriate interpretation of the AC joint cyst, assistance in determining the therapeutic strategy, and prevention of complications after treatment. We present a case of AC joint cyst with an aseptic fistula which was complicated by simple excision for recurred AC joint cyst after multiple aspirations. This case revealed a massive rotator cuff tear involving supraspinatus, infraspinatus, and subscapularis tendon on ultrasonography. We also reviewed the clinical approach and treatment options to be considered for its pathogenesis in the literature.

Key Words: Shoulder, Acromioclavicular joint cyst, Aseptic fistula, Rotator cuff tear, Ultrasonography

Introduction

Acromioclavicular (AC) joint cyst is uncommon presentation around the shoulder joint. It is usually associated with chronic rotator cuff tear or cuff tear arthropathy with degenerative AC joint arthritis.¹⁾ Treatment options of AC joint cyst that have been discussed in the literature include observation, aspiration, simple cyst excision, and distal clavicle resection with or without rotator cuff repair, and glenohumeral

joint hemiarthroplasty.^{1,3-6)} Most authors emphasized that there is high recurrence rate if the cyst is simply treated, while overlooking the underlying rotator cuff pathology.^{1-3,5-9)} Furthermore, these inadequate approaches can even lead to draining fistula with the potential for deep infection.^{7,10)} Therefore, understanding the underlying pathophysiology of the shoulder joint is essential for appropriate interpretation of the AC joint cyst, assistance in determining the therapeutic strategy, and prevention of complications after treatment. We present a case of AC joint cyst with an aseptic fistula, which was complicated by simple excision for recurred AC joint cyst after multiple aspirations, and massive rotator cuff tear was detected on ultrasonography (US). We also reviewed the clinical

통신저자: 이 경 학
서울특별시 중구 을지로6
국립중앙의료원 관절센터 정형외과학교실
Tel: 02-2262-4707 Fax: 02-2278-9570
E-mail: smsice125@naver.com

* 본 논문의 요지는 2013년도 대한정형외과초음파학회 추계 학술대회에서 발표되었음.

approach and treatment options to be considered for its pathogenesis in the literature.

Case report

A 66-year-old, right-hand dominant male visited our outpatient clinic with painless, soft mass on the right acromioclavicular joint, which had incisional scar with a fistula that drained a small amount of serous fluid (Fig. 1). He has been working as a construction laborer over 30 years, and had an intermittent history

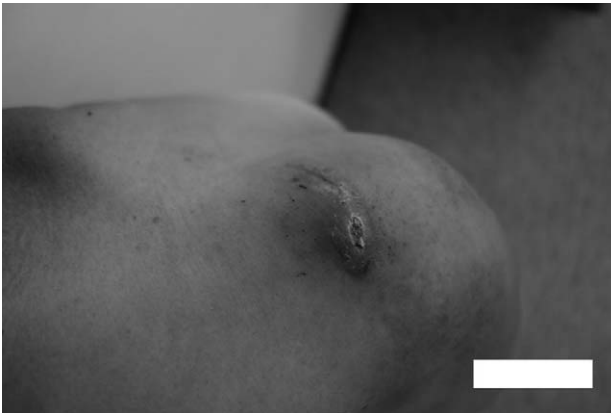


Fig. 1. Image of incisional scar with a fistula that drained small amount of serous fluid over the right acromioclavicular (AC) joint.

of mild discomfort during overhead activity. The cystic mass over AC joint had grown progressively for at least 6 months recently.

He already underwent simple aspiration of the lesion 3 times at a local hospital about 3 to 4 months ago, and the cyst recurred each time. Two months ago, he underwent simple excision twice with an interval of one week because of a rapid re-accumulation of the cyst after first simple excision. The draining fistula of the cyst developed 3 weeks after the second excision, and then the size of cyst fluctuated. The cyst led to a reduced size as serous fluid drained through the opening fistula, but the cystic size grew gradually after incomplete closure of the opening site. He denied any history of gout, inflammatory disease, or shoulder trauma.

On physical examination, there were no inflammatory signs, such as redness or local heat, around the AC joint. Active range of motion of the right shoulder was within nearly normal range with no pain, but he complained of mild pain at the terminal range of movement. Plain X-ray shoulder series of the right shoulder revealed an acromial spur, AC joint degeneration with AC joint space narrowing

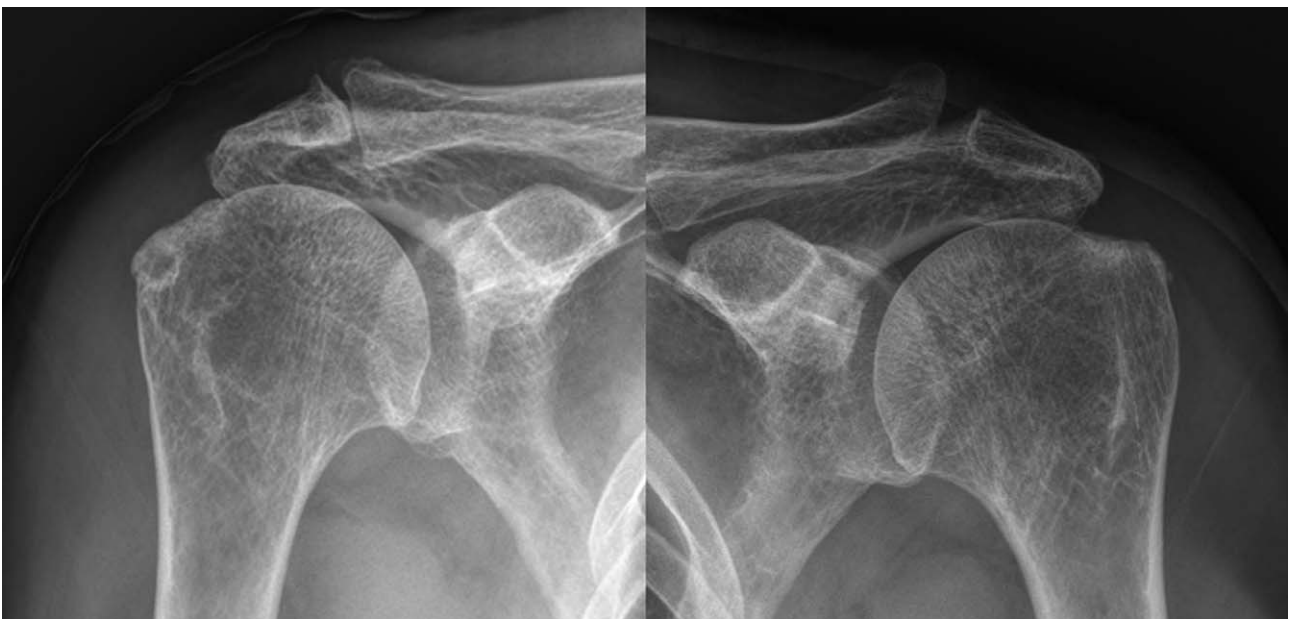

Fig. 2. Shoulder anteroposterior view on radiographs.

and osteophyte formation, superior migration of humeral head and sclerotic irregular cortical margin of the greater tuberosity (Fig. 2). Swab culture of the serous fluid was negative and blood test showed within normal limit of white blood cell count, erythrocyte sedimentation rate and reactive C-protein.

Ultrasound examination, which was performed with Zonare ultrasound system (Z.One, Zonare Medical Systems, Mountain View, CA, USA) with linear array (L14-5W) transducer, demonstrated the AC joint cyst and underlying rotator cuff pathology. Initially, the skin was cleansed and the probe was wrapped in aseptic

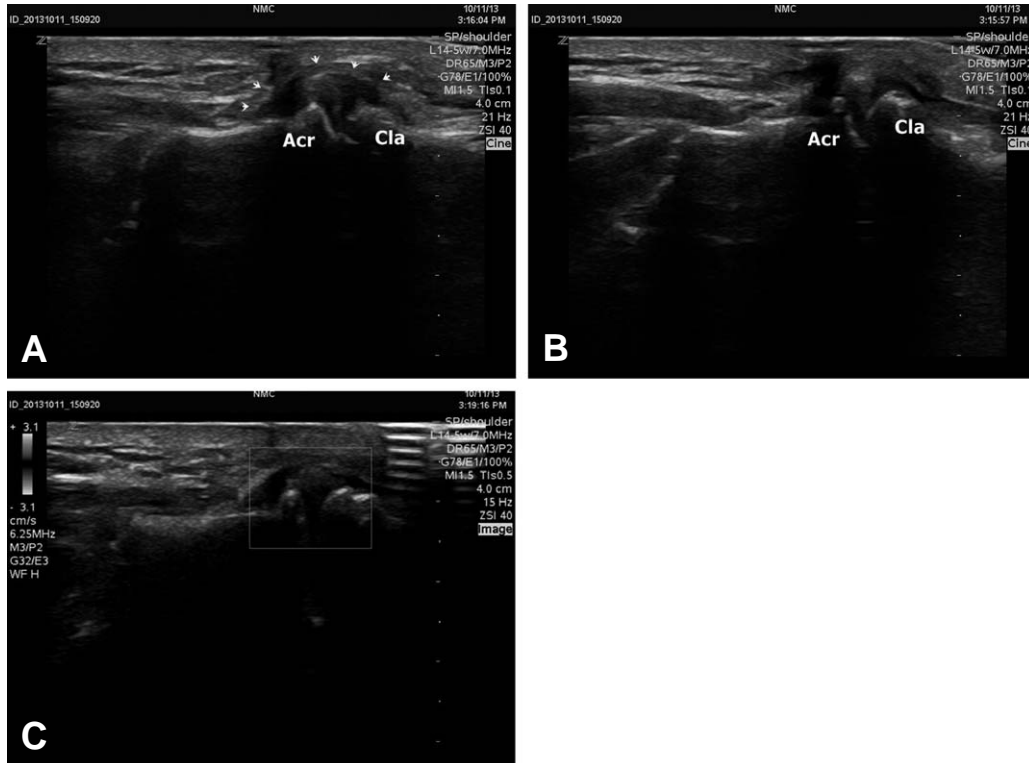


Fig. 3. On ultrasonography, (A) hypoechoic cystic distension (yellow arrowhead) of the AC joint capsule and (B) draining fistula track (red arrow) communicating with posterior aspect of the AC joint cyst was confirmed. The AC joint showed joint space narrowing and bony irregularity with osteophytes consistent with degenerative arthritis. (C) Doppler imaging demonstrated no flow in the mass. Acr: Acromial end, Cla: clavicular end

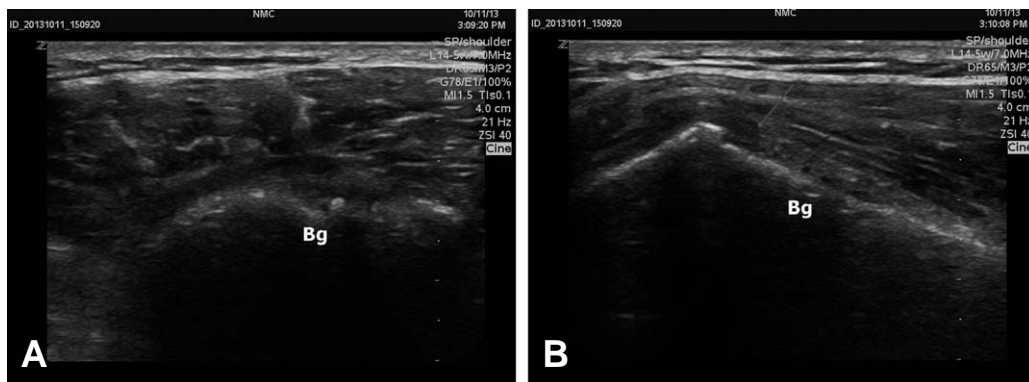


Fig. 4. The long head of biceps tendon was absent within the bicipital groove on (A) transverse and (B) longitudinal US scan. The groove distal to hypoechoic defect (red arrow) was filled with a poor defined, hetero-echoic signal.

surgical glove because of the risk of secondary infection. Diagnostic ultrasound was then performed with the patient sitting. On ultrasonography, hypoechoic cystic distension of the AC joint capsule (Fig. 3A) and fistula track communicating with the AC joint cyst (Fig. 3B) was confirmed. The AC joint showed

joint space narrowing and bony irregularity with osteophytes consistent with degenerative arthritis. Doppler imaging demonstrated no flow in the mass (Fig. 3C).

The long head of biceps tendon was absent within the bicipital groove on transverse US scan (Fig. 4A), and the groove distal to echoic

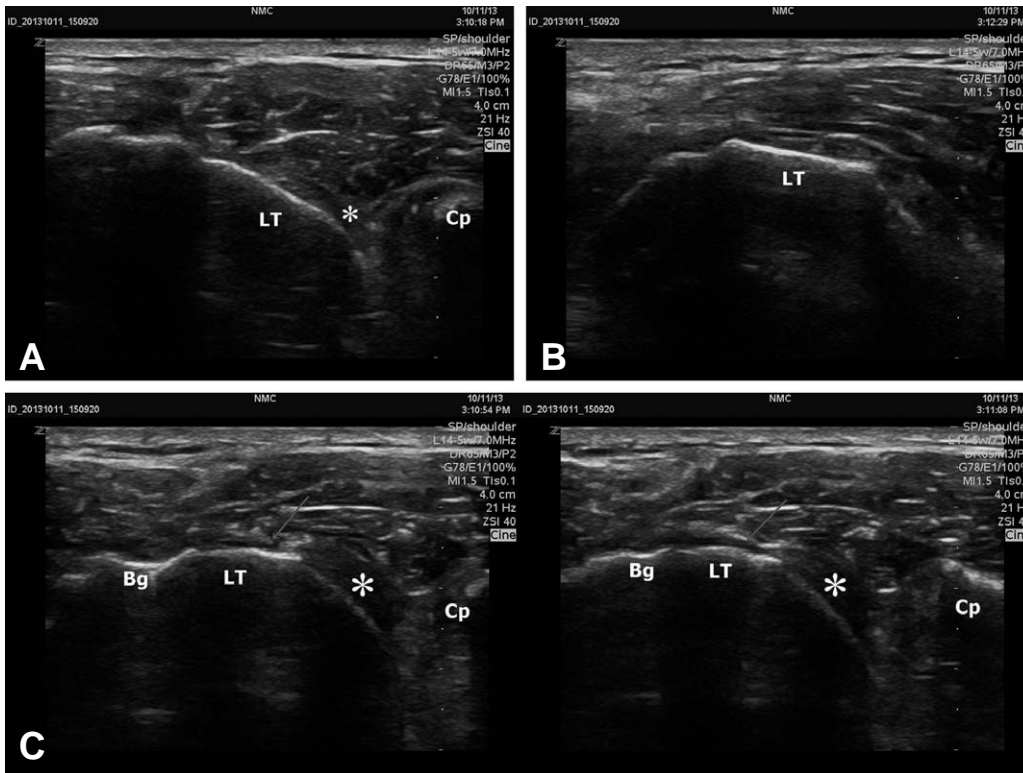


Fig. 5. (A) Longitudinal and (B) transverse scan to evaluate the subscapularis, the subscapularis tendon (yellow asterisk) was not visualized on its footprint. (C) In maximal external rotation of the arm, the torn (red arrow) and retracted subscapularis tendon was identified at the inferior and medial aspect of the lesser tuberosity footprint. Bg: Bicipital groove, Cp: coracoid process, LT: lesser tuberosity

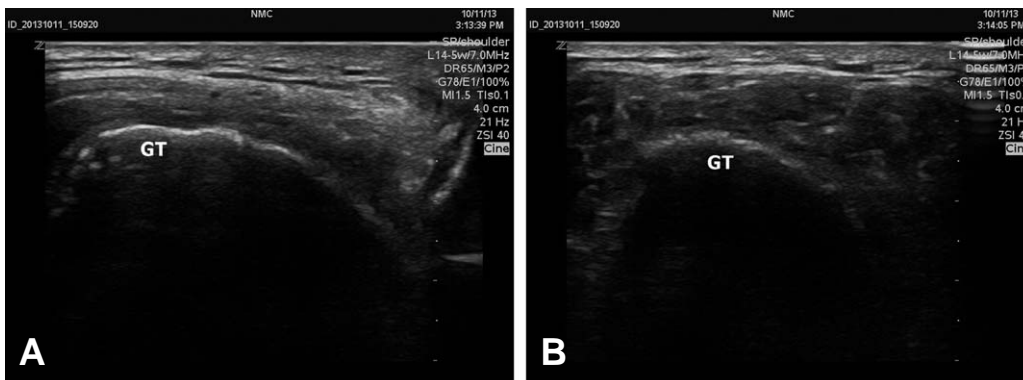


Fig. 6. Supraspinatus tendon was not visualized between deltoid muscle and humeral head on (A) longitudinal and (B) transverse scan. These findings indicate completely ruptured and retracted tendon. GT, greater tuberosity

defect was filled with a poor defined, hetero-echoic signal on longitudinal US scan (Fig. 4B). Longitudinal and transverse scan to evaluate the subscapularis (Fig. 5A, B), the subscapularis tendon was not visualized on its footprint (lesser tuberosity). In maximal external rotation of the arm, the torn and retracted subscapularis tendon was identified at the inferior and medial aspect of the lesser tuberosity footprint (Fig. 5C). Supraspinatus tendon was absent on its footprint (greater tuberosity) and flattening of the bursal surface on longitudinal and transverse US scan (Fig. 6). These findings indicated as complete ruptured and retracted tendon. Longitudinal US scan of infraspinatus tendon also showed hypoechoic defect on its footprint and thinning of the infraspinatus (Fig. 7). Considering the recurrence of the cyst with draining fistula and underlying rotator cuff pathology, we recommended the patient to undergo surgery, such as distal clavicle resection with or without rotator cuff repair. However, he refused any surgical treatment and wanted conservative treatment only for the draining fistula. During 2 months follow-up, the fistula of AC joint cyst spontaneously closed and the cyst itself had no recurrence. He refused any further

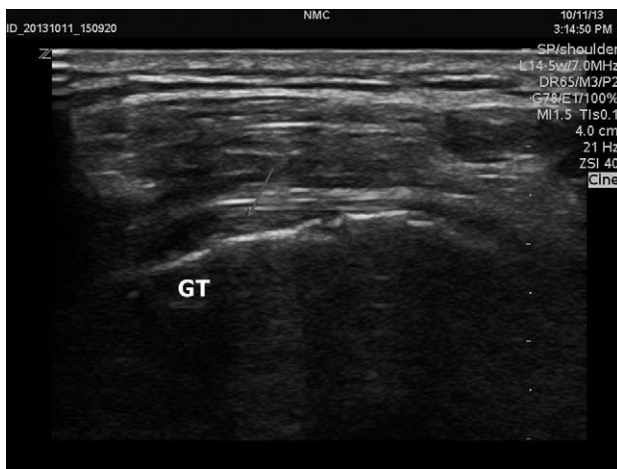

Fig. 7. Longitudinal US scan of infraspinatus tendon also showed hypoechoic defect on its footprint and thinning (red arrow) of the infraspinatus.

treatments due to lack of pain and satisfactory shoulder function and was lost to follow-up.

Discussion

We present a case of complicated AC joint cyst with an aseptic fistula resulting from multiple simple excision and aspiration, and massive rotator cuff tear combined with degenerative AC joint arthritis was detected on ultrasonography.

Although no consensus has been reached regarding the exact pathogenesis of the AC joint cyst, several authors have investigated a close relationship between AC joint cyst and rotator cuff pathology with or without degenerative AC joint arthritis.^{1,2,8)} This relationship was first described by Craig²⁾ in 1984 as a presence of the 'Geysler sign', where dye on shoulder arthrogram leaks from the glenohumeral (GH) joint and subacromial bursa through the torn cuff, into the AC joint cyst. Hiller *et al.*¹⁾ proposed that the high-riding humeral head causes damage to the inferior capsule of the AC joint, eventually allowing synovial fluid to flow from the GH joint into the AC joint. The migration damages the inferior capsule of AC joint and then pushes synovial fluid into the AC joint, with the deteriorated capsule acting as a 'pinch-valve' and sustaining the cyst.

This 'Geysler sign' and the relationship with the rotator cuff pathology to the AC joint cyst can be confirmed on various imaging modalities, such as arthrogram with X-ray or CT, and MRI. To date, two case reports have reported the use of ultrasound to investigate AC joint cyst with rotator cuff tear.^{4,9)} Although most AC joint cysts have been known to be associated with a rotator cuff pathology and AC joint arthritis, several other possible conditions, such as gout, trauma, tumor, infection, or other inflammatory dis-

eases, can be seen as an isolated soft tissue mass over AC joint. In this aspect, US can be a suitable tool to diagnose the cystic feature and vascularity of AC joint mass, the presence of underlying shoulder pathology, and identify other possible affections.

That has often been overlooked in clinical practice despite its importance as an initial or one of associated symptoms of the rotator cuff tear or cuff tear arthropathy. There is a high recurrence rate if the underlying rotator cuff pathology of AC joint cyst is overlooked. In addition, repeated aspirations or excision of these lesions is not recommended, and these repeated attempts may lead to formation of a draining fistula that mandates surgical attention. Murena *et al.*⁷⁾ reported a case of an AC joint cyst complicated by an aseptic fistula resulting from multiple aspirations, similar to our case, which was successfully treated with cyst excision and distal clavicle resection. Furthermore, a draining fistula complicated by simple aspiration or excision may lead to secondary infection of AC joint, even develop into subacromial space or glenohumeral joint infection. More recently, Cho¹⁰⁾ reported 2 cases involving an infected AC joint cyst with a massive rotator cuff tear caused by simple cyst excision.

The presence of an AC joint cyst should alert the orthopedic surgeon to consider a rotator cuff tear as an underlying pathogenesis, and it may be necessary to explain to the patients about the pathogenesis of the AC joint cyst and treatment options to prevent related complications. If the surgeon adequately excises the cyst in combination with distal clavicle excision, or surgical treatments addressing rotator cuff tears, there is low likelihood of cyst recurrence and further com-

plications. US may be one of the first line imaging modality in the setting of outpatient clinics, and the appropriate diagnostic tool in the assessment of the AC joint cyst and the presence of underlying rotator cuff tear.

참고문헌

1. **Hiller AD, Miller JD, Zeller JL.** *Acromioclavicular joint cyst formation. Clin Anat.* 2010;23:145-52.
2. **Craig EV.** *The geyser sign and torn rotator cuff: clinical significance and pathomechanics. Clin Orthop Relat Res.* 1984;191:213-5.
3. **Groh GI, Badwey TM, Rockwood CA Jr.** *Treatment of cysts of the acromioclavicular joint with shoulder hemiarthroplasty. J Bone Joint Surg Am.* 1993;75:1790-4.
4. **Moratalla MB, Gabarda RF.** *Acromioclavicular joint ganglion. Eur J Radiol Extra.* 2007;63:21-3.
5. **Mullett H, Benson R, Levy O.** *Arthroscopic treatment of a massive acromioclavicular joint cyst. Arthroscopy.* 2007;23:e1-4.
6. **Nowak DD, Covey AS, Grant RT, Bigliani LU.** *Massive acromioclavicular joint cyst. J Shoulder Elbow Surg.* 2009;18:e12-4.
7. **Murena L, D'Angelo F, Falvo DA, Vulcano E.** *Surgical treatment of an aseptic fistulized acromioclavicular joint cyst: a case report and review of the literature. Cases J. Published online Aug 7, 2009; doi: 10.4076/1757-1626-2-8388.*
8. **Cooper HJ, Milillo R, Klein DA, DiFelice GS.** *The MRI geyser sign: acromioclavicular joint cysts in the setting of a chronic rotator cuff tear. Am J Orthop.* 2011;40:E118-21.
9. **McCreech KM, Riley SJ, Crotty JM.** *Acromio-clavicular joint cyst associated with a complete rotator cuff tear-A case report. Man Ther. Published online Nov 23, 2013; doi: 10.1016/j.math.2013.11.004.*
10. **Cho CH.** *Complicated acromioclavicular joint cyst with massive rotator cuff tear. Am J Orthop.* 2014;43:70-3.

국문초록

견봉-쇄골 관절 낭종은 비교적 드물게 발생되나, 대부분의 경우 만성적인 회전근 개 질환과 퇴행성 견봉-쇄골관절염에서 동반된다. 이러한 병변에 대한 임상적 해석, 치료적 접근 및 치료 후 합병증을 최소화하기 위해서는 견관절 질환과의 병태생리학적 기전을 이해하는 것이 필수적이라 할 수 있다. 저자들은 단순 흡입술 후 재발되는 견봉-쇄골 낭종에 대한 추가적인 단순 절제술 이후 재발성 무균성 누공이 합병된 증례와 함께 초음파 검사상 누공을 가진 낭종성 병변과 동반된 광범위한 회전근 개 파열을 진단하였던 예를 경험하였기에 보고하고자 하며, 문헌고찰을 통하여 견봉-쇄골 관절 낭종의 발생 기전을 고려한 임상적 접근 및 치료적 방법들을 재조명하고자 한다.

색인단어: 견관절, 견봉쇄골 관절 낭종, 무균성 누공, 회전근 개 파열, 초음파