



Retrospective Study of Cysts in the Oral and Maxillofacial Regions: Statistical and Clinical Analysis

Hyun-Kyung Lee, Kyung-Sun Ryu, Moo-Gun Kim, Kwang-Won Park,
Ryun-Ga Kim, Sang-Hwa Roh, Tae-Young Jung, Sang-Jun Park

Department of Oral and Maxillofacial Surgery, Inje University Busan Paik Hospital

Abstract

Purpose: This study was designed for identification of the main clinicopathological features of cysts in the oral and maxillofacial regions.

Methods: A retrospective observational study was conducted on 164 patients who had been diagnosed with cyst of the jaw, from the database of 168 histopathological diagnoses at the Department of Oral and Maxillofacial Surgery of Busan Paik Hospital at Inje University, from January 2009 to December 2011. The subjects were treated and the following variables were recorded: gender, age, clinical signs and symptoms, histopathological distribution, treatment methods, and complications. A descriptive analysis of the study variables was performed using a chi-square test.

Results: Among the 164 patients, there were more male than female patients (male-female ratio: 1.7:1). The most predominant ages were the 20s and 40s. Among the classes of pathological cysts, radicular cysts and dentigerous cysts were the most common, with incidences of 56.0% and 35.1%. Thirty-six percent of the patients had no symptoms; and of those who had symptoms, the main signs and symptoms were swelling (24.4%) and pain (17.1%). The most frequent management method was the combination operation, such as enucleation with or without extraction and apicoectomy of the causative teeth. Of the 164 patients, 13 had complications; and one patient who had been treated with enucleation with apicoectomy had a recurrent cyst.

Conclusion: Using a chi-square test, no significant differences in prevalence were observed in relation to gender according to age. Comparative analysis of radicular and dentigerous cysts showed a significant difference in their prevalence according to their anatomical location, however, no significant differences in were observed in their incidence rates according to age.

Key words: Odontogenic cysts, Classification, Enucleation

Introduction

A cyst is an epithelial lined cavity filled with fluid or a soft material and usually grows from the internal pressure generated by the fluid being drawn into the cavity from osmosis. Cysts that arise from tissue that would normally

develop into teeth are referred to as odontogenic cysts. Other cysts of the jaws are termed non-odontogenic cysts (Table 1)[1]. As the cyst grows due to hydraulic pressure, it causes resorption of the surrounding bone, and may cause movement of teeth or other vital structures such as nerves and blood vessels, or resorption of the roots of

RECEIVED August 5, 2013, REVISED October 3, 2013, ACCEPTED November 22, 2013

Correspondence to Sang-Jun Park

Department of Oral and Maxillofacial Surgery, Inje University Busan Paik Hospital
75 Bokji-ro, Busanjin-gu, Busan 614-735, Korea
Tel: 82-51-890-6360, Fax: 82-51-896-6675, E-mail: ds5nki@hanmail.net

© This is an open access article distributed under the terms of the Creative Commons Attribution Non-Commercial License (<http://creativecommons.org/licenses/by-nc/3.0>) which permits unrestricted non-commercial use, distribution, and reproduction in any medium, provided the original work is properly cited.

Table 1. Classification of cysts (World Health Organization, 1990)

1. Developmental
A. Odontogenic
"Gingival cyst" of infants (Epstein pearls)
Odontogenic keratocyst (primordial cyst)
Dentigerous (follicular) cyst
Eruption cyst
Lateral periodontal cyst
Gingival cyst of adults
Glandular odontogenic cyst, sialodontogenic cyst
B. Non-odontogenic
Nasopalatine duct (incisive canal) cyst
Nasolabial (nasolabial) cyst
2. Inflammatory
A. Radicular cyst
Apical and lateral cyst
Residual cyst
B. Paradental (inflammatory collateral, mandibular infected buccal) cyst

adjacent teeth. Most cysts do not cause any symptoms and are discovered incidentally on routine dental radiographs. Cysts are usually unilocular, but may also be multilocular. In most cases, the cyst lining is sent to a pathologist for histopathological examination after it has been surgically removed. This means that the exact diagnosis of the type of cyst is often made in retrospect. Some cysts may not require any treatment; however, if they do, such treatment usually involves minor surgery for partial or complete removal of the cyst in a one- or two-stage procedure. There are four methods for management of cysts.

1. Enucleation: Removal of the entire cyst.

2. Marsupialization: Creation of a window in the wall of a cyst that allows drainage of its contents. The window is left open, and the lack of pressure in the cyst causes the lesion to shrink, as the surrounding bone starts to refill.

3. Enucleation following marsupialization: Marsupialization is sometimes performed as a single procedure; however, it is usually followed by a second procedure for removal of the cyst. This is particularly true when cysts are very large and their removal would leave a significant surgical defect.

4. Enucleation with curettage: This involves removal of the cyst and some of the surrounding bone, which may contain some of the lining of the cyst.

The prognosis depends upon the type, size, and location of a cyst. Rarely, if left untreated, some cystic lesions represent locally aggressive tumors that may destroy surrounding bones. This type of cyst area is usually removed with a margin of healthy bones in order to prevent recurrence

of new cysts. If a cyst becomes very large, the mandible may be so weak that a pathologic fracture occurs.

This study was conducted in order to follow the distribution, characteristics, histopathological diagnosis, and outcome of jaw cysts in a series of patients and for review of related literature.

Materials and Methods

During a three-year period (from January 2009 to December 2011), 164 patients (103 male and 61 female) with cystic lesions in their jaws were referred to the Department of Oral and Maxillofacial Surgery of Busan Paik Hospital at Inje University for consultation. All patients underwent clinical examination and plain film radiography (panoramic and periapical views). Some of them were referred for computed tomography (CT). Patients whose histopathological diagnosis by a general pathologist after surgical treatment did not confirm any type of cyst were excluded. Their age, gender, and cyst type and location were recorded. The patients were divided into four groups according to age (≤ 20 years, 21 to 40 years, 41 to 60 years, ≥ 61 years). The anatomical locations were classified according to causative teeth, anterior or posterior area. All analyses were performed using the statistical analysis system, IBM SPSS Statistics version 19.0 (IBM Co., Armonk, NY, USA). The Pearson chi-square test was used for comparison of age distribution and anatomic site between radicular cysts and dentigerous cysts. The level of significance was set at $P=0.05$.

Results

1. Gender and age

The gender and age distributions are shown in Fig. 1. A total of 164 patients, 103 of them men and 61 women (male-female ratio: 1.7:1), with a cyst on their jaw were referred. The gender distributions were as follows: in patients aged 41 to 60 years (67 patients, 40.9%), 49 patients were male and 18 patients were female; and in patients aged 21 to 40 years (59 patients, 36.0%), 35 patients were male and 24 patients were female. Using a Pearson chi-square test, no significant difference in the prevalence

rates was observed in relation to gender according to age ($P=0.105$, Fig. 1).

2. Clinical signs and symptoms

Most of the cysts had no symptoms (36%, 59 patients) and were discovered incidentally during a dental examination; however, their expansion may cause clinically noticeable displacement of teeth, and swelling and pain when the cyst enlarges or becomes secondarily infected. These signs and symptoms appear singly or in combination. In addition, some aggressive cysts even cause nerve injury

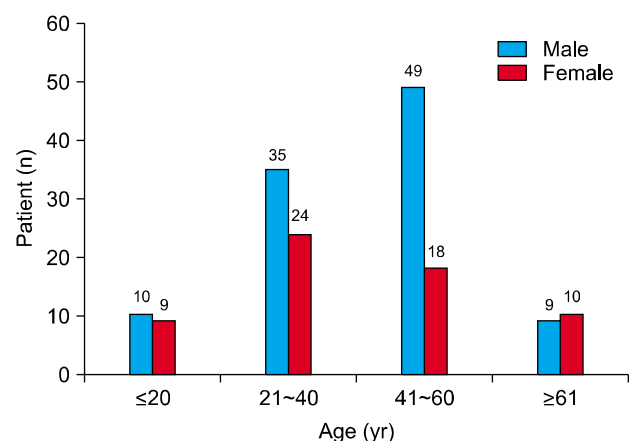


Fig. 1. Distribution of gender and age of cysts. By Pearson chi-square test, significant at $P<0.05$ ($P=0.105$).

and hypoesthesia (Table 2).

3. Histopathological distribution

The distribution of jaw cysts according to the histopathological diagnosis is as follows: radicular cysts, 56.0%; dentigerous cysts, 35.1%; odontogenic keratocysts, 3.6%; nasopalatine duct cysts, 3.6%; and postoperative maxillary cysts, 1.8% (Table 3). Incidence rates of the most common cysts, radicular and dentigerous cysts, showed no significant difference according to age ($P=0.263$).

4. Site distribution

Regarding the anatomic location (Table 4), 56.0% of cysts (94 of 168) were located in the mandible and 44.0% (74 of 168) in the maxilla. The most common sites of develop-

Table 2. Clinical signs and symptoms of cysts on the jaw

Symptom	Patient, n (%)
No symptom	59 (36.0)
Swelling	40 (24.4)
Pain	28 (17.1)
Pain and swelling	16 (9.8)
Pus	6 (3.6)
Tooth mobility	4 (2.4)
Hypoesthesia	2 (1.2)
Swelling and mouth opening limitation	1 (0.6)
Etc.	8 (4.9)
Total	164 (100.0)

Table 3. Histopathologic distribution of cysts according to age

Diagnosis	Age (yr)				Total	P-value*
	0~20	21~40	41~60	61~80		
Radicular cyst	7	37	39	11	94 (56.0)	0.263
Dentigerous cyst	10	21	24	4	59 (35.1)	
Other cysts	2	3	6	4	15 (8.9)	
Total	19 (11.3)	61 (36.3)	69 (41.1)	19 (11.3)	168 (100.0)	

*Pearson chi-square test, significant at $P<0.05$.

Values are presented as number only or number (%).

Other cysts: postoperative maxillary cyst, nasopalatine duct cyst, odontogenic keratocyst, simple bone cyst, primodal cyst.

Table 4. Histopathologic distribution of cysts according to anatomic site

Diagnosis	Maxilla		Mandible		Total	P-value*
	Anterior	Posterior	Anterior	Posterior		
Radicular cyst	44	10	9	31	94 (56.0)	0.001
Dentigerous cyst	8	3	2	46	59 (35.1)	
Other cysts	4	5	0	6	15 (8.9)	
Total	56 (33.3)	18 (10.7)	11 (6.5)	83 (49.4)	168 (100.0)	

*Pearson chi-square test, significant at $P<0.05$.

Values are presented as number only or number (%).

Other cysts: postoperative maxillary cyst, nasopalatine duct cyst, odontogenic keratocyst, simple bone cyst, primodal cyst.

ment were the posterior area of the mandible (49.4%, 83 cases) and the anterior area of the maxilla (33.3%, 56 cases). In the anterior area of the maxilla, the most common type of cyst was radicular cysts (46.8%, 44 cases). On the other hand, dentigerous cysts were most common in the posterior area of the mandible (55.4%, 46 cases). Comparative analysis of radicular and dentigerous cysts showed significant difference in their incidence rates according to their anatomical location ($P=0.001$).

5. Treatment methods

The treatment procedures primarily involved enucleation or marsupialization of the cyst. Tooth extraction, root canal treatment, and apicoectomy were also performed. A list of the treatment methods used is shown in Table 5.

6. Complications

Postoperative complications occurred in 13 of the 164 patients (7.9%). The most common types of complications were hypoesthesia (four patients), fistula (two patients),

tooth discoloration and fracture, sequester, and jaw fracture (Fig. 2). Only one patient experienced recurrence. After proper management of these complications, the healing process normalized and a favorable prognosis was achieved.

Discussion

A cyst is a unilocular or multilocular epithelium-lined cavity with various etiologies, which contains liquid or gaseous materials and develops in both hard and soft tissue. Bones of the jaws, the mandible, and the maxilla are the bones in the human body with the highest prevalence of cysts. This is due to the abundant amount of epithelial remnants in the jaw bones. Cystic jaw lesions may be epithelial or non-epithelial, odontogenic or non-odontogenic, and developmental or inflammatory in origin. The reasons why a resting epithelium may proliferate and undergo cystic transformation are generally unknown; however, inflammation is thought to be a major factor. The high prevalence of tooth impactions and dental infections in the jaw bones is also important in explaining why cysts are more common in these sites.

With regard to the gender, comparison of the results of this study with those published by other authors revealed several similarities. Tekkesin *et al.*[2] observed slightly greater prevalence in male patients (57.7%). Choi *et al.*[3] observed a similar frequency of males (64.5%). In this study, the male-female ratio was 1.7:1 (male: 63% and female: 37%). The highest frequencies were in patients aged 41 to 60 years (40.9%, 67 patients; male: 49 patients

Table 5. Treatment methods for cysts on the jaw

Treatment methods	Cyst, n (%)
Enucleation+RCT+apicoectomy	64 (38.1)
Enucleation+extraction	56 (33.3)
Enucleation+RCT+apicoectomy+extraction	26 (15.5)
Enucleation	15 (8.9)
Enucleation+RCT+extraction	3 (1.8)
Enucleation+RCT+apicoectomy+bone graft	2 (1.2)
Enucleation+RCT	1 (0.6)
Marsupialization+extraction	1 (0.6)
Total	168 (100.0)

RCT, root canal therapy.

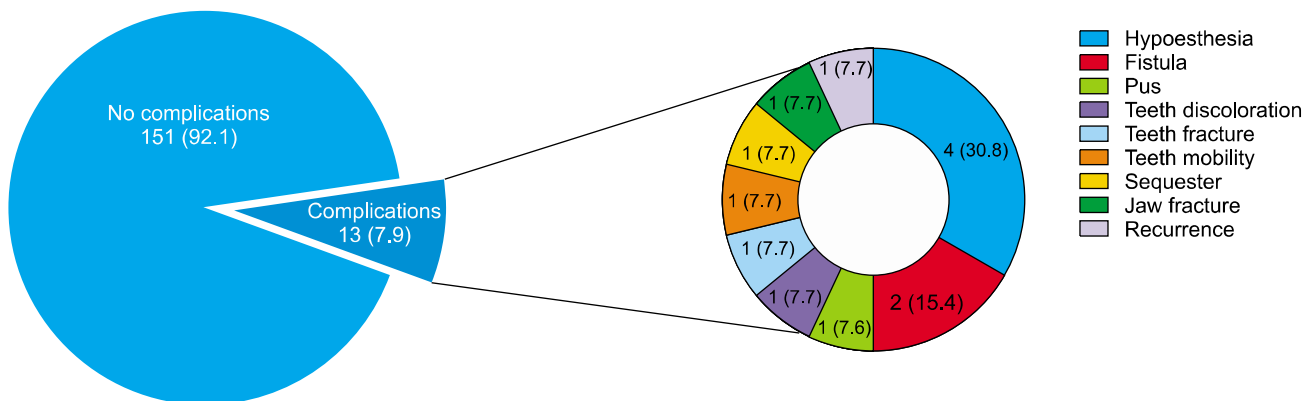


Fig. 2. Complications of cysts on the jaw. Values are presented as number (%).

and female: 18 patients) and 21 to 40 years (36.0%, 59 patients; male: 35 patients and female: 24 patients). On the other hand, Choi *et al.*[3] observed greater prevalence in patients in their 30s. Using a Pearson chi-square test, no significant difference in the prevalence rates was observed in relation to gender according to age ($P=0.105$, Fig. 1).

In most cases, after surgical removal of a cyst, it is sent to a pathologist for histopathological examination. This means that the exact diagnosis of the type of cyst is often made in retrospect. In this series, the most commonly diagnosed type of odontogenic cyst was the radicular cyst (56.0%), and this was consistent with the published results of the study reported by Nuñez-Urrutia *et al.*[4] (50.2%). The second most frequently diagnosed type of lesion was dentigerous cysts (35.1%), which coincided with the published results of the study reported by Nuñez-Urrutia *et al.*[4] (21.8%).

Cysts rarely have symptoms, unless they become secondarily infected. The signs depend primarily on the size and location of the cyst. If the cyst has not expanded beyond the normal anatomical boundaries of the bone, there will be no palpable lump outside or inside the mouth. The vast majority of cysts expand slowly, and the surrounding bone has time to increase its density around the lesion, which is the body's attempt to isolate the lesion. A cyst may become acutely infected and may be discharged into the oral cavity via a sinus. This may cause loosening, tilting, or even movement of adjacent teeth. The inferior alveolar nerve runs throughout the mandible and supplies sensations to the lower lip and chin. As most cysts expand slowly, there is often no altered sensation (anesthesia or paresthesia), because the inferior alveolar canal is harmlessly enveloped or displaced over time. More aggressive cysts, or acute infection of any cyst, may cause altered sensation.

Moon *et al.*[5] discovered that pain (48.3%) and swelling (24.1%) are the most common signs and symptoms of a dental cyst. Choi *et al.*[3] reported similar results: pain, 28.1% and swelling, 28.1%. In this study, the symptoms were also pain (17.1%) and swelling (24.4%). These signs and symptoms usually appear in combination.

Development of radicular cysts is common; their reported frequency varies from 7% to 54% of periapical radio-

lucencies[1]. The frequency of their occurrence in the maxilla is 60%[1]. Although they may occur in all tooth-bearing areas in the jaws, they usually occur in the maxillary anterior region. In this study, most of the radicular cysts were located in the anterior region of the maxilla (46.8%, 44 cases). Almost half of them (47.7%, 21 cases) were treated with a prosthetic or endodontic procedure due to luxation or fracture of the teeth before cyst formation.

The most common locations of dentigerous cysts are the mandibular third molars and the maxillary canines, and they rarely involve deciduous teeth and are occasionally associated with odontomas[1]. In this study, 78.0% of dentigerous cysts were located in the posterior region of the mandible (46 cases) and 13.6% in the anterior region of the maxilla (eight cases). Most dentigerous cysts on the posterior area of the mandible were associated with the third molar (95.7%, 44 cases), and only two were associated with an impacted second molar. Thus, if there is an impacted third molar in the jaw, preventive extraction of the impacted tooth or periodic follow-up through radiographical examination is needed in order to reduce occurrence of complications.

In a comparative analysis of radicular cysts and dentigerous cysts, the most common cysts, no significant differences were observed in their incidence rates according to age ($P=0.263$, Table 3), however, significant differences were observed in their anatomical location ($P=0.001$, Table 4).

Regarding treatment, the cystic enucleation procedure with or without tooth extraction predominated (99.0%), and periapical surgery such as apicoectomy (54.9%) and a bone graft (1.2%) was performed with enucleation or marsupialization. On the other hand, 8.9% were treated with enucleation only. This indicates the importance of complete removal of the origin of a cyst. The preceding figures show the relationships between the treatment methods and the complications observed during and after surgery.

The objective of treatment is to restore the morphology and function of the affected area. There are two basic surgical procedures: marsupialization (decompression) and enucleation. Marsupialization, a relatively simple procedure, involves surgically producing a 'window' in the cystic wall in order to relieve the intra-cystic tension, after which slow shrinkage of the cystic cavity occurs. Enucleation with

primary closure is the other treatment of choice. It is a one-stage surgical treatment procedure that can be performed only when the jaw bone adjacent to the cyst is still intact. If the CT shows erosions in the buccal or lingual cortex, marsupialization should be the treatment of choice[6].

Most cysts are entirely benign, and some may require no treatment at all. Rarely, if left untreated, some cystic lesions represent locally aggressive tumors that may cause destruction of surrounding bones[7,8]. Regarding complications during and after surgery, 13 (7.3%) of the 164 patients had complications from radicular cysts (five cases), dentigerous cysts (five cases), and odontogenic keratocysts (two cases). The most common complications were hypoesthesia (34%) and fistula formation (17%). Most types of cysts have a low recurrence rate; however, in odontogenic keratocysts, the recurrence rate has been reported as between 20% and 60%. This high recurrence rate is thought to be the result of the specific abnormal biology of this type of cyst.

Conclusion

1. Among a total of 164 patients, male patients were more common than female patients (male-female ratio: 1.7:1).

2. The patients mainly ranged in age from 41 to 60 years (67 patients; male: 49 and female: 18) and 21 to 40 years (59 patients; male: 35 and female: 24).

3. Using the Pearson chi-square test, no significant difference in the prevalence rates was observed in relation to gender according to age ($P=0.105$).

4. Among the pathological classes, radicular cysts and dentigerous cysts were the most common, with incidence rates of 56.0% and 35.1%, respectively.

5. Thirty-six percent of the patients had no symptoms; and among those who had symptoms, the main signs and

symptoms were swelling (24.4%) and pain (17.1%).

6. The most frequent management method was the combination operation, such as enucleation with or without extraction and apicoectomy of the causative teeth.

7. Among the 164 patients, 13 had complications; and one patient treated with enucleation with apicoectomy had a recurrent cyst.

8. Comparative analysis of radicular cysts and dentigerous cysts showed no significant differences in their incidence rates according to age ($P=0.263$); however, significant differences were observed in their anatomical location ($P=0.001$) using the Pearson chi-square test.

Knowledge of the biological behavior and clinicopathological features of jaw cysts enables early diagnosis and adequate surgery, and, thus, helps in the planning stage and in achievement of a good prognosis.

References

1. Neville BW, Damm DD, Allen CM, *et al*, editors. Oral and maxillofacial pathology. Philadelphia, PA: Saunders; 1995. p.493.
2. Tekkesin MS, Olgac V, Aksakalli N, Alatlı C. Odontogenic and nonodontogenic cysts in Istanbul: analysis of 5088 cases. *Head Neck* 2012;34:852-5.
3. Choi GH, Jang JR, Park YJ, *et al*. A 6-year retrospective study about cysts in the oral and maxillofacial region. *J Korean Assoc Maxillofac Plast Reconstr Surg* 2009;31:401-7.
4. Nuñez-Urrutia S, Figueiredo R, Gay-Escoda C. Retrospective clinicopathological study of 418 odontogenic cysts. *Med Oral Patol Oral Cir Bucal* 2010;15:e767-73.
5. Moon C, Lee DK, Min SK, Oh SH, Kim TS. Clinical study of Jaw Cysts. *J Korean Assoc Maxillofac Plast Reconstr Surg* 2000;22:301-9.
6. Lim SY, Yeo DS, Lee HJ, Kim HK, An KM, Sohn DS. A clinicostatistical study of jaw cyst between 2001-2005. *J Korean Assoc Oral Maxillofac Surg* 2006;32:588-93.
7. Richter M, Laurent F, Chausse JM. Homologous cancellous bone grafts for large jaw defects caused by bone cysts. *J Oral Maxillofac Surg* 1986;44:447-53.
8. Mosqueda-Taylor A, Irigoyen-Camacho ME, Diaz-Franco MA, Torres-Tejero MA. Odontogenic cysts. Analysis of 856 cases. *Med Oral* 2002;7:89-96.