

Brief Communication

## 지속기도양압으로 대량의 빠른눈운동반동을 보인 폐쇄수면무호흡

인제대학교 의과대학 부산백병원 신경과

정진호 · 지기환

### Massive REM Rebound on Continuous Positive Airway Pressure in Obstructive Sleep Apnea

Jin-Ho Jung, Ki-Hwan Ji

*Department of Neurology, Busan Paik Hospital, Inje University College of Medicine, Busan, Korea*

**Key Words:** Continuous positive airway therapy, Sleep apnea, REM rebound

Received 7 February 2014; received in revised form 28 July 2014; accepted 12 October 2014.

Usually REM sleep makes up 20% to 25% of total sleep time. Causes of an increased REM sleep proportion, so-called REM rebound phenomenon, are diverse such as REM sleep deprivation, withdrawal of REM-suppressing or -suppressing recreational drugs, depression or initial continuous positive airway pressure (CPAP) exposure.<sup>1</sup> Among them, REM rebound undergoing CPAP titration may be associated with the improvement of subjective sleep quality and further CPAP compliance.<sup>2</sup> Here, we report a case of obstructive sleep apnea and heart failure, which showed a remarkable REM rebound under successful CPAP titration.

#### Case Report

A 41-year old male visited the sleep clinic due to snoring

and frequent choking sensation during sleep. Three months ago, he had a diagnosis of dilated cardiomyopathy, hypertension, and dyslipidemia with symptoms of dyspnea on exertion. He was obese (body mass index, 30.08 kg/m<sup>2</sup>). He was a smoker and a social drinker. He complained of excessive daytime sleepiness (Epworth sleepiness scale, ESS, 18) and fatigue. Usually he went to bed at midnight, fell asleep within 10 min and woke up at 6:30 in the morning. Electrocardiography revealed left ventricular hypertrophy and first degree AV blocks. Chest x-ray showed voluminous heart and pulmonary edema. He took a standard in-lab polysomnography (PSG). Sleep latency was 16.5 min and REM latency was 75 min. PSG showed severe obstructive sleep apnea (apnea-hypopnea index, AHI, 60.1/h) with profound oxygen desaturation. Mixed apneas were prevalent and composed of 94% of respiratory events. REM-AHI and NREM-AHI was 45.6/h and 62.1/h, respectively. Baseline oxygen saturation, when he was waking up, was 89%. Average oxygen saturation during sleep was 75.9%, and the lowest was 55%. Percentage of oxygen saturation below 90% to the total sleep

Address for correspondence;

Ki-Hwan Ji

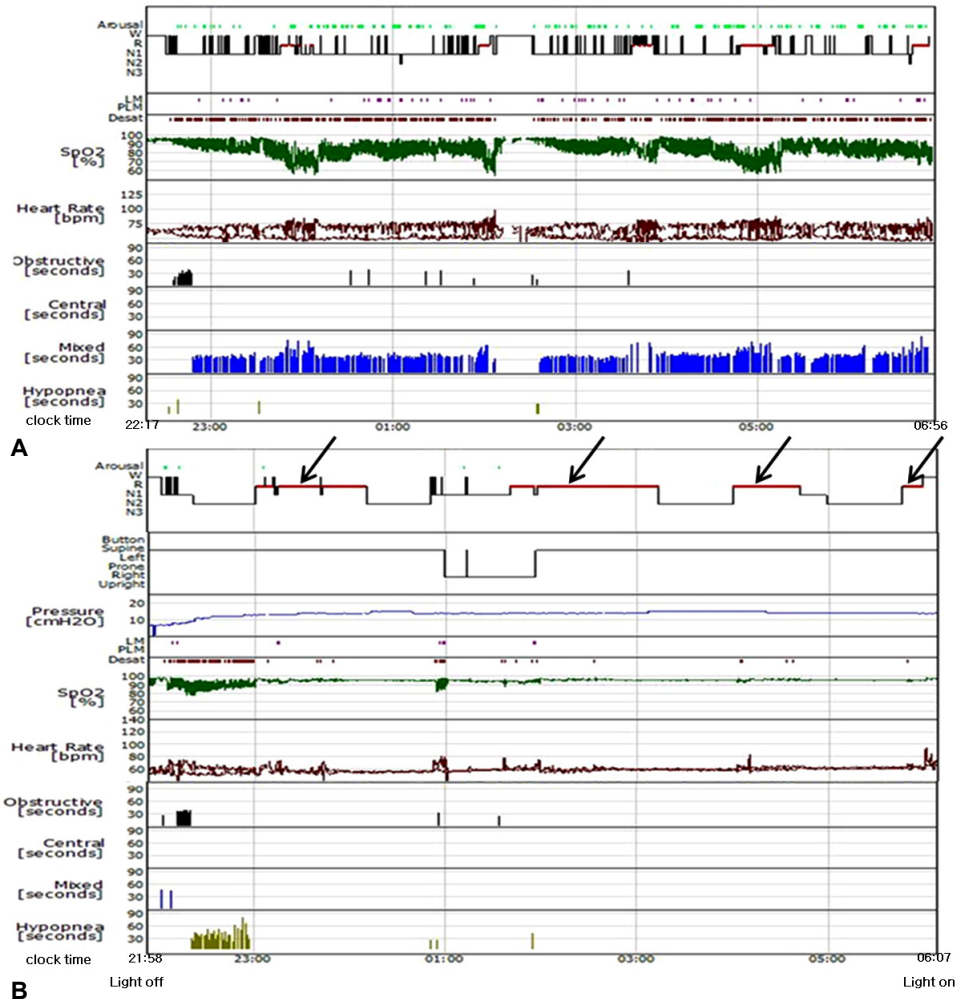
Department of Neurology, Busan Paik Hospital, Inje University College of Medicine, 75 Bokji-ro, Busanjin-gu, Busan 614-735, Korea

Tel: +82-51-890-8769 Fax: +82-51-895-6367

E-mail: kihwanji@gmail.com

Copyright 2014 by The Korean Society of Clinical Neurophysiology

This is an Open Access article distributed under the terms of the Creative Commons Attribution Non-Commercial License (<http://creativecommons.org/licenses/by-nc/3.0>) which permits unrestricted non-commercial use, distribution, and reproduction in any medium, provided the original work is properly cited.



**Figure 1.** Hypnogram of diagnostic polysomnography (A) and continuous positive airway pressure (CPAP) titration (B). Note the profound oxygen desaturation with sleep-disordered breathing regardless of sleep stage and sleep position. Sleep architecture was highly fragmented. REM proportion was relatively preserved, but slow wave sleep was absent. Optimal CPAP terminated sleep-disordered breathing and reduced arousals. Note the remarkable REM rebound (as designated by R in the y axis) with the arrows pointing to these areas of interest. REM; rapid eye movement.

time was 75.9%. Total sleep time was 421 min and sleep efficiency was 81.1%. N1 proportion was markedly increased (84.4%), and slow wave sleep (SWS) was absent. REM proportion was decreased (15.3%). Arousal index was 57.0/h and most arousals accompanied with respiratory disturbances (Fig. 1-A). Urgent CPAP titration was done successfully during 484 min. Total sleep time was 470 min and sleep efficiency increased to 94.9%. Sleep latency and REM latency was 10.9 min and 59 min, respectively. AHI and arousal index decreased to 7.3/h and 3.5/h respectively. Oxygen saturation

maintained above 90% with optimal CPAP pressure of 14 cmH<sub>2</sub>O. N1 proportion decreased to 17.9%, and N2 increased to 37.0%. SWS was absent. There was profound REM rebound phenomenon. REM sleep time was 212 min, and REM proportion was 45.1% (Fig. 1-B).

### Discussion

There is no established consensus about the cut-off value in defining REM rebound. Increased REM percentages over

20-25% usually seen in healthy human being may be reasonable. On the other hand, a recent study showed about 20% increase of the REM percentages under CPAP titration compared with those on diagnostic PSG satisfy the REM rebound.<sup>3</sup> REM restoration plays an important role in sleep quality improvement.<sup>2,3</sup> The degree of sleep changes after its first exposure to CPAP is somewhat a measure of pre-existing sleep disruption, and large REM change is likely reflecting significant prior sleep fragmentation.<sup>2</sup>

The patient entirely was satisfied with his quality of sleep immediately after CPAP titration, and he has kept a good compliance with the CPAP. The downloaded data from the CPAP machine showed 81% of the days of usage were more than four hours, and the mean duration of use was 6 hours 45 minutes per night over three months. He reported that his sleep and quality of life improved, and recent ESS was 9. Moreover, his blood pressure decreased without dosage adjustment of anti-hypertensive medication. These benefits of CPAP may be predictable with profound REM rebound on CPAP titration. Recent study showed that the diagnostic AHI was not associated with CPAP compliance, but the rebounding of REM sleep on the first exposure to CPAP is associated with early CPAP compliance up to 60 days.<sup>2</sup> As for this case, author believes that the termination of sleep-disordered breathing and sleep disruption, and stabilization of cardio-pulmonary states contributed to the REM rebound.<sup>2,4</sup> In general, half of patients with heart failure have sleep apnea and fewer sleeping hours, and they also suffer from interrupted sleep, which disrupt the normal relaxing effects on the car-

diovascular system.<sup>5</sup> On the contrary, absent SWS during CPAP titration is questionable. The propensity of SWS distribution on the early phase of sleep may be one of the explanations. The suboptimal CPAP in the early period of sleep may hinder the occurrence of SWS and its rebound. Some studies have shown that REM increase to a greater extent than SWS following first CPAP.<sup>2,6</sup> Interestingly, SWS was not associated with CPAP compliance.<sup>2</sup>

REM rebound on initial CPAP therapy may be a good sign implying prompt recovery of respiration, sleep quality and cardio-pulmonary circulation and may guarantee further CPAP compliance in OSA patient with heart failure.

## REFERENCES

1. Brass SD, Auerbach S. A sleepy patient with REM rebound. *J Clin Sleep Med* 2009;5:386-389.
2. Koo BB, Wiggins R, Molina C. REM rebound and CPAP compliance. *Sleep Med* 2012;13:864-868.
3. Brillante R, Cossa G, Liu PY, Laks L. Rapid eye movement and slow-wave sleep rebound after one night of continuous positive airway pressure for obstructive sleep apnoea. *Respirology* 2012;17:547-553.
4. McArdle N, Douglas NJ. Effect of continuous positive airway pressure on sleep architecture in the sleep apnea-hypopnea syndrome: a randomized controlled trial. *Am J Respir Crit Care Med* 2001;164:1459-1463.
5. Bradley TD, Floras JS. Sleep apnea and heart failure: Part I: obstructive sleep apnea. *Circulation* 2003;107:1671-1678.
6. Aldrich M, Eiser A, Lee M, Shipley JE. Effects of continuous positive airway pressure on phasic events of REM sleep in patients with obstructive sleep apnea. *Sleep* 1989;12:413-419.