

# The relationship of maxillary canines to the facial anatomical landmarks in a group of Thai people

Potchaman Sinavarat<sup>1\*</sup>, BSc, DDS, MSc, Chuchai Anunmana<sup>1</sup>, DDS, MSc, PhD, Sharafat Hossain<sup>2</sup>, BDS, MSc

<sup>1</sup>Department of Prosthodontics, Faculty of Dentistry, Mahidol University, Bangkok, Thailand

<sup>2</sup>Department of Prosthodontics, University Dental College & Hospital, Dhaka, Bangladesh

**PURPOSE.** The objective was to evaluate canine positions, intercanine tip width (ICTW) and width of distal surface of canine (WDC), related to facial landmarks including interalar width (IAW), intercommissural width (ICoW), and distance between left and right projection lines drawn from inner canthus of eyes to alae of the nose (DPICa) in a group of Thai. **MATERIALS AND METHODS.** One hundred Thai subjects aged 18-35 years were selected. IAW and ICoW were measured on subject's face using digital vernier caliper. Irreversible hydrocolloid impression of the upper arch was taken, and a cast was poured with dental stone. Silicone impression material was used to take imprint of the incisal edge of upper six anterior teeth. DPICa was obtained from the subject's face using custom-made measuring equipment and marked on the silicone incisal imprint. The marks were then transferred from the imprint to the stone cast and measured with digital caliper. The ICTW and WDC were also measured on the stone cast. Pearson's correlation was used to determine the correlation. **RESULTS.** The results revealed that the correlation between ICTW-ICoW was 0.429 and ICTW-DPICa was 0.573. The correlation between WDC-ICoW was 0.426 and WDC-DPICa was 0.547. However, IAW did not show any correlation with ICTW or WDC ( $P>.05$ ). **CONCLUSION.** The correlation between canine position and facial landmarks was found. ICTW and WDC had relationship with ICoW and DPICa. DPICa showed stronger correlation with the position of maxillary canine than that of ICoW. [J Adv Prosthodont 2013;5:369-73]

**KEY WORDS:** Complete denture; Canine; Canthus; Alae

## INTRODUCTION

Esthetics is one of the major concerns for patients seeking prosthetic treatment. In completely edentulous patients, it is difficult to successfully place the denture teeth in the same position as natural teeth and conform to the normal physiological oral activities. Selection and positioning of esthetic and pleasing artificial teeth depend on many fac-

tors. Facial and oral anatomical landmarks can be of great value when there are no pre-extraction records available.

The position of the canine is critically important in denture teeth arrangement because it provides tissue support at the corner of the mouth and its position is in the turning point of the dental arch. Therefore, the position of the canines is the principle factor to be considered in complete denture esthetics. In addition, the correct position of the canines can provide valuable information for selecting the size of upper anterior teeth.

Several suggestions are offered as guidance when marking the canine line on the upper occlusion rim. First, it has been stated that the approximate location of the distal surface of the upper canines can be indicated by marks made on the upper occlusion rim at the corner of the mouth.<sup>1-3</sup> Second, the canine line is marked by extending the vertical parallel lines from the lateral surface of the alae of the nose on to the labial surface of the upper occlusion rim. This line indicates the estimation of the position of the tip of the upper canine.<sup>2,3</sup> Third, the projection of a line drawn

Corresponding author:  
Potchaman Sinavarat  
Department of Prosthodontics, Faculty of Dentistry, Mahidol University,  
Bangkok, Thailand  
Tel. 6622007817; e-mail, potchaman.sin@mahidol.ac.th  
Received September 17, 2012 / Last Revision October 14, 2013 /  
Accepted October 16, 2013

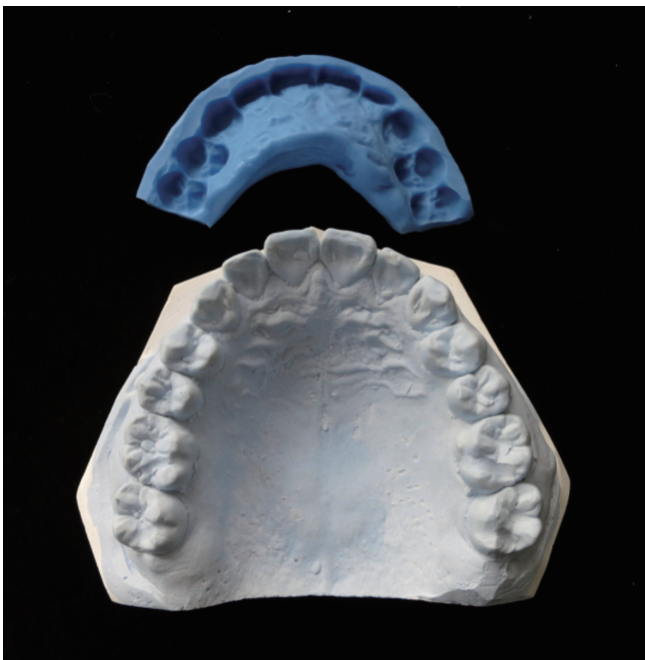
© 2013 The Korean Academy of Prosthodontics  
This is an Open Access article distributed under the terms of the Creative  
Commons Attribution Non-Commercial License (<http://creativecommons.org/licenses/by-nc/3.0>) which permits unrestricted non-commercial use,  
distribution, and reproduction in any medium, provided the original  
work is properly cited.

from the inner canthus of the eye to the alae of the nose passes through the upper canine tooth.<sup>4</sup> Several studies have been conducted in the past 4-5 decades for marking the canine line. Latta *et al.*<sup>5</sup> studied in the North American subjects and found no correlation between intercommissural width, interalar width and/or interpupillary width. Varjão and Nogueira<sup>6</sup> found a weak correlation between intercommissural width and distal of the surfaces of canines for four different racial group. However, Hasanreisoglu *et al.*<sup>7</sup> and al-el-Sheikh and al-Athel<sup>8</sup> found positive correlation between intercanine tip width and interalar width on their studies. As the canine position has been based on facial anatomical structures, this may relate to individual race. Very few studies regarding the relationship of the canines to the facial landmarks have been performed in Asian people. The objective of this study was to determine the relationship between maxillary canine position and the facial landmarks including interalar width, intercommissural width, and the distance between the left and right projection of the line drawn from the inner canthus of the eye to the alae of the nose in a group of Thai people.


## MATERIALS AND METHODS

The experiment was held at the Faculty of Dentistry, Mahidol University. The proposal and the procedure of the study were reviewed and approved by Mahidol University Institutional Review Board (COA No. MU-IRB 2010/182.0806). One hundred Thai subjects of both sexes rang-

ing from 18-35 years of age were selected. They all had complete intact dentition except third molar, no crowding, never been orthodontically treated, no crown reconstruction of upper six anterior teeth, without abnormal and altered nose. The subjects were grouped by gender and arch form to determine the effect of these two factors on the correlation of the measurement. A maxillary stone cast (Fig. 1) was made of each subject from an irreversible hydrocolloid impression (Jeltrate, Dentsply International, NY, USA). Intercanine tip width (ICTW) and width of the distal surface of canine (WDC) were measured from the stone cast with digital caliper (Mitutoyo, Kawasaki, Japan). Interalar width and intercommissural width were measured on the subjects' faces with digital caliper. No pressure was applied during measurements. To measure the distance between left and right projection of the line drawn from inner canthus of the eyes to the alae of the nose (DPICa), the imprint of the incisal edges of the maxillary anterior teeth and the occlusal surface of the premolar were prepared on the maxillary cast using silicone impression material (putty type) (Silagum, DMG, Chemisch Pharmazeutische Fabrik, Hamburg, Germany) (Fig. 1). The thickness of the silicone imprint was 2 mm. The subjects were asked to sit comfortably in upright position and bit on the silicone imprint with the lips in contact lightly. The customized equipment (Fig. 2) was used for marking the projection line from inner canthus of the eye to the alae of the nose extending to the silicone imprint. The chin was placed on the chin support of the designed equipment. The adjustable flags were placed over the subject's face while their eyes were closed. The flags were adjusted to place over the inner canthus of the eyes and contact the outer surface of the alae lightly (Fig. 3). The projection of the lines obtained from the placement of the flags was marked on the silicone



**Fig. 1.** The silicone imprint of the incisal edges of maxillary anterior teeth and the occlusal surface of the premolar obtained from the stone cast.



**Fig. 2.** The equipment for marking the projection of the line drawn from inner canthus of the eye to alae of the nose (top view).


imprint using a Roach wax carver (Fig. 4). The silicone imprint was then placed on the incisal edges of the maxillary stone cast to transfer the marks from the imprint to the labial surface of the teeth on the cast using a pencil. The straight-line distance between the left and right dots were measured using a digital vernier caliper (Fig. 5).

One operator performed all the measurements. The dimensions were recorded to an accuracy of 0.01 mm. All measurements were repeated three times on three separate occasions and average values were calculated. Multiple regression analysis was used to determine the influence of independent variables on intercanine tip distance and distance between distal surfaces of canines. The independent variables were gender, arch form, IAW, ICoW and DPICa.

## RESULTS

From one hundred subjects, 52 subjects had ovoid arch, 32 had tapering arch, and 16 had square arch forms. Table 1 shows number of subjects, which were classified by arch form and gender.

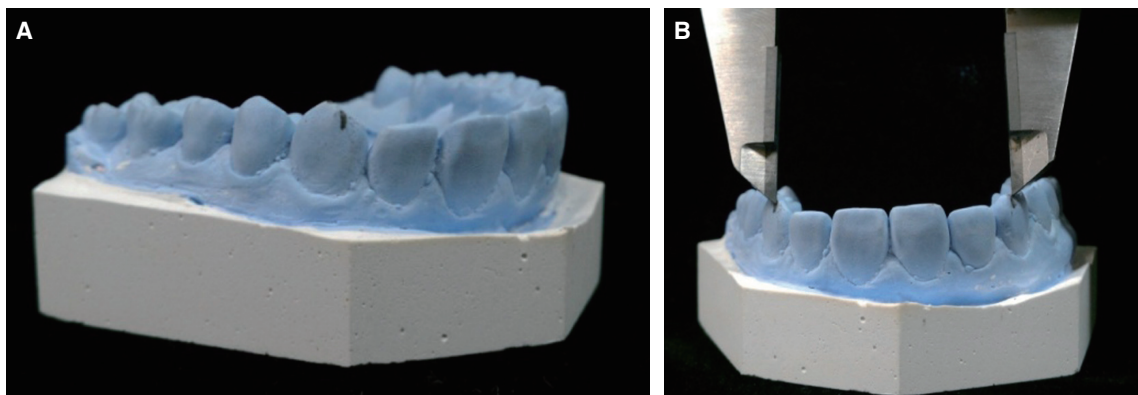
To detect outliers for each variable, the raw data were converted into standard scores, which had a mean of 0 and standard deviation of 1. The data that had the standard score greater than 3 or lesser than -3 were identified as outliers. As a result, one subject was excluded from this study because it was recognized as an outlier for ICTW. Therefore, the total number of subjects was 99 for further statistical analysis. Pearson's correlation ( $r$ ) showed the strength of



**Fig. 3.** The adjustable flag of the equipment touching the inner canthus of the eye and alae of the nose.



**Fig. 4.** Projection of the line was marked on the silicone imprint using a Roach wax carver.



**Fig. 5.** (A) The marks on the silicone imprint were transferred to the stone cast, (B) The straight-line distance between the two marks was determined.



**Table 1.** Number of subjects classified by arch form and gender

	Arch form			Total
	Ovoid	Tapering	Square	
Male	22	10	7	39
Female	30	22	9	61
Total	52	32	16	100

**Table 2.** Correlation coefficient of measurement variables with ICTW and WDC

		IAW	ICoW	DPICa
ICTW	r	.035	.429*	.573*
WDC	r	.149	.426*	.547*

\*(P value <.05)

the relationship of ICTW and WDC with other measurement variables. Both the ICoW and DPICa showed correlation with ICTW and WDC ( $P < .05$ ). However, IAW did not show any correlation with either ICTW or WDC ( $P > .05$ ) (Table 2).

Since the canine positions, ICTW and WDC, were functionally dependent on two different variables (ICoW and DPICa), multiple linear regression was employed to combine these two independent variables and the other two categorical variables (gender and arch form) to confirm if it provided a better determination of ICTW and WDC.

As the gender and arch form are nominal scale variables, a dummy variable or indicator variable was used in the regression equation.<sup>9</sup> For this analysis, the following dummy variables were used for statistical analysis:

Gender: male = 1; female = 0

Arch form: square = 0-0

ovoid = 0-1

tapering = 1-0

To detect multivariate outliers, standardized residual value, which was greater than 3 or lesser than -3 was excluded from the analysis. After statistical analysis, it was found that only arch form was a significant determinant of ICTW; however, both arch form and gender had no effect on WDC. As a result, the predictive equation for ICTW and WDC of this group of subjects were the followings:

1.  $ICTW = 19.37 - 0.81 \text{ arch form}^* + 0.29 \text{ DPICa} + 0.11 \text{ ICoW}$   
\*where tapering arch form equals 1, and ovoid and square arch forms equal 0.

Coefficient of determination ( $R^2$ ) = 0.434

Therefore, for tapering arch form;

$ICTW = 18.56 + 0.29 \text{ DPICa} + 0.11 \text{ ICoW}$

For ovoid and square arch forms;

$ICTW = 19.37 + 0.29 \text{ DPICa} + 0.11 \text{ ICoW}$

2.  $WDC = 21.98 + 0.26 \text{ DPICa} + 0.14 \text{ ICoW}$

Coefficient of determination ( $R^2$ ) = 0.378

## DISCUSSION

It is well accepted that the accuracy of the measurement is suspect when the measurements are made on the soft tissue. As both the inner canthus of the eye and the alae of the nose are soft tissue, and they are mobile in nature, special consideration must be taken to minimize errors during taking these measurements. Moreover, the patient's head position and stability may also influence these measurements. To improve the accuracy, in this study, customized equipment was used to mark the projection line from the inner canthus of the eye to the alae of the nose extending to the occlusal level. The chin rest helped to stable the subject's head during marking. Thin stainless steel sheet was used as the adjustable flag to get accurate direction of the projection line in a sagittal plane. This made the measurement more consistent. To minimize errors during measurement in the subject's mouth, the distance between the right and left projection of the line from the inner canthus of the eye to the alae of the nose extending to the occlusal level were marked on the silicone imprint and the distance was measured on the cast. Many researchers have used the curved line distance between ICTW and WDC while correlating the maxillary canine position with interalar width and intercommissural width.<sup>6,10</sup> However, straight-line distances between the tips of the canines and width of the distal surfaces of the canines were measured in this study. It was due to the fact that the purpose of the study was to evaluate the position of canine rather than the mesiodistal width of the anterior teeth. Therefore, measuring the straight line could minimize errors occurring when the curvature of anterior teeth were measured.

The result suggested that the canine tooth position, ICTW and WDC, showed correlation with both ICoW and DPICa. The DPICa had a higher correlation with both ICTW and WDC ( $r = 0.573$  and  $0.574$  accordingly) than that of ICoW and IAW. This result disagrees with Latta *et al.*<sup>5</sup> and Yodsuan *et al.*<sup>11</sup> They measured the straight line between canine and found no correlation between the canine position and intercommissural width. However, previous researchers did not report the correlation between canine position and DPICa. The result also revealed that there was no correlation between IAW-ICTW and IAW-WDC in this subject group. This is in agreement with Varjão and Nogueira<sup>6</sup> and Smith.<sup>12</sup> They concluded that the nose would not be a reliable guide to select the artificial anterior teeth.

Although the correlation found in this study was not high, clinicians could use ICoW and DPICa to estimate the position of the canine for construction of prosthesis for edentulous patients. Since the canine position is influenced by many variables, it would be a mistake to claim that either facial landmark was proven superior by this research effort. Evaluation of the canine position by contouring the occlusion wax rim to obtain adequate lip support and optimal occlusal vertical dimension and then marking the canine line must be considered as a tentative method. The final decision should be made when the clinician evaluates the

appearance of each patient.<sup>1</sup>

Generally, the arch form contributes to the face form. People who have narrow tapering arch usually have narrow tapering face.<sup>1</sup>

Changing the position of the artificial teeth from the natural alignment causes an unsatisfactory loss of face form and facial expression.<sup>13</sup> It seems that the canine position should have correlation with the arch form, but according to this study, this conclusion cannot be drawn. The result revealed that only the arch form was a significant determinant of ICTW but had no effect on WDC. The inconsistent result was probably due to the error in the technique used to classify arch form. In this study, the arch form was classified by direct vision, as it was a routine clinical practice. However, some of the casts appeared to have the combination of arch forms, which might affect the result. Regarding the gender, it was found that gender had no effect on both ICTW and WDC.

Generally, facial appearance varies between ethnic groups. Moreover, it is not possible to confirm that each subject in this study was native Thai. People with Thai nationality may be of ethnic differences. Some may be a mixture of Thai and Chinese and others may be Thai and Cambodian or Malaya, etc. Moreover, there might be some other factors that influence the position of canine which were out of the scope of this study. Therefore, facial landmarks cannot be too strongly emphasized when a dentist wants to provide complete dentures with pleasing appearance. Esthetic that matches to each individual and phonetic outcome should be concerned more.

## CONCLUSION

Within the limitation of this study, it can be concluded that both ICTW and WDC had a relationship with ICoW and DPICa. The DPICa had stronger correlation with both ICTW and WDC. However, the facial measurements studied in this article could be used to establish only tentative determination of the canine position for complete denture fabrication. Esthetic and phonetic outcomes should be considered as another help in verifying the location of maxillary canines.

## REFERENCES

- Hickey JC, Zarb GA. Boucher's prosthodontic treatment for edentulous patient. 8<sup>th</sup> ed. St Louis: CV Mosby; 1980, p. 322-5.
- Rahn AO, Heartwell CM Jr. Textbook of complete dentures. 5<sup>th</sup> ed. Philadelphia: Lea & Febiger, 1993. p. 272.
- Wehner PJ, Hickey JC, Boucher CO. Selection of artificial teeth. *J Prosthet Dent* 1967;18:222-32.
- Basker RM, Davenport JC. Prosthetic treatment of the edentulous patient. Oxford: Blackwell Munksgaard, Blackwell Publishing Company, 2002, p. 172-202.
- Latta GH Jr, Weaver JR, Conkin JE. The relationship between the width of the mouth, interalar width, bizygomatic width, and interpupillary distance in edentulous patients. *J Prosthet Dent* 1991;65:250-4.
- Varjão FM, Nogueira SS. Intercommissural width in 4 racial groups as a guide for the selection of maxillary anterior teeth in complete dentures. *Int J Prosthodont* 2005;18:513-5.
- Hasanreisoglu U, Berksun S, Aras K, Arslan I. An analysis of maxillary anterior teeth: facial and dental proportions. *J Prosthet Dent* 2005;94:530-8.
- al-el-Sheikh HM, al-Athel MS. The relationship of interalar width, interpupillary width and maxillary anterior teeth in Saudi population. *Odontostomatol Trop* 1998;21:7-10.
- Zar JH. *Biostatistical Analysis*. 5<sup>th</sup> ed. Upper Saddle River, NJ: Prentice Hall; 2010, p. 419-57.
- Gomes VL, Gonçalves LC, Costa MM, Lucas Bde L. Interalar distance to estimate the combined width of the six maxillary anterior teeth in oral rehabilitation treatment. *J Esthet Restor Dent* 2009;21:26-35.
- Yodsuan D, Srisamaung J, Santaveesuk O, Srinukul S. Relationship between canine lines, cusp tips and distal of the maxillary canines and corners of the mouths in the Thai Esarn sample. *Khon Kaen University Dental Journal* 2003;6: 1-7.
- Smith BJ. The value of the nose width as an esthetic guide in prosthodontics. *J Prosthet Dent* 1975;34:562-73.
- Bolender CL. The Try-in Appointment. In: Zarb GA, Bolender CL, (eds). *Prosthodontic treatment for edentulous patients: Complete dentures and implant-supported prostheses*. 12<sup>th</sup> ed. St. Louis: CV Mosby Co., 2004, p. 329-78.