

측두골 골절후 발생한 안면마비 환자의 안면신경감압술: 25명 환자들의 증례분석

한림대학교 동탄성심병원 신경외과학교실, ¹순천향대학교 부천병원 신경외과학교실

남한가위, 황형식, 문승명, 신일영, 신승훈, 정제훈¹

- Abstract -

Facial Nerve Decompression for Facial Nerve Palsy with Temporal Bone Fracture: Analysis of 25 Cases

Han Ga Wi Nam, M.D., Hyung Sik Hwang, M.D., Seung-Myung Moon, M.D.,
Il Young Shin, M.D., Seung Hun Sheen, M.D., Je Hoon Jeong, M.D.¹

Department of Neurosurgery, Dongtan Sacred Heart Hospital, College of Medicine, Hallym University, Hwaseong, Korea
¹Department of Neurosurgery, Bucheon Hospital, College of Medicine, Soonchunhyang University, Bucheon, Korea

Purpose: The aim of this study is to present a retrospective review of patients who had a sudden onset of facial palsy after trauma and who underwent facial nerve decompression.

Methods: The cases of 25 patients who had traumatic facial palsy were reviewed. Facial nerve function was graded according to the House-Brackmann grading scale. According to facial nerve decompression, patients were categorized into the surgical (decompression) group, with 7 patients in the early decompression subgroup and 2 patients in the late decompression subgroup, and the conservative group(16 patients).

Results: The facial nerve decompression group included 8 males and 1 female, aged 2 to 86 years old, with a mean age of 40.8. In early facial nerve decompression subgroup, facial palsy was H-B grade I to III in 6 cases (66.7%); H-B grade IV was observed in 1 case(11.1%). In late facial nerve decompression subgroup, 1 patient (11.1%) had no improvement, and the other patient(11.1%) improved to H-B grade III from H-B grade V. A comparison of patients who underwent surgery within 2 weeks to those who underwent surgery 2 weeks later did not show any significant difference in improvement of H-B grades ($p>0.05$). The conservative management group included 15 males and 1 female, aged 6 to 66 years old, with a mean age of 36. At the last follow up, 15 patients showed H-B grades of I to III(93.7%), and only 1 patient had an H-B grade of IV(6.3%).

Conclusion: Generally, we assume that early facial nerve decompression can lead to some recovery from traumatic facial palsy, but a prospective controlled study should and will be prepared to compare of conservative treatment to late decompression.

Key Words: Facial paralysis, Temporal bone, Facial nerve injuries, Decompression, Facial nerve

* Address for Correspondence : **Hyung Sik Hwang, M.D.**

Department of Neurosurgery, Dongtan Sacred Heart Hospital, College of Medicine, Hallym University,
40 Sukwoo-dong, Hwaseong, 445-170, Korea

Tel : 82-31-8086-2810, Fax : 82-31-8086-2809, E-mail : hyungsik99@hallym.or.kr

Submitted : August 13, 2013 **Revised** : August 24, 2013 **Accepted** : August 28, 2013

I. Introduction

Facial nerve palsy (FNP) after temporal bone fractures occurs in 7% to 10% of patients.(1,2) FNP that is associated with temporal bone fractures is classified into immediate palsy or delayed palsy, depending on the timing of the onset of the FNP after the head trauma.(2) When complete FNP occurs immediately after head trauma, surgical intervention is indicated. Conventionally, facial nerve decompression (FD) is considered for the following conditions: 1) severe or complete paralysis of House-Brackmann (H-B) grades of 4 to 6,(3) 2) immediate onset of FNP, and 3) degree of denervation exceeding 90% according to electroneuronography (ENoG).

Some studies have reported beneficial effects of late FD in patients who had facial paralysis caused by temporal bone fractures and who could not be operated on earlier.(4,5) Others have suggested that surgical decompression of the facial nerve is indicated at any time and may be beneficial, even in very old injuries.(6) However, most surgeons think that surgical intervention should be performed within 2 weeks of the onset of total FNP for it to be effective and favor surgical decompression as soon as electrical studies indicate severe injury and predict a poor prognosis.(7-10) Otherwise, a patient's unstable condition may complicate decisions about the optimal timing of surgical decompression. The best timing of FD remains controversial.(11,12)

The aim of this study was to report surgical results for patients with FNP after temporal bone fractures according to the timing of surgical exploration. We investigated the outcomes in facial function according to the location of the temporal bone fracture, the severity, and the type of injury.

II. Materials and Methods

The study design was a retrospective review of 25 patients who had FNP due to temporal bone fractures from because of head injury that occurred between 2003 and 2011. We determined patient age, and sex, type of temporal bone fracture, severity of FNP, type of operation, operation timing, follow-up period, and recovery of FNP. Evaluation of facial

nerve function was graded according to the H-B grading scale.(3) According to the FD performed, 25 patients were divided into the FD group or the conservative management group. The FD group consisted of 9 patients, and the conservative management group consisted of 16 patients. The FD group was subdivided into 2 groups according to early decompression(7 patients) or late decompression(2 patients, with late defined as the surgical decompression was conducted 2 weeks after the onset of FNP). Electromyography or ENoG, if possible, was conducted on the patients with facial paralysis. In total 12 patients (FD group, 6 patients; conservative management group, 6 patients) underwent electrophysiological assessments. For radiological evaluations, high-resolution computerized tomography was performed in all cases. Magnetic resonance imaging (MRI) was not routinely performed in this series but was performed in cases in which MRI was indicated. Thus, MRI played a complementary role in the diagnosis of concomitant intracranial complications.

The outcomes after the decompression surgery were also assessed with the H-B grading scale. In this study, an H-B grade of I was defined as complete recovery, and grades I-III with slight sequelae were defined as good recovery.

Statistical analyses were performed with the Statistical Package for the Social Sciences (SPSS) for Windows (version 18, IBM Corporation, Amonk, NY, USA). The improvement in H-B grades between the early FD group and the late FD group was analyzed with Crosstab. *p* values less than 0.05 were considered statistically significant.

III. Results

The FD group had 8 male and 1 female patients who were aged 2 to 86 years, with a mean age of 40.8 years. The mean operation time after the onset of FP was 15.6 days (ranging from 2 to 55 days). The mean follow-up period was 22 months (ranging from 2 months to 8 years). FP involved the left side in 4 cases and the right side in 5 cases. Seven patients had temporal bone fractures of the longitudinal type(77.7%), and 2 patients(22.3%) had tempo-

Table 1. The Demography of Facial Nerve Decompression Group

No.	Age	Sex	Fx Side	Fx Type	Etiology	Associated pathologies	Electrophysiological testing	Operation time (days after facial palsy)	Operation type	Operation finding	Initial H-B	Immediate Post operation H-B	Last Follow up H-B
1	30	M	R	LF	MVA	Rt. conductive HD	EnoG 100% degeneration	9	MCF	Fracture segment impinging+ Nerve swelling	4	2	2
2	31	M	R	LF	PTA	60 dB Rt. SNHL at 4000 Hz in the contralateral ear	ENoG 80.6% degeneration	11	MCF	Fracture segment impinging +Hematoma	3	4	3
3	26	M	L	TF	MVA	40 dB Lt. SNHL at 4000 Hz in the contralateral ear, AP	ENoG 79% degeneration	2	TM	Crordatympani cutting+M-I luxation+ Nerve swelling +Hematoma	3	3	2
4	61	M	L	TF	MVA	Lt. Tympanic membrane perforation	-	4	TM	Hematoma+ Nerve swelling	5	4	4
5	65	M	L	LF	MVA	Lt. conductive HD	ENoG 78.5% degeneration	9	MCF+TM	M-I subluxation +Granulation	5	5	1
6	38	M	R	LF	MVA	-	-	9	TM	M-S adhesion	5	4	3
7	29	M	R	LF	FD	-	ENoG 86.84% degeneration	5	TM	M-I dislocation +Hematoma	5	3	2
8	86	M	L	LF	VA	-	-	55	MCF+TM	M-I luxation+ Hematoma	4	5	5
9	2	F	R	LF	FD	-	-	36	TM	M-I subluxation +Granulation	4	4	3
Mean	40.8							15.6			4.2	3.8	2.8

R: right, L: left, MVA: motor vehicle accident, VA: vehicle accident, SD: slip down, PTA: pedestrian traffic accident, FD: fall down, LF: longitudinal fracture, TF: transverse fracture, SNHL: sensory neural hearing loss, HD: hearing disturbance, MCF: middle cranial fossa approach, TM: transmastoid approach, M-S: malleus-stapes, M-I: malleus-incus, I-S: incus-stapes

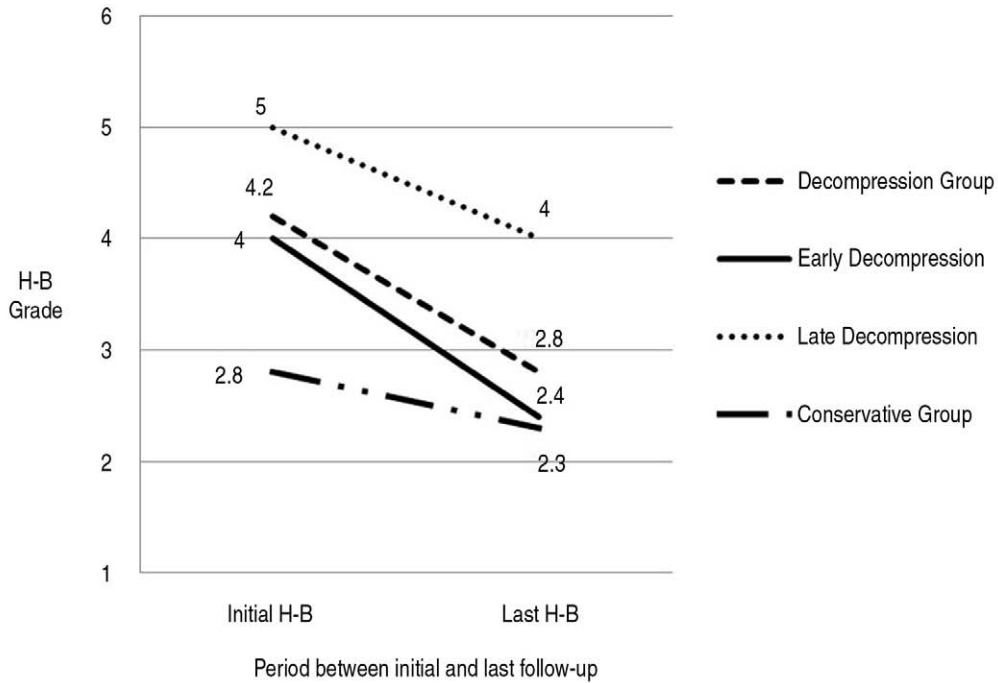


Fig. 1. Change of Mean H-B Grade Between Decompression Group and Conservative Group

Table 2. The Demography of Conservative Management Group

No.	Age	Sex	Fx Side	Fx Type	Etiology	Associated pathologies	Initial H-B	Electrophysiological testing	Last Follow up H-B
1	14	M	R	LF	VA	40 dB Lt. SNHL at 4000 Hz in the contralateral ear	3	—	3
2	22	M	R	LF	MVA	Rt. Conductive HD	3	—	3
3	41	M	R	LF	FD	AP	4	—	3
4	51	M	L	LF	FD	AP	2	—	2
5	49	M	R	LF	VA	Rt. Conductive HD	3	ENoG 23.1% degeneration	3
6	30	M	R	LF	VA	Rt. Conductive HD	2	—	2
7	65	M	R	LF	VA	Rt. Conductive HD	4	—	3
8	23	M	B	LF	TA	Both Conductive HD	2	ENoG 0% degeneration	2
9	19	M	L	LF	MVA	Both Conductive HD	2	ENoG 82.1% degeneration	2
10	66	F	R	LF	PTA	Rt. Conductive HD	2	—	2
11	53	M	R	LF	MVA	Rt. Conductive HD	2	ENoG 35.7% degeneration	2
12	6	M	R	TF	PTA	—	2	—	1
13	50	M	B	TF	MVA	Rt. Conductive HD	3	—	2
14	14	M	L	LF	MVA	Lt. Temporal Pseudo-aneurysm	4	—	4
15	45	M	L	LF	FD	Lt. Optic nerve injury	3	—	2
16	28	M	L	LF	FD	Lt. Conductive HD	3	ENoG 69.7% degeneration	1
Mean	36						2.8		2.3

R: right, L: left, MVA: motor vehicle accident, VA: vehicle accident, SD: slip down, PTA: pedestrian traffic accident, FD: fall down, LF: longitudinal fracture, TF: transverse fracture, AP: abducens palsy, SNHL: sensory neural hearing loss, HD: hearing disturbance

ral bone fractures of the transverse type. One case of sixth nerve palsy was evaluated. There were 6 road traffic accidents(66.7%), 2 falls(22.2%), and 1 vehicle accident(11.1%).

For the preoperative H-B grades of the FD group (9 patients), 2 patients were normal to moderate (grades I-III), 3 patients were moderately severe (grade IV), and 4 patients were poor (grades V-VI). The immediate postoperative H-B grades of 3 patients were normal to moderate (grades I-III), of 4 patients were moderately severe (grade IV), and of 2 patients were poor (grade V-VI). At the last follow up, facial nerve function was grade I to III in 7 cases. H-B grade IV was observed in 1 case(11.1%), and grade V was found in 1 case(11.1%). Grade VI was not found in any of the cases. The mean improvement in the H-B grade was a grade of 1.4. The rate of goof recovery was 85.7%(6 of 7 patients) if the surgery was performed within 2 weeks. Of the 2 patients who underwent FD after 2 weeks, 1 patient had no improvement, and the other patient had an improved H-B grade of III from grade V (Table 1) (Fig. 1).

The conservative management group included 15 males and 1 female who were aged 6 to 66 years old and with a mean age of 36. The mean follow-up period was 14.7 months (ranging from 2 months to 9 years). FNP involved the left side in 5 cases and the

right side in 11 cases. One case of a left temporal traumatic pseudoaneurysm was identified, and 2 cases of sixth nerve palsy were evaluated. Fourteen patients had temporal bone fractures of the longitudinal type(87.5%), and 2 patients(12.5%) had them of the transverse type. Eight FPs(50.0%) were caused by road traffic accidents, 4(25.0%) were due to falls, and 4(25.0%) were from vehicle accidents. For the initial H-B grades of the conservative management group, 13 patients were normal to moderate (grades I-III)(81.2%), 3 patients were moderately severe (grade IV)(18.8%), and no cases were poor (grades V-VI). At the last follow up, 15 patients had H-B grades of I to III(93.7%), and only 1 patient had an H-B grade of IV(6.3%). The mean improvement in the H-B grade was a grade of 0.6. The demographics of the conservative management group are shown in Table 2.

1. Facial nerve decompression

Of the 25 FP cases managed, 9 were surgically treated(36%), and 16 were medically treated(64%). For the 9 surgically treated patients, surgery was performed any time between 2 days and 55 days after the onset of FNP, depending on the severity of the patient's general condition and intracranial injury. Most patients were operated on within 2

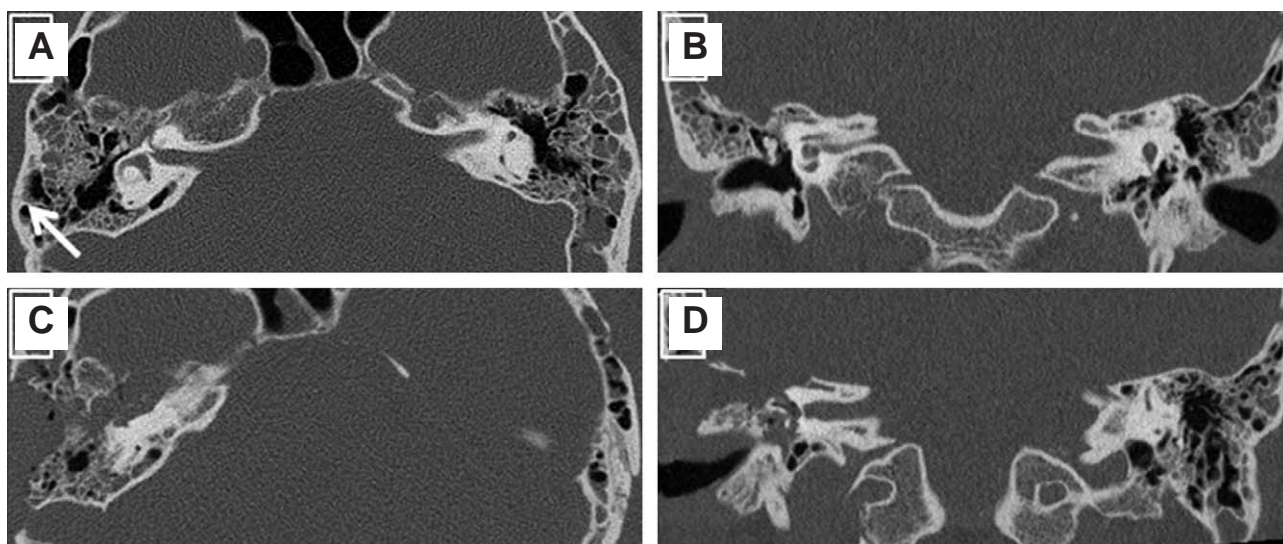


Fig. 2. Preoperative (A, B) and postoperative (C, D) HRCT images of patient no. 1, longitudinal fracture line (white arrow) of the temporal bone in axial view of the right temporal bone (A), Traumatic fluid collection of both mastoids and right middle ear cavity (B), Middle cranial fossa approach of axial view (C) and coronal view (D)

weeks (mean, 7 days; ranging from 2 to 11 days) after the onset of FNP(7 cases, 77.8%), and 2 patients (patients 8 and 9, 22.2%) underwent the decompression 2 weeks later (mean, 45.5 days; ranging from 36 to 55 days). Patients who underwent surgery within 2 weeks and those who underwent surgery 2 weeks later did not have any significant difference in improvement of H-B grades ($p>0.05$). A combined middle cranial fossa (MCF) and transmastoid (TM) approach was chosen in 2 cases (22.2%). A pure MCF route was used in 2 cases (22.2%) (Fig. 2). A pure TM route was used in 5 cases (55.6%) (Fig. 3). During the operation, it was observed that 5 cases had massive hematomas surrounding the facial nerve, 4 cases had malleus-incus subluxation, 3 cases had severe nerve swelling, 2 cases had granulation with the facial nerve, 2 cases had a fracture segment impinging on the facial nerve, 1 case had chorda tympani cutting, and 1 case had malleus-stapes subluxation.

IV. Discussion

There is still controversy concerning the efficacy, timing, and choice of approach in the management of traumatic FNP. First, Nash et al. reported the results of a systemic review of 612 patients and concluded that the efficacy of FD was debatable because

the rate of complete recovery was only 23% in the surgery group, whereas it was 66% in patients who were followed without treatment. Dorrouzet et al.(13) reported that, among their 115 patients, 65 patients received FD, and 94% of them recovered to H-B grades of I to III, 2 years later. They suggested that FD was effective. These different results may be explained by differences in the severity of the FNP between the patients receiving conservative therapy and those treated with FD. In our study, 7(77.7%) of the 9 patients who underwent FD recovered to H-B grades of I to III.

Second, FD has been shown to provides beneficial effects if it is performed within 14 days of injury. In addition, later FD should be done if the facial nerve function does not show any recovery in order to ascertain acute or delayed FP in an unconscious patient.(1) In many studies, it has been emphasized that early FD is more effective than late FD. Hato et al.(2) found that 14 of 66 patients who underwent FD within the first 2 weeks after trauma had an excellent therapeutic outcome with a rate of complete recovery of 85.7% and a rate of good recovery of 92.9%. However, recent studies have reported that late FD had sufficient effects for traumatic FNP. Lieberherr et al.(14) reported on 14 patients with acute FP, with more than 90% nerve degeneration shown on ENoG, 1 to 3 months following the

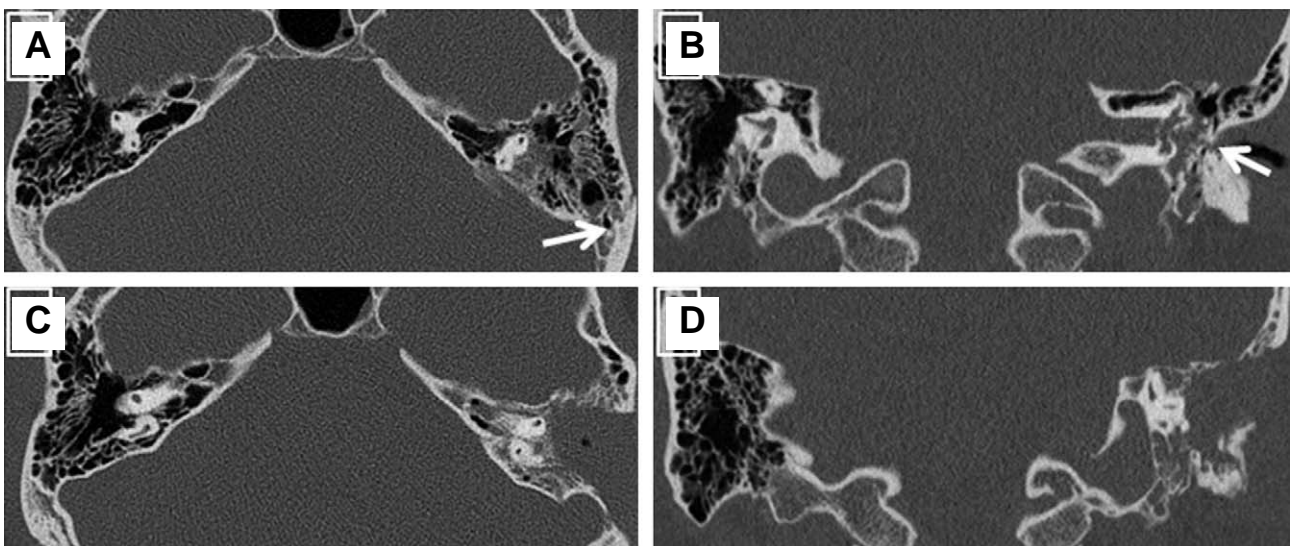


Fig. 3. Preoperative (A, B) and postoperative (C, D) HRCT images of patient no. 3, transverse fracture line (white arrow) of the temporal bone in axial view of the left temporal bone (A) and coronal view (B), Transmastoid approach of axial view (C) and coronal view (D)

trauma and found that 53~100% of the facial nerve function returned to normal. In addition, Quaranta et al.(5) found good recovery in patients who underwent FD even 3 months after the temporal bone fracture and with >95% denervation on ENoG. They found that 77.7% of the patients showed H-B grades of I or II recovery followed for at least 1 year. Ulug and Ulubil(15) reported that 11 patients with FNP after traumatic temporal bone fracture underwent FD within the first 3 months after the onset of paralysis. Five patients showed H-B grade of I, 4 patients had an H-B grade of II, and 2 patients had an H-B grade of III facial recovery.

In our study, the rate of good recovery was 85.7% (6 of 7 patients) if the surgery was performed within 2 weeks. This result supported the beneficial effects of early FD. Among the 2 patients who underwent FD after 2 weeks, 1 patient had no improvement, and the other patient had an improved H-B grade of III from a grade of V.

Third, the choice of the FD approach in traumatic FP considerably depends on the presence of serviceable hearing following the trauma and the types of temporal bone fractures. According to Fisch,(16) the facial nerve is injured distal to the geniculum in the majority of the cases with longitudinal fractures.

In general, for longitudinal fractures, the MCF approach is the preferred technique. For mixed and transverse fractures, when serviceable hearing is present, a middle fossa craniotomy combined with a TM exploration is used.(13,17,18) We used the MCF approach and combined it with TM exploration in 2 such affected patients, and total decompression of the facial nerve was achieved. A pure MCF approach was performed in 2 patients. We agree that the MCF approach is adequate for direct exposure of the internal auditory meatus and the cisternal, meatal, labyrinthine, and tympanic segments of the facial nerve, and, even more so, the perigeniculate area.

Last, when the FP is moderate and the patient's condition is unstable, medical treatment is considerable. In this study, 16 patients were treated with prednisolone for 2~3 weeks. At the last follow up, 15 patients had H-B grades of I to III(93.7%), and only 1 patient had an H-B grade of IV(6.3%). Thus, medical treatment was effective in moderate FP patients

and when some aspect of iatrogenic injury was considered during the decompression surgery.

A retrospective study to examine the usefulness of FD is a readily available method.(2,19) However, our study had some limitations. The 2 groups (FD group and conservative management group) had differences in their severity of facial paralysis, and there was a small number of patients. Therefore, further studies with prospective randomization, and a sufficient number of patients are needed.

V. Conclusion

We think that the early decompression for traumatic FP provides beneficial effects to patients. If the patients are delayed and have an unstable general condition, late surgery might be considered better when the patient's condition is stable. Medical treatment is effective in moderate FP patients, especially when considering with some aspect of iatrogenic injury during the decompression surgery. Finally, a prospective randomized and blinded study to examine the usefulness of FD is needed.

REFERENCES

- 1) Chang CY, Cass SP. Management of facial nerve injury due to temporal bone trauma. *Am J Otol.* 1999; 20(1): 96-114.
- 2) Hato N, Nota J, Hakuba N, Gyo K, Yanagihara N. Facial nerve decompression surgery in patients with temporal bone trauma: analysis of 66 cases. *J Trauma.* 2011; 71(6): 1789-92; discussion 92-3.
- 3) House JW, Brackmann DE. Facial nerve grading system. *Otolaryngol Head Neck Surg.* 1985; 93(2): 146-7.
- 4) Sanus GZ, Tanriover N, Tanriverdi T, Uzan M, Akar Z. Late decompression in patients with acute facial nerve paralysis after temporal bone fracture. *Turk Neurosurg.* 2007; 17(1): 7-12.
- 5) Quaranta A, Campobasso G, Piazza F, Quaranta N, Salonna I. Facial nerve paralysis in temporal bone fractures: outcomes after late decompression surgery. *Acta Otolaryngol.* 2001; 121(5): 652-5.
- 6) Brodsky L, Eviatar A, Daniller A. Post-traumatic facial nerve paralysis: three cases of delayed temporal bone exploration with recovery. *Laryngoscope.* 1983; 93(12): 1560-5.
- 7) Gantz BJ, Rubinstein JT, Gidley P, Woodworth GG. Surgical management of Bell's palsy. *Laryngoscope.* 1999; 109(8): 1177-88.
- 8) U F, editor. *Lacrimation in Facial Nerve Surgery.* Birmingham, AL; 1977.

- 9) May M. Total facial nerve exploration: transmastoid, extralabyrinthine, and subtemporal indications and results. *Laryngoscope*. 1979; 89(6 Pt 1): 906-17.
- 10) Kim J, Moon IS, Shim DB, Lee WS. The effect of surgical timing on functional outcomes of traumatic facial nerve paralysis. *The Journal of trauma*. 2010; 68(4): 924-9.
- 11) Adour KK, Boyajian JA, Kahn ZM, Schneider GS. Surgical and nonsurgical management of facial paralysis following closed head injury. *Laryngoscope*. 1977; 87(3): 380-90.
- 12) Yanagihara N. Transmastoid decompression of the facial nerve in temporal bone fracture. *Otolaryngol Head Neck Surg*. 1982; 90(5): 616-21.
- 13) Darrouzet V, Duclos JY, Liguoro D, Truilhe Y, De Bonfils C, Bebear JP. Management of facial paralysis resulting from temporal bone fractures: Our experience in 115 cases. *Otolaryngol Head Neck Surg*. 2001; 125(1): 77-84.
- 14) Lieberherr U SD, Fisch U. Management of severe facial nerve paralysis in the temporal bone-a review of 82 cases. In: Castro D, ed. *Proceedings of the Sixth International Symposium on the facial nerve*. 1990: 285-9.
- 15) Ulug T, Arif Ulubil S. Management of facial paralysis in temporal bone fractures: a prospective study analyzing 11 operated fractures. *Am J Otolaryngol*. 2005; 26(4): 230-8.
- 16) Fisch U. Management of intratemporal facial nerve injuries. *J Laryngol Otol*. 1980; 94(1): 129-34.
- 17) Angeli SI, Chiossone E. Surgical treatment of the facial nerve in facial paralysis. *Otolaryngol Clin North Am*. 1997; 30(5): 683-700.
- 18) U F. Facial paralysis in fractures of the petrous bone. *Laryngoscope*. 1974; 84: 2141-54.
- 19) Lathrop FD. Lesions of the Facial Nerve Due to War Injuries and Their Repair. *Proc R Soc Med*. 1945; 38(11): 629-34.