

## Case report

J Korean Soc Pediatr Nephrol 2013;17:132-136  
DOI: <http://dx.doi.org/10.3339/jkspn.2013.17.2.132>

ISSN 1226-5292 (print)  
ISSN 2234-4209 (online)

# Parainfluenza virus 감염 후 발생한 횡문근융해증과 isovaleric acidemia로 인한 고암모니아혈증을 가진 소아에서의 지속적 신대체요법

아주대학교 의과대학 소아청소년과학교실, 아주대병원 소아청소년과  
연세대학교 의과대학 소아과학교실, 세브란스 어린이병원 소아청소년과\*  
박세진·조수연·배기수·신재일\*

Se Jin Park, M.D., Ph.D.,  
Soo Yeon Cho, M.D.,  
Ki Soo Pai, M.D., Ph.D.,  
and Jae Il Shin, M.D., Ph.D.\*

Department of Pediatrics, Ajou University Hospital, Ajou University School of Medicine, Suwon, Korea  
Department of Pediatrics\*, Severance Children's Hospital, Yonsei University College of Medicine, Seoul, Korea

**Corresponding Author:** Jae Il Shin  
Department of Pediatrics, Severance Children's Hospital, Yonsei University College of Medicine, Seoul, Korea  
Tel: 02-2228-2050, Fax: 02-393-9118  
E-mail: [shinji@yuhs.ac](mailto:shinji@yuhs.ac)

Received: 14 September 2013  
Revised: 28 September 2013  
Accepted: 2 October 2013

This is an open-access article distributed under the terms of the Creative Commons Attribution Non-Commercial License (<http://creativecommons.org/licenses/by-nc/3.0/>) which permits unrestricted non-commercial use, distribution, and reproduction in any medium, provided the original work is properly cited.

## Continuous Renal Replacement Therapy in a 4-year-old Child with Rhabdomyolysis Following Parainfluenza Virus Infection and Hyperammonemia due to Isovaleric Acidemia

Parainfluenza virus infection is one of the causes of fatal rhabdomyolysis. Rhabdomyolysis can be aggravated by mitochondrial fatty acid  $\beta$ -oxidation disorders during prolonged periods of fasting. Moreover, in patients with late-onset isovaleric acidemia, hyperammonemia may occur following catabolic stress. In the present report, we describe a case of a 4-year-old boy with parainfluenza virus infection and late-onset isovaleric acidemia that rapidly progressed to coma, seizures, and cardiorespiratory collapse. His serum ammonia and creatinine kinase (CK) levels were 385  $\mu$ Mol/L and 23,707 IU/L, respectively. Continuous renal replacement therapy (CRRT) was initiated using continuous venovenous hemodiafiltration, after which the ammonia and CK levels returned to normal. Thus, we recommend the immediate initiation of CRRT in the management of patients with life-threatening rhabdomyolysis and hyperammonemia.

**Key words:** Rhabdomyolysis, Hyperammonemia, Parainfluenza virus, Isovaleric acidemia, Continuous renal replacement therapy

### Introduction

Rhabdomyolysis and hyperammonemia due to congenital metabolic disorders are often treated with hemodialysis (HD) [1]. However, conventional HD may be relatively ineffective in removing circulating myoglobin due to its large molecular weight. Continuous renal replacement therapy

(CRRT) has the advantage of removing relatively large molecules and abolishing rebound hyperkalemia and acidosis through continuous venovenous hemofiltration or hemodiafiltration. Theoretically, convection removes larger molecular-weight solutes better than diffusion [1].

Here, we report a case of rhabdomyolysis and hyperammonemia in a 4-year-old boy following parainfluenza virus infection and late-onset, transient isovaleric acidemia, which was treated successfully with CRRT.

## Case report

A 4-year-old boy was transferred to our emergency room due to a change in mental status. Four days before admission, he developed fever, vomiting, and diarrhea. Oral medication was administered at a local clinic, but vomiting and diarrhea continued 5 to 6 times a day. There was no specific perinatal or past medical history. He did not experience any trauma or drug intoxication.

On physical examination, the child was lethargic, stuporous, and severely dehydrated. He had a blood pressure of 100/48 mmHg, a pulse rate of 130/min, a body temperature of 37.5°C, and a respiratory rate of 42/min. His previous body weight of 19 kg had decreased to 18 kg. He did not show any meningeal signs such as Brudzinski or Kernig signs.

Initial laboratory findings revealed hypoglycemia (45 mg/dL, range 70–110), hyperammonemia (385  $\mu\text{Mol/L}$ , range 0.0–54), and rhabdomyolysis (creatinine kinase, 1,665 IU/L; range 30–180). Aspartate aminotransferase (AST, 133 IU/L; range 5–40), alanine aminotransferase (ALT, 129 IU/L; range 8–41), lactate dehydrogenase (LDH, 592 IU/L; range 100–200), and uric acid (12.0 mg/dL; range 2.0–5.5) levels were elevated. Prothrombin time was 13.6 seconds (INR 1.18) and activated partial thromboplastin time was 25 seconds. The electrolyte results were as follows: serum sodium of 148 mEq/L (range 135–145), potassium of 3.4 mEq/L (range 3.5–5.5), chloride of 114 mEq/L (range 98–107), and total carbon dioxide of 7 mEq/L (range 24–31), suggesting severe metabolic acidosis. Arterial blood gas analysis results were as follows: pH 7.285,  $\text{pCO}_2$  9.8 mmHg,  $\text{pO}_2$  85.4 mmHg,

base excess  $-18.6$  mEq/L, and  $\text{HCO}_3^-$  4.6 mEq/L. These results also indicated severe metabolic acidosis with respiratory compensation. The calculated anion gap [ $\text{Na}^+ - (\text{Cl}^- + \text{HCO}_3^-)$ ] was 27 mEq/L in ambient air. The specific gravity of his urine was elevated to  $\geq 1.035$ , and the urine was positive for ketone 3. Cerebrospinal fluid profiles were all within normal ranges and no organisms were isolated from blood, urine, or CSF cultures. However, parainfluenza virus was detected by polymerase chain reaction in nasopharyngeal specimens. With a high index of suspicion for organic acidemia, treatment with sodium phenylbutyrate, L-carnitine, lactulose enema, and 10% dextrose in water was begun.

On the third day of admission, laboratory testing revealed rapidly deteriorating rhabdomyolysis. Maximum creatinine kinase (CK) and CK-MB levels were 23,707 IU/L and 131, 3  $\mu\text{g/L}$  (range 0.0–5.0), respectively. Tandem mass spectrometry (MS/MS) showed an increase in isovalerylcarnitine [C5] (1,513  $\mu\text{M}$ , range 0.005–0.899), suggesting isovaleric acidemia, which requires a low protein and leucine diet. Increases in AST to 1,626 IU/L, ALT to 691 IU/L, LDH to 2,719 IU/L, uric acid to 10.6 mg/dL (range 2.0–5.5), myoglobin to 2,020 ng/mL (range 0.0–72), and the onset of acute kidney injury (creatinine, 1.0 mg/dL; range 0.3–0.6) indicated CRRT. CRRT was performed for 5 days, after which rhabdomyolysis and hyperammonemia subsided (Fig. 1).

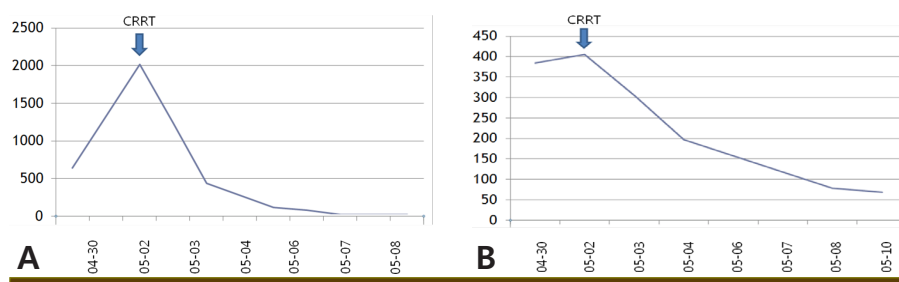
After 2 weeks, urinary aminoacid analysis showed high amounts of  $\beta$ -aminoisobutyric acid (3,103  $\mu\text{mol/g}$  creatinine), arginine (216  $\mu\text{mol/g}$  creatinine), cystathionine (44  $\mu\text{mol/g}$  creatinine), cystine (139  $\mu\text{mol/g}$  creatinine), and ethanolamine (1,837  $\mu\text{mol/g}$  creatinine). Tandem mass spectrometry analysis performed two months later revealed an increase in octanoylcarnitine [C8] (0.803  $\mu\text{M}$ , range 0.010–0.453) and decenoylcarnitine [C10:1] (0.438  $\mu\text{M}$ , range 0.005–0.233), suggesting medium-chain acyl-coenzyme dehydrogenase deficiency. However, the A985G and T199C mutations commonly associated with that deficiency had not been detected. He was discharged with puritan (vitamin B2) and L-carnitine syrup. He has been doing well over one year of follow-up and shows no evidence of recurrent rhabdomyolysis or hyperammonemia.

## Discussion

Rhabdomyolysis is a syndrome caused by various insults to skeletal muscle and results in the release of myoglobin into the plasma. Massive rhabdomyolysis accompanied by viral myositis and its consequences have been reported by several researchers [2]. In a retrospective series from a pediatric emergency room, 38% of rhabdomyolysis cases were found to have been caused by viral myositis [2]. Several viruses such as adeno, influenza A and B, coxsackie, Epstein-Barr, echo, and measles have been implicated in the pathogenesis of rhabdomyolysis [3]. Parainfluenza virus is known to be one of the causative viruses for complicated rhabdomyolysis. To our knowledge, only 6 cases of rhabdomyolysis induced by parainfluenza virus infection in adolescents and children have been reported in the literature: 3 were attributed to parainfluenza type 1 [4-6], 2 to parainfluenza type 2 [7,

8], and 1 fatal case was attributed to type 3 [9] (Table 1). While rhabdomyolysis is rare, it is a life-threatening complication of viral myositis. We believe that the most probable cause of rhabdomyolysis in our patient was from a parainfluenza virus infection aggravated by coexistent isovaleric acidemia, which caused severe metabolic acidosis and hyperammonemia, finally resulting in acute kidney injury. CRRT is able to remove myoglobin from the blood in spite of its large molecular weight, thus aborting rebound hyperkalemia and acidosis. Consequently, virus-induced fatal rhabdomyolysis can be effectively treated by CRRT, resulting in successful clinical outcomes [10].

Isovaleric acidemia, a type of organic acidemia, is an autosomal recessive congenital defect in leucine metabolism caused by deficiency of isovaleryl-CoA dehydrogenase, a mitochondrial enzyme [11]. Most organic acidemias become clinically apparent during shortly after birth or in early infancy. However, there is another phenotype



**Fig. 1.** Changes in serum myoglobin (A) and ammonia (B) levels. Continuous renal replacement therapy effectively decreased both increased serum myoglobin and ammonia levels to normal range.

**Table 1.** Summary of Previously Reported Patients with Parainfluenza-induced Rhabdomyolysis

	Authors	Age/sex	Virus species	Clinical symptoms	CK	AST	LDH	Serum myoglobin	Serum anion gap	Treatment	Prognosis
Case 1	Pana et al (4) (2011)	10 yr/M	Parainfluenza type 1	Muscle weakness	7,563 U/L	71 U/L	617 U/L	NA	NA	Oral fluid intake	good
Case 2	Ebbeson et al (6) (2009)	6 yr/F	Parainfluenza type 1	Fever, malaise, sore throat	>50,000 IU/L	156 IU/L	NA	NA	9 mEq/L	hemodialysis	good
Case 3	Vrsalovic (5) (2007)	5 yr/M	Parainfluenza type 1	Rhinorrhea, vomiting, spastic quadriplegia	22,242 IU/L	1,040 IU/L	2,995 IU/L	NA	NA	CRRT	good
Case 4	Zvolanek (7) (1984)	8 yr/M	Parainfluenza type 2	Fever, headache, Vomiting	4,060 IU/L	204 IU/L	NA	NA	NA	Conservative Tx	good
Case 5	O'Connor et al (8) (1982)	38 yr/M	Parainfluenza type 2	Dark urine	66,000 mU/dL	1,200 mU/dL	4,500 mU/dL	NA	NA	hydration	good
Case 6	Ueda et al (9) (1978)	4 yr/M	Parainfluenza type 3	Rhinorrhea, cough	1,700 IU	392 mU/mL	1,032 mU/mL	NA	NA	Aspirin	fatal
Case 7 (present study)	Park et al (2011)	4 yr/M	Parainfluenza (No type)	Fever, vomiting, diarrhea	23,707 IU/L	1,626 IU/L	2,719 IU/L	2,020 ng/mL	27 mEq/L	CRRT	fatal → good

Abbreviations: NA, not available; CK, creatinine kinase; AST, Aspartate aminotransferase; LDH, lactate dehydrogenase

similar to that seen in our case that presents after an initial period of good health in which the patient develops a life-threatening episode of metabolic acidosis characterized by an increased anion gap [12]. This late-onset organic acidemia is difficult to detect. Children with organic acidemia are susceptible to metabolic decompensation during acute episodes of increased catabolism such as intercurrent illness, trauma, surgery, or prolonged episodes of fasting. First-line diagnosis of organic acidemia is by organic acid urine analysis. However, tandem mass spectrometry (MS/MS), which is used in newborn screening, is also helpful in establishing a prompt diagnosis in some unexpected late-onset metabolic crises following catabolic stress [13]. In our patient, catabolic stress due to upper respiratory infection by parainfluenza virus infection, vomiting, diarrhea, and poor oral intake induced the presentation with transient isovaleric acidemia and hyperammonemia and rapidly aggravated the clinical course of rhabdomyolysis. Excessive ammonemia, which occurs in organic acidemia, should be treated early with hemodialysis and medication such as N-carbamylglutamate [10]. CRRT has proved effective in many studies for treating hyperammonemia complicated by congenital metabolic defect [14-16].

In conclusion, this case highlights the significance of maintaining a high index of suspicion for viral infection in children with rhabdomyolysis and emphasizes the role of CRRT in the management of fatal rhabdomyolysis and hyperammonemia in children who have parainfluenza virus infection and coexistent isovaleric acidemia.

## 국문요약

Parainfluenza virus 감염은 횡문근융해증의 하나의 원인이 될 수 있다. 횡문근융해증은 지속된 금식기간동안 미토콘드리아 지방산  $\beta$ -oxidation 장애에 의해 악화될 수 있다. 또한 후기 발생 isovaleric 산증을 가진 환아들에게서 고암모니아혈증이 이화작용을 일으키는 상태 후 발생할 수 있다. 본 케이스는 parainfluenza virus 감염과 후기 발생 isovaleric 산증을 가진 4세 남아가 혼수, 경련 및 심호흡 부전으로 빠르게 진행했던 경우이다. 초기 암모니아와 creatinine kinase는 각각  $385 \mu\text{Mol/L}$ 과  $23,707 \text{ IU/L}$  이

었으나 지속적 신대체요법 시행 후 암모니아와 creatinine kinase 수치는 정상으로 돌아왔다. 그러므로 생명을 위협하는 횡문근융해증과 고암모니아혈증을 가진 환아들의 치료에 있어서 즉각적인 지속적 신대체요법의 사용을 권하는 바이다.

## Conflict of Interest

The authors declare no potential conflicts of interest with respect to the research, authorship, and/or publication of this article, and no funding.

## References

- 1) Cruz DN, Bagshaw SM. Does continuous renal replacement therapy have a role in the treatment of rhabdomyolysis complicated by acute kidney injury? *Semin Dial* 2011;24:417-20.
- 2) Mannix R, Tan ML, Wright R, Baskin M. Acute pediatric rhabdomyolysis: causes and rates of renal failure. *Pediatrics* 2006; 118:2119-25.
- 3) Seibold S, Merkel F, Weber M, Marx M. Rhabdomyolysis and acute renal failure in an adult with measles virus infection. *Nephrol Dial Transplant* 1998;13:1829-31.
- 4) Pana ZD, Traqiannidis A, Douma S, Chrisa K. Rhabdomyolysis in an adolescent associated with parainfluenza type 1 virus. *Pediatr Infect Dis J* 2011;30:450.
- 5) Vrsalovic R, Tesovic G, Mise B. Rhabdomyolysis and acute renal failure in a child with para-influenza type 1 infection. *Pediatr Nephrol* 2007;22:1369-71.
- 6) Ebbeson RL, De Kock MJ, Penny N, Kollman TR. Rhabdomyolysis, acute renal failure, and compartment syndrome in a child with parainfluenza type 1 infection. *Pediatr Infect Dis J* 2009;28:850-2.
- 7) Zvolanek JR. Benign acute childhood myositis associated with parainfluenza type 2 infection. *Pediatr Infect Dis* 1984; 3:594-5.
- 8) O'Connor JV, Iyer SK. Myoglobinuria associated with parainfluenza type 2 infection. *N Y State J Med* 1982;82:1469-70.
- 9) Ueda K, Robbins DA, Iitaka K, Linnemann CC Jr. Fatal rhabdomyolysis associated with parainfluenza type 3 infection. *Hiroshima J Med Sci* 1978;27:99-103.
- 10) Sloboqean BL, Reilly CW, Alvarez CM. Recurrent viral induced compartment syndrome. *Pediatr Emerg Care* 2011;27:660-2.
- 11) Kasapkara CS, Ezgu FS, Okur I, Tumer L, Biberoglu G, Hasanoglu A. N-carbamylglutamate treatment for acute neonatal

- hyperammonemia in isovaleric acidemia. *Eur J Pediatr* 2011; 170:799-801.
- 12) Vockley J, Ensenauer R. Isovalericacidemia: new aspects of genetic and phenotypic heterogeneity. *Am J Med Genet C Semin Med Genet* 2006;142C:95-103.
- 13) Plochl E, Plochl W, Wermuth B, Roscher AA. Variants of inborn errors of metabolism with late onset but nevertheless life threatening course. *KlinPadiatr* 2001;213:261-5.
- 14) Kim HJ, Park SJ, Park KI, Lee JS, Eun HS, Kim JH, et al. Acute treatment of hyperammonemia by continuous renal replacement therapy in a newborn patient with ornithine transcarbamylase deficiency. *Korean J Pediatr* 2011;54:425-8.
- 15) Schaefer F, Straube E, Oh J, Mehls O, Mayatepek E. Dialysis in neonates with inborn errors of metabolism. *Nephrol Dial Transplant* 1999;14:910-8.
- 16) Ponikvar R, Kandus A, Urbancic A, Kornhauser AG, Primozic J, Ponikvar JB. Continuous renal replacement therapy and plasma exchange in newborns and infants. *Artif Organs* 2002; 26:163-8.