

Surgical Treatment for an Invasive Leiomyosarcoma of the Inferior Vena Cava

Hee Moon Lee, M.D., Dong Seop Jeong, M.D., Ph.D., Pyo Won Park, M.D.,
Wook Sung Kim, M.D., Kiick Sung, M.D., Young Tak Lee, M.D.

A 49-year-old woman presented with right lumbar pain and edema in both legs. Computed tomography showed a large low attenuated mass around and in the S7 segment of the liver involving the right kidney and multiple enlarged mesenteric lymph nodes. There were multiple variably sized discrete nodules in both lungs. Cavography showed subtotal occlusion of the inferior vena cava (IVC). She was successfully treated by wide resection and IVC reconstruction with partial cardiopulmonary bypass and metastasectomy.

Key words: 1. Leiomyosarcoma
2. Inferior vena cava
3. Multiple metastasis

CASE REPORT

A 49-year-old woman was admitted with right lumbar pain and edema of both legs. At admission, she was not very ill looking and had experienced no weight loss. Abdominal computed tomography (CT) showed a large low attenuated mass around and in the S7 segment of the liver: the mass measured 9×12 cm, and it involved the right kidney (Fig. 1). In addition, there were multiple enlarged mesenteric lymph nodes and multiple variably sized discrete nodules in both lungs (Fig. 1). Cavography showed subtotal occlusion of the inferior vena cava (Fig. 2). During cavography, intracaval biopsy was performed and spindle cell sarcoma was found.

An operation was performed via midline laparotomy with subcostal extension. Before beginning to resect the tumor, we checked the lymph nodes and the rectal shelf and omental seedings. All were negative on frozen biopsy. During dis-

section around the tumor, partial bypass (femoro-femoral) was inevitable due to massive bleeding of collateral vessels. Through the right femoral artery and vein, arterial and venous cannulation was done. The pump flow was 3 L/min and the total bypass time was 30 minutes. During en bloc resection of the mass from the hepatic vein to the iliac bifurcation, partial duodenal excision, partial liver resection, and right nephrectomy were performed due to tumor invasion.

The left renal vein was clamped for one hour because we had confirmed good drainage of the gonad vein. After resection, the IVC was replaced with a 12-mm vascular graft, and the left renal vein was re-implanted in the vascular graft. The gross findings are shown in Fig. 3. Histological analysis revealed a moderate grade malignant spindle cell tumor that arose in the IVC with intraluminal spread into the vena cava and the right renal vein. No lymph node involvement was found. The tumor border had infiltrated to the renal paren-

Department of Thoracic and Cardiovascular Surgery, Samsung Medical Center, Sungkyunkwan University School of Medicine

Received: April 15, 2013, Revised: May 12, 2013, Accepted: May 20, 2013

Corresponding author: Dong Seop Jeong, Department of Thoracic and Cardiovascular Surgery, Samsung Medical Center, Sungkyunkwan University School of Medicine, 81 Irwon-ro, Gangnam-gu, Seoul 135-710, Korea
(Tel) 82-2-3410-1278 (Fax) 82-2-3410-0089 (E-mail) cabg@korea.com

© The Korean Society for Thoracic and Cardiovascular Surgery. 2013. All right reserved.

© This is an open access article distributed under the terms of the Creative Commons Attribution Non-Commercial License (<http://creativecommons.org/licenses/by-nc/3.0>) which permits unrestricted non-commercial use, distribution, and reproduction in any medium, provided the original work is properly cited.

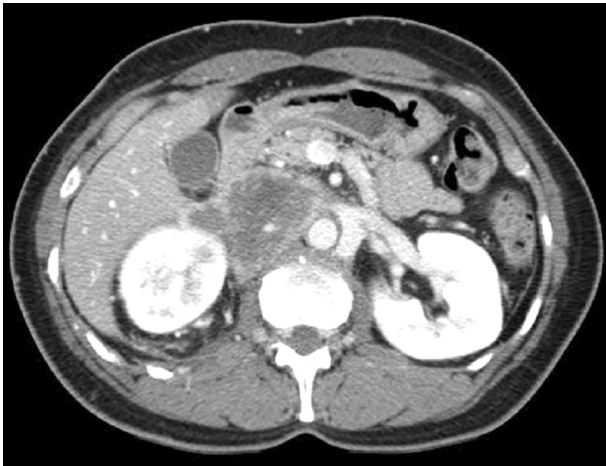

Fig. 1. The abdominal computed tomography scan shows an intracaval leiomyosarcoma infiltrating the right kidney and liver.

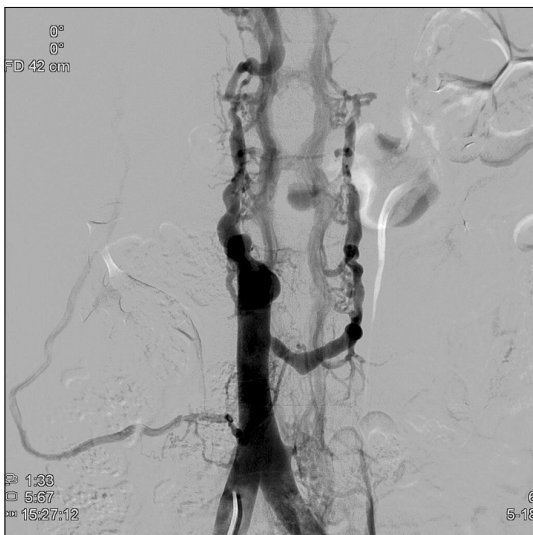


Fig. 2. The Cavography for the inferior vena cava (IVC) leiomyosarcoma: note the subtotal occlusion of the IVC.

chyma, the adrenal gland, and the IVC, but the resection margins were clear. The patient's postoperative recovery was uneventful except for minor gastrointestinal troubles and the patient was discharged at the 24th day. The patient remained asymptomatic for 8 months when she was readmitted for radiation therapy and pulmonary metastasectomy. At this time, the vascular graft in the IVC was occluded on the CT angiography, but she did not complain of any symptoms such as leg edema or abdominal discomfort. Periodic follow-up is

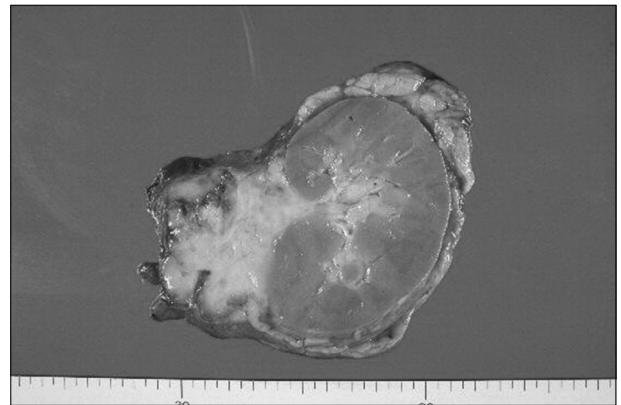


Fig. 3. The gross findings of the IVC leiomyosarcoma that infiltrated the right kidney.

being conducted at the department of oncology.

DISCUSSION

Leiomyosarcomas of the inferior vena cava (IVC) are rare tumors that most commonly arise as a primary malignancy of the IVC. In spite of its poor prognosis, surgical resection and additional chemoradiation are recommended to promote survival [1,2]. However, performing an operation for a patient with multiple metastases is still challenging and the necessity of IVC reconstruction remains in question. We present here a case of a patient with leiomyosarcoma of the IVC with multiple metastases, and this was treated by wide resection and IVC reconstruction with partial cardiopulmonary bypass and metastasectomy.

Leiomyosarcoma of the inferior vena cava was first reported in the German literature by Perl and Virchow in 1871 [3], more than 400 cases since then have been reported in the literature [4]. Although only 2% of leiomyosarcomas are vascular in origin, tumors of the IVC account for at least half the cases. Females were affected in about 80% of the cases with a mean age of 54 years.

This tumor commonly shows vague abdominal symptoms, including pain, anorexia, and vomiting, but it may also present with more obvious signs such as an abdominal mass, lower extremity edema, or deep vein thrombosis caused by IVC occlusion. A tumor arising above the hepatic vein causes acute Budd-Chiari syndrome [5]. Making the perioperative

diagnosis is usually difficult. In the literature, the diagnosis of about two thirds of these patients was confirmed only after laparotomy [6]. CT and magnetic resonance imaging (MRI) can confirm the existence of this tumor. Positron emission tomography has recently enabled defining the extent of the tumor, and this can aid in choosing the proper treatment approach [7]. In our case, CT revealed the existence of the tumor and the local extent of tumor spread.

There has been controversy about the indications for surgery [8,9]. Radical surgical resection with a tumor-free margin is generally recommended. Debulking surgery could be performed for palliation [10]. Our patient had hepatic and pulmonary metastases. Left renal vein invasion and caudate lobe invasion were suspected. To obtain the IVC resection margin, the liver should be elevated and massive bleeding should be suspected. For our case, an operation was thought to be impossible for prolonging the patient's life, but we hoped to relieve the symptoms. We additionally performed radical tumor resection and metastasectomy for the metastatic lung nodules. The patient was relatively young and was generally in good condition, and no definite invasion was identified on the MRI scan. Surgery is the only effective method for treating these patients.

Kieffer et al. [2] reported on a patient who underwent an operation with cardiopulmonary bypass and hypothermic circulatory arrest, but the patient could not be weaned from cardiopulmonary bypass. Our patient underwent an operation with partial bypass because of massive bleeding and she was successfully weaned. Due to the concern about cancer cell seeding, using a cardiotomy sucker is usually thought to be contraindicated for a cancer operation. In our case, a cardiotomy sucker was used only during dissection.

Some authors have reported that it is not necessary to reconstruct the IVC because of collateral vessels (the capsular, genital, and reno-azygo-lumbar veins), but caval reconstruction and preserving vascular continuity should generally be considered after tumor resection [11]. A polytetrafluoroethylene ring-reinforced graft is commonly used for replacement of the IVC although other prostheses have been described, such as a spiral saphenous vein graft, Teflon, Dacron, and bovine pericardium [12-14]. The ideal prosthetic material has not been defined due to the small number of

cases. A vascular graft was used for our patient. After 1 month, the graft was near totally obstructed. No symptoms associated with IVC obstruction were identified because of the slow progression of the graft occlusion.

The overall prognosis for a patient with leiomyosarcoma of the IVC is poor. With radical resection, the 5- and 10-year survival rates were 49.4% and 29.5%, respectively [8]. However, the cancer-free actuarial survival rates at 5 and 10 years were 31.4% and 7.4%, respectively [2]. This tumor metastasizes late in the course of the disease, and it often recurs locally. The local recurrence rate for leiomyosarcoma of the IVC is 10%. Radiotherapy may improve the local recurrence rates and survival. Metastases are initially spread hematogenously and then subsequently through the lymphatics. Metastatic disease can involve the liver, lung, lymph nodes, and/or bone. However, metastases have been reported in 32.5% of the cases [6]. In our case, there were lung metastases, and all of them were at a resectable location.

In conclusion, IVC leiomyosarcoma is a rare lesion that develops symptoms depending to its size and location. Surgical treatment is still challenging due to its invasiveness and poor prognosis, and to date, the ideal material for reconstruction of the IVC is controversial. Unfortunately, the vascular graft in our case was obstructed without symptoms. We report here on successful radical resection of an IVC leiomyosarcoma following radiation therapy and metastasectomy.

CONFLICT OF INTEREST

No potential conflict of interest relevant to this article was reported.

REFERENCES

1. Abisi S, Morris-Stiff GJ, Scott-Coombes D, Williams IM, Douglas-Jones AG, Puntis MC. *Leiomyosarcoma of the inferior vena cava: clinical experience with four cases*. World J Surg Oncol 2006;4:1.
2. Kieffer E, Alaoui M, Piette JC, Cacoub P, Chiche L. *Leiomyosarcoma of the inferior vena cava: experience in 22 cases*. Ann Surg 2006;244:289-95.
3. Perl L, Virchow R. *Ein fall von sarkom der vena cava*

- inferior*. Virchows Arch Pathol Anat 1871;53:378-83.
4. Mingoli A, Sapienza P, Brachini G, Tarantino B, Cirillo B. *Surgical treatment of inferior vena cava leiomyosarcoma*. J Am Coll Surg 2010;211:145-6.
 5. Griffin AS, Sterchi JM. *Primary leiomyosarcoma of the inferior vena cava: a case report and review of the literature*. J Surg Oncol 1987;34:53-60.
 6. Kulaylat MN, Karakousis CP, Doerr RJ, Karamanoukian HL, O'Brien J, Peer R. *Leiomyosarcoma of the inferior vena cava: a clinicopathologic review and report of three cases*. J Surg Oncol 1997;65:205-17.
 7. Reddy VP, Vanveldhuizen PJ, Muehlebach GF, et al. *Leiomyosarcoma of the inferior vena cava: a case report and review of the literature*. Cases J 2010;3:71.
 8. Mingoli A, Cavallaro A, Sapienza P, Di Marzo L, Feldhaus RJ, Cavallari N. *International registry of inferior vena cava leiomyosarcoma: analysis of a world series on 218 patients*. Anticancer Res 1996;16:3201-5.
 9. Hollenbeck ST, Grobmyer SR, Kent KC, Brennan MF. *Surgical treatment and outcomes of patients with primary inferior vena cava leiomyosarcoma*. J Am Coll Surg 2003; 197:575-9.
 10. Mingoli A, Feldhaus RJ, Cavallaro A, Stipa S. *Leiomyosarcoma of the inferior vena cava: analysis and search of world literature on 141 patients and report of three new cases*. J Vasc Surg 1991;14:688-99.
 11. Zheng W, Song S, Jiang Y, Liang F, Li R. *Leiomyosarcoma of inferior vena cava: report of 7 cases and literature review*. Chinese-German J Clin Oncol 2004;3:60-1.
 12. Bower TC, Nagorney DM, Cherry KJ Jr, et al. *Replacement of the inferior vena cava for malignancy: an update*. J Vasc Surg 2000;31:270-81.
 13. Mondragon-Sanchez R, Orellana H, Bernal-Maldonado R, Ruiz-Molina JM. *Resection of tumors of the pararenal inferior vena cava with in situ perfusion of the right kidney and graft replacement with bovine pericardium*. J Am Coll Surg 1998;186:717-9.
 14. Sarkar R, Eilber FR, Gelabert HA, Quinones-Baldrich WJ. *Prosthetic replacement of the inferior vena cava for malignancy*. J Vasc Surg 1998;28:75-81.