

비골골절 치료 시 간접 관혈적 정복술 및 외고정술의 유용성

박기린 · 정규진 · 김용하

영남대학교 의과대학 성형외과학교실

Usefulness of Indirect Open Reduction and External Fixation in Algorithm Oriented Treatment of Nasal Fracture

Ki Rin Park, Kyu-Jin Chung, Yong-Ha Kim

Department of Plastic and Reconstructive Surgery, Yeungnam University College of Medicine, Daegu, Korea

Background: To suggest the need of more aggressive reduction techniques than closed reduction (CR) technique in nasal fracture treatment, we identified the usefulness of algorithm oriented treatment of nasal fracture that includes indirect open reduction (IOR) and external fixation (EF) as well as the CR.

Methods: We compared the clinical course of the group A (n=128) where only the CR was performed regardless of the pattern of the nasal fracture and the group B (n=127) where algorithm oriented treatment including IOR and EF as well as CR was performed depending on the pattern of nasal fracture. And the degree of postoperative pain after CR and IOR technique was compared through the dose of analgesics and pain scores.

Results: More than 80% of patients were satisfied the result of reduction in both group A and B. Good contour of nasal bone after reduction was showed 71% of group A and 81% of group B without significant difference. Minor ($p>0.05$) and major ($p<0.05$) deformity after reduction were less occurred in the group B than group A. Postoperatively, the dose of analgesics was significantly lower after IOR technique than CR technique (53 mg vs. 142 mg) ($p<0.05$).

Conclusion: Algorithm oriented treatment of nasal fracture including IOR and EF as well as CR reduce major deformity after reduction than treatment of CR alone. It is useful to perform the more aggressive reduction techniques such as IOR and EF according to the pattern of fracture in treatment of nasal fracture.

Keywords: Nasal bone / Fractures / Injuries

Introduction

The nasal fracture is the most common type of facial fracture, and it displays various patterns of the fracture. The nasal fracture is generally considered a minor injury [1]. Therefore most of the nasal

fractures have been simply treated with closed reduction (CR).

Because the bone fragments are not within the visual field in the CR, appropriate reduction could not be achievable if the bone fragments are severely overlapped or displaced. As a result, the postoperative nasal deformity occurs at a maximum incidence of 14% to 50% [2]. Nasal deformity is not easy to correct and lead to poor treatment outcomes. Therefore, the prevention of nasal deformity would be essential for the treatment of nasal fracture [3].

To overcome the limitations of the CR, some authors have attempted aggressive surgical techniques such as septorhinoplasty,

Correspondence: Yong-Ha Kim

Department of Plastic and Reconstructive Surgery, Yeungnam University College of Medicine, 170 Hyeonchung-ro, Nam-gu, Daegu 705-717, Korea
Tel: +82-53-620-3481 / Fax: +82-53-626-0705 /
E-mail: yhkim@med.yu.ac.kr

Received July 20, 2013 / Revised September 14, 2013 / Accepted September 30, 2013

indirect open reduction (IOR), external fixation (EF) using a plate, intranasal K-wire splinting and et al. [2,4,5]. However, if these aggressive reduction techniques were used regardless of the severity of fractures, it could cause overtreatment of the patients in the perspectives of operative extent, time and cost. Therefore, to be the optimal treatment of the nasal fracture, it would be mandatory to determine the reduction technique of nasal fracture according to the pattern of fracture in each individual case.

The objectives of this study are to suggest the need of more aggressive reduction techniques than CR in the treatment of nasal fracture. And we identified the usefulness of algorithm oriented treatment of nasal fracture that includes IOR and EF as well as CR.

Materials and Methods

1. Patients and treatment algorithm

In the current study, we performed a retrospective chart review in 255 patients who were diagnosed with nasal fracture and underwent reduction during a period ranging from January of 2011 to June of 2012. The patterns of nasal fractures were classified by the Stranc's classification system [6]. According to the direction of the energy, it was classified into the fracture from frontal and lateral impact. According to the severity of the fracture, it was classified

into plane I, II, III and the comminuted fracture. We divided patients into two groups. The group A comprises 128 patients who were treated with CR alone. The group B comprises 127 patients who were treated according to the algorithm including IOR and EF as well as CR. In this group, surgical technique was determined depending on the pattern of the nasal fracture: frontal impacted plane I fracture was treated with CR. Frontal impacted plane II and lateral impacted plane I, II fractures were treated with the IOR. In cases of comminuted fracture regardless of direction of the energy, EF was done following CR (Fig. 1).

2. Surgical technique

All the surgical procedures were performed under general anesthesia. For local anesthesia, nasal packing was done using Bosmin (1 mg/mL epinephrine solution, Je Il Pharm., Seoul, Korea) gauze for ten minutes.

1) Closed reduction

The Asch forceps were placed below the bone pyramid which was displaced posteriorly and then elevated anteriorly. Synchronously, using the tactile sensation of the thumb and the index finger, the bone fragments were repositioned to the original location. Following the reduction, to support the bone fragments, Meroce

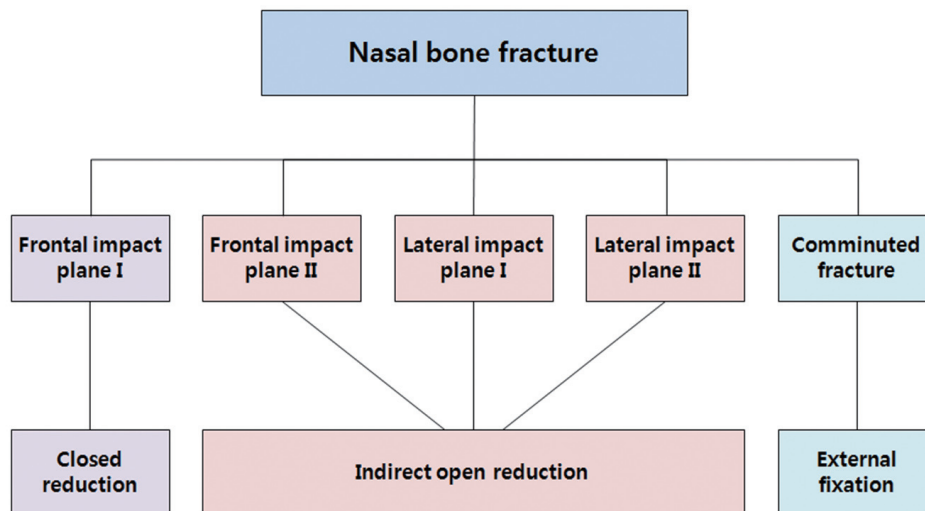


Fig. 1. The algorithm for nasal fracture management.

was packed in the superior meatus and Doyle Combo Splints was packed in the middle meatus, both of which were removed on postoperative day 5.

2) Indirect open reduction

Following a local infiltration in the nasal mucosa, an intercartilaginous incision was made at an approximate length of 5 mm. Using metzenbaum scissors and a periosteal elevator, the dissection was done up to the caudal border of the fractured bone segment on the supracartilaginous plane, preserving the attachment of the periosteum anterior to the nasal bone and of the mucoperiosteum posterior of the unfractured nasal bone. A nasal elevator was placed between the nasal bone and the mucosa. With the tactile sense of the bone fragments and the fracture line from an elevator tip, the bone fragments were reduced to the original position (Fig. 2). Synchronously, using the tactile sensation of the thumb and the index finger, the protruded bone fragments were repositioned to the original location. Using Vicryl 5-0, the sites of intercartilaginous inci-

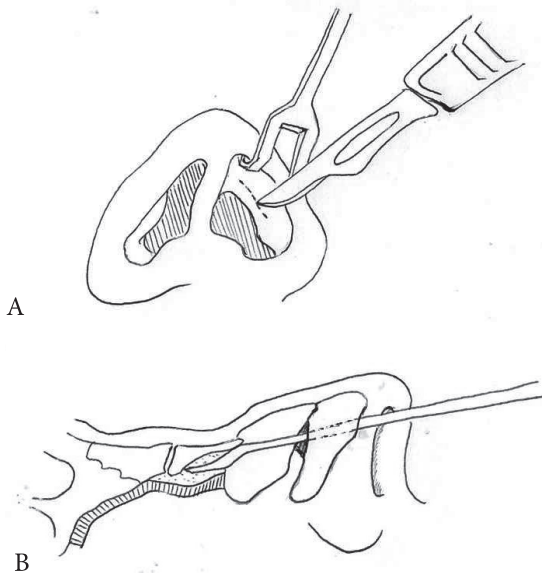


Fig. 2. Surgical technique of indirect open reduction through intercartilaginous incisional approach. (A) An intercartilaginous incision was made at an approximate length of 5 mm. (B) Using metzenbaum scissors and a periosteal elevator, the dissection was done up to the caudal border of the fractured bone segment on the supracartilaginous plane. A nasal elevator was placed between the nasal bone and the mucosa. With the tactile sense of the bone fragments and the fracture line from an elevator tip, the bone fragments were reduced to the original position.

sion were sutured. The internal packing was done in the same manner as the CR.

3) External fixation

The comminuted bone fragments were disimpacted and then re-aligned using Asch forceps. Synchronously, using the tactile sensation of the thumb and the index finger, the protruded bone fragments were repositioned to the original location. An external fixation device, composed of silastic sheets and nelaton tube, was placed in the bilateral sides of the nasal pyramid. Under the guidance of a hand-drilled, threaded K-wire, two 18-gauge needles were horizontally inserted in the nasal pyramid. The superior needle was passed through the comminuted bone fragments anteriorly and inferiorly to the medial canthus. The inferior needle was passed through the frontal process of maxillary bone. A 26-gauge stainless-steel wire was inserted through a needle. We performed a wiring by exerting a light pressure to such an extent as to maintain the symmetry and projection of the nasal bone (Fig. 3). Wire was removed on postoperative day 5.

3. Assessment methods

1) Distribution of fracture patterns

To make an objective comparison of the treatment outcomes between group A and group B, we evaluated the pattern of nasal fracture based on the Stranc's classification in both groups. We excluded any patients with plane III fracture (naso-ethmoid-orbital [NEO] fracture) or a preexisting nasal deformity from the current analysis.

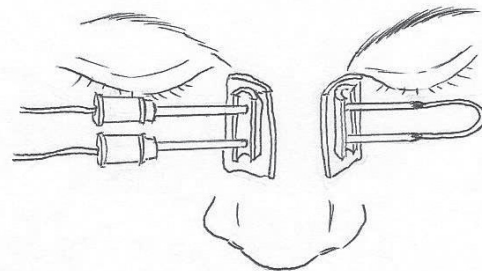


Fig. 3. An external fixation device, composed of silastic sheets and nelaton tube, was placed in the bilateral sides of the nasal pyramid. A wiring was performed by exerting a light pressure to such an extent as to maintain the symmetry and projection of the nasal bone.

2) Evaluation of postoperative nasal contour

One month postoperatively, we evaluated the result of reduction. Based on physical examination, photography and preoperative and postoperative plain radiography, the physician evaluated the postoperative nasal contour: straight nose and good contour, minor deformity and major deformity. Minor deformity included bony irregularity and major deformity included nasal hump and obvious deviation. The patient satisfaction scores were also evaluated according to a 3-point scale through an interview: "satisfied (3 points)", "fair (2 points)" and "dissatisfied (1 point)".

3) Postoperative degree of pain

Twenty patients with lateral impacted plane II fracture of the group A were randomly assigned to the CR group, and 20 patients with lateral impacted plane II fracture of the group B were randomly assigned to the IOR group. The randomization was done based on the computer-generated sequence. To compare the degree of pain between the two groups, we evaluated the dose of analgesics and pain scores. To determine the treatment dose of analgesics, we performed a review of the medication sheet and thereby evaluated the dose of ketorolac tromethamine (Kerola, Dong Kwang Pharm., Seoul, Korea) which was intravenously given to the patients for 24 hours postoperatively. The pain scores were evaluated according to a visual analogue scale, ranging from 0 to 10, on postoperative day 1 through a review of the pain observation sheet.

4. Statistical analysis

Statistical analysis was performed using SPSS ver. 14 (SPSS Inc., Chicago, IL, USA). We performed a chi-square test to compare the

distribution of the pattern between group A and B. To postoperatively compare the result of reduction between group A and B and the treatment dose of analgesics and pain scores between CR group and IOR group, we performed chi-square test and independent t-test. A p -value of <0.05 was considered statistically significant.

Results

1. Distribution of fracture types

In both group A and B, the lateral impacted plane II fracture was the most prevalent and the comminuted fracture was the least prevalent. There were no significant differences in the distributions of fracture patterns between the two groups ($p>0.05$) (Table 1).

2. Postoperative nasal contour

After reduction, the group B presents more straight nose and good contour than the group A (81% vs. 71%, $p>0.05$). Minor deformity was less occurred in the group B compared to the group A (16% vs. 19%, $p>0.05$). Major deformity was less occurred in the group B compared to the group A (3% vs. 10%, $p<0.05$) (Table 2). Mean postoperative patient satisfaction scores were higher in the group B than the group A (2.86 points vs. 2.79 points, $p>0.05$) (Table 3).

3. Postoperative degree of pain

Postoperatively, the dose of analgesics was significantly lower in the IOR group as compared with the CR group (53 mg vs. 142 mg,

Table 1. Distribution of nasal bone fracture type between group A and B

Fracture type	Group A (n=128)	Group B (n=127)	p -value
Frontal impact, plane I	18 (14)	14 (11)	0.154 ^{a)}
Frontal impact, plane II	18 (14)	10 (8)	
Lateral impact, plane I	33 (26)	33 (26)	
Lateral impact, plane II	50 (39)	63 (50)	
Comminution	9 (7)	7 (5)	

Values are presented as number (%).

^{a)}The difference between group A and B is not significant by chi-square test ($p>0.05$).

$p < 0.05$). Mean postoperative pain scores were lower in the IOR group as compared with the CR group (7.8 points vs. 8.5 points, $p > 0.05$) (Table 4).

4. Case reports

1) Case 1

A 26-year-old woman sustained nasal injury by the fist. The nose showed slight deviation to the patient's right. Radiographs revealed dislocation of the nasal bone (Fig. 4A–C). Patient's right intercartilaginous incision was made following a local infiltration under general anesthesia. Using metzenbaum scissors and a periosteal elevator, the dissection was done up to the caudal border of the fractured bone segment. A nasal elevator was placed between the nasal bone and the mucosa. With the tactile sense of the bone fragments from an elevator tip and synchronously the opposite thumb and index finger, the bone fragments were reduced to the original position. Postoperatively, Meroceal was packed bilaterally in the superior meatus and Doyle Combo Splints was packed in the middle

meatus. The intranasal packs were removed after 5 days. External nasal appearance was very good with no complications up to 6 months after operation, and radiographs showed accurate reduction (Fig. 4D–F).

2) Case 2

An 18-year-old man sustained nasal injury by the baseball. The nose showed deviation to the patient's right with flattening. Radiographs revealed severe comminution and deviation of the nasal bone and the frontal process of the right maxilla (Fig. 5A–C). The comminuted bone fragments were disimpacted and then realigned using Asch forceps under general anesthesia. An external fixation device was placed in the bilateral sides of the nasal pyramid. Under the guidance of a hand-drilled, threaded K-wire, two 18-gauge needles were horizontally inserted in the nasal pyramid. A 26-gauge stainless-steel wire was inserted through a needle. A wiring was performed by exerting a light pressure to such an extent as to maintain the symmetry and projection of the nasal bone. The wire was removed on postoperative day 5. External nasal appear-

Table 2. Comparison of postoperative nasal contour between group A and B

Postoperative nasal contour	Group A (n=128)	Group B (n=127)	p-value
Straight nose and good contour	91 (71)	103 (81)	0.061
Minor deformity	24 (19)	20 (16)	0.526
Major deformity	13 (10)	4 (3)	0.025 ^{a)}

Values are presented as number (%).

^{a)}The difference between group A and B is significant by chi-square test ($p < 0.05$).

Table 3. Comparison of subjective satisfaction scores between group A and B

Subjective satisfaction	Score	Group A (n=128)	Group B (n=127)
Satisfied	3	104 (81)	110 (87)
Fair	2	22 (17)	16 (13)
Dissatisfied	1	2 (2)	1 (1)
Average score ^{a)}	-	2.80	2.86

Values are presented as number (%).

^{a)}The difference between group A and B is not significant by independent t-test ($p > 0.05$).

Table 4. Comparison of degree of pain according to the CR and IOR group in lateral impact II typed nasal bone fracture

Degree of pain	CR group (n=20)	IOR group (n=20)
Kerola given (mg) ^{a)}	142	53
Pain score (point)	8.5	7.8

CR, closed reduction; IOR, indirect open reduction.

^{a)}The difference of Kerola given between CR and IOR group is significant by independent t-test ($p < 0.05$).

ance was very good with no complications up to 5 months after the operation. There was almost invisible scar at the puncture site where the wires had been inserted (Fig. 5D–F).

Discussion

The CR is a treatment modality that has been performed to treat the nasal fracture over the past several thousand years [7]. It is advantageous that it is a simple procedure and can be done under local anesthesia. But the blunt pressure to reduce the

bone fragments is difficult to achieve the appropriate reduction in cases of severely displaced or overlapped bone fragments. In spite of adequate CR, the incidence of posttraumatic nasal deformity could remain high [3]. If the nasal deformity occurs, it is not easy to be corrected and it requires the additional cost for revision rhinoplasty [2]. Therefore, aggressive surgical techniques would be essential for appropriately treating the nasal fracture. And it would be mandatory to determine the technique according to the patterns of fractures for the optimal treatment of the nasal fracture. Various management al-

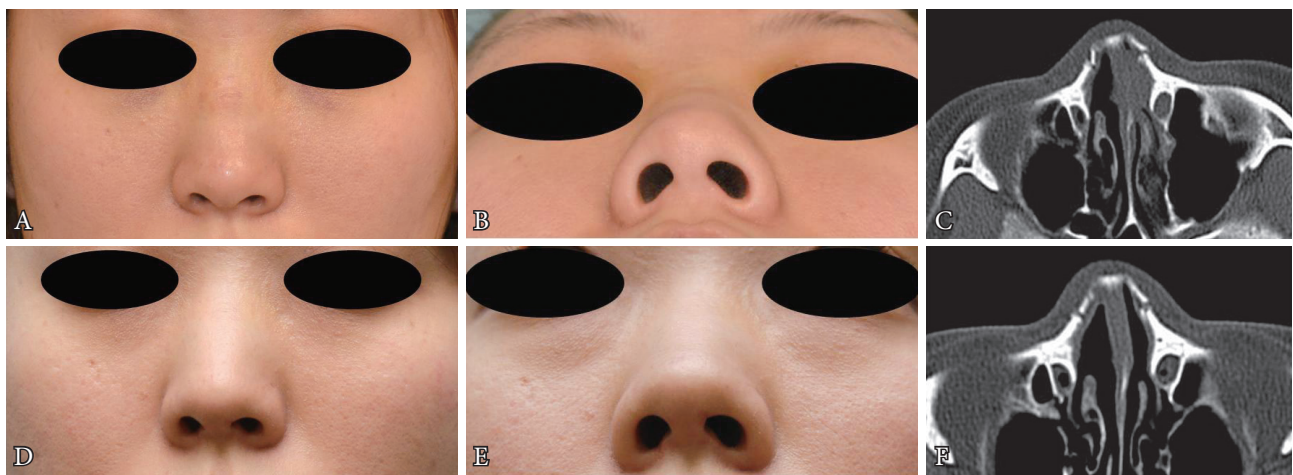


Fig. 4. Case 1. A 26-year-old woman injured by lateral impact. (A, B) Preoperative view. (C) Preoperative computed tomography scans. (D, E) Six months after indirect open reduction. There were no postoperative complications and the patient showed satisfaction at follow-up. (F) Postoperative computed tomography scans.

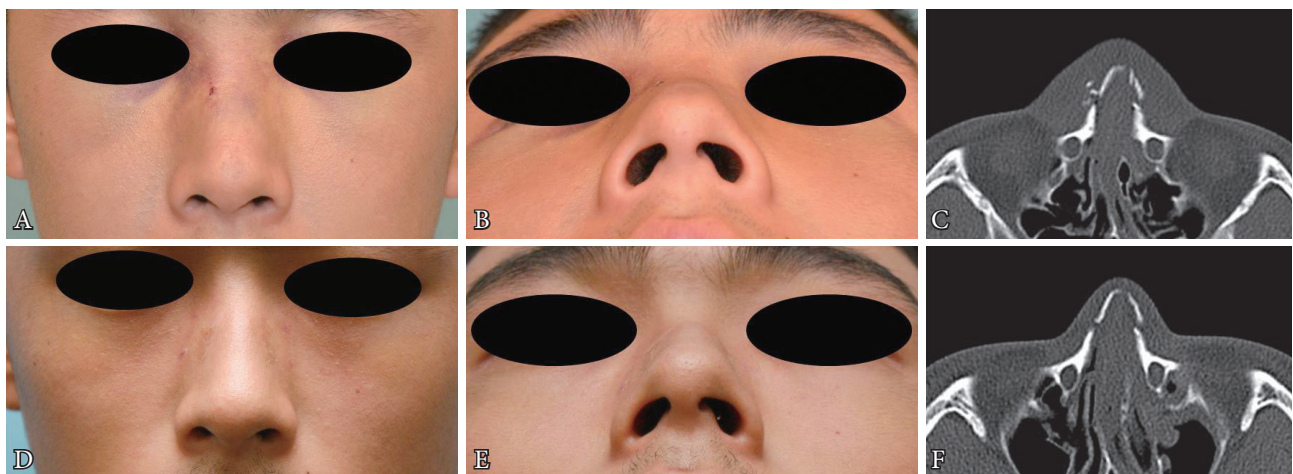


Fig. 5. Case 2. A 18-year-old man injured by frontal impact. (A, B) Preoperative view. (C) Preoperative computed tomography scans showing comminuted nasal fracture with deviation to the right. (D, E) Five months after surgery. There were no postoperative complications and the patient showed satisfaction at follow-up. (F) Postoperative computed tomography scans showing the proper reduction of nasal fracture and the adequate support of the stainless-steel wire.

gorithms of nasal fracture were reported to provide each patient with an aesthetically and functionally superior repair. But these were no reports that demonstrated the usefulness of management algorithm objectively. In most cases, however, invasive techniques such as osteotomy and open rhinoplasty that were used for severe fractures were too aggressive to apply to many patients widely.

The nasal fracture displays various clinical characteristics with the pattern of fracture. According to the Stranc classification, the incidence of nasal deformity is higher in the lateral impacted fracture as compared with frontal impacted fracture [8]. As compared with the plane I fracture, the incidence of complications is relatively higher in the plane II fracture [8]. Therefore, aggressive surgical techniques are strongly recommendable for the all of lateral impacted fractures and the frontal impacted plane II fracture except frontal impacted plane I fracture. In the current study, major deformity was less occurred in the group B than the group A. This result is due to the fact that reduction techniques, IOR and EF as well as CR, were determined according to the patterns of fractures in the group B.

The IOR was first introduced by Burm and Oh [4] who performed the IOR concomitantly with the K-wire splinting for the treatment of the comminuted fracture. Compared to the CR, the IOR has advantages as following: 1) more accurate reduction, 2) less mucosal injury, and 3) less postoperative pain. Although the bone fragments cannot be visually observed, they could be more accurately reduced to the original position through the tactile sensation of the hand from an elevator tip in IOR. Another advantage of the IOR is that it can prevent additional mucosal injury induced by surgical instruments because it directly transfers the force to the bone fragments instead of passing through the mucosa. Because the mucosal injury may cause a nasal deformity due to the contracture of the soft tissue, it is important to reduce the mucosal injury for appropriately treating the nasal fracture. Some author measured the degree of mucosal injury through the intraoperative nasal bleeding [9]. In the current study, the degree of mucosal injury was measured quantitatively based on the treatment dose of analgesics and pain scores. Although pain scores were not significantly different between both group, treatment dose of analgesics and pain scores

were lower in IOR group than CR group. These results suggest that the degree of pain were not too severe to need analgesics in IOR group, compared to CR group.

In our experience, nasal crust often occurred after IOR and removal of nasal packing. Patients complained airway discomfort resulting from nasal crust of intercartilaginous suture site during follow-up observation. These problems were resolved without difficulty through removal of nasal crust with forceps. In addition, synechia infrequently occurred after IOR. In most patients, they were not affected the result of reduction and postoperative discomfort. And there were no cases of nasal skin or mucosal necrosis related to the IOR procedure.

In frontal impacted plane I fracture, although some authors suggested the IOR method [4], we could treated the nasal fracture effectively with CR using a C-arm visualization that offers real-time imaging assistance and enables precise correction of a fractured nose. In the comminuted fracture, Burm and Oh [4] suggested the IOR and intranasal K-wire splinting. However, some authors were concerned that the submucosal dissection in the IOR procedure could scattered the comminuted fracture segments that were maintained by the soft tissue into multiple separate pieces and disrupted the blood circulation of the fractured fragments [9]. In this situation, therefore, external fixation technique was useful to rebuild the nasal contour.

There were some limitations of the current study that we had short term follow-up of patients after reduction. It was not easy to have long term follow-up of patients who considered that nasal fracture was minor injury. And we could not obtain postoperative computed tomography scan in most of the patients due to the insurance policy.

In conclusion, minimizing the occurrence of long-term nasal deformity, appropriate assessment and reduction of the nasal pyramid and septum would be essential for the optimal treatment of the nasal fracture. CR was performed in frontal impacted plane I fracture. IOR was used actively in severe cases of nasal fracture, all of lateral impacted fractures and the frontal impacted plane II fracture. In comminuted fracture, external fixation was used. As a result, we could reduce the overtreatment and obtain the satisfactory treatment outcomes, postoperatively.

Conflict of Interest

No potential conflict of interest relevant to this article was reported.

References

1. Verwoerd CD. Present day treatment of nasal fractures: closed versus open reduction. *Facial Plast Surg* 1992;8:220-3.
2. Staffel JG. Optimizing treatment of nasal fractures. *Laryngoscope* 2002;112:1709-19.
3. Rohrich RJ, Adams WP Jr. Nasal fracture management: minimizing secondary nasal deformities. *Plast Reconstr Surg* 2000;106:266-73.
4. Burm JS, Oh SJ. Indirect open reduction through intercartilaginous incision and intranasal Kirschner wire splinting of comminuted nasal fractures. *Plast Reconstr Surg* 1998;102:342-9.
5. Kochar HS. An innovative approach to external fixation of severe nasal bone fractures with orthopedic plates. *Ear Nose Throat J* 2011;90:102-4.
6. Stranc ME, Robertson GA. A classification of injuries of the nasal skeleton. *Ann Plast Surg* 1979;2:468-74.
7. Murray JA, Maran AG, Mackenzie JJ, Raab G. Open v closed reduction of the fractured nose. *Arch Otolaryngol* 1984;110:797-802.
8. Park WY, Kim YH. A clinical study of the nasal bone fracture according to stranc classification. *J Korean Soc Plast Reconstr Surg* 2008;35:289-94.
9. Kim HS, Suh HW, Ha KY, Kim BY, Kim TY. The usefulness of the endonasal incisional approach for the treatment of nasal bone fracture. *Arch Plast Surg* 2012;39:209-15.