

구개열 환자에서 포비돈 아이오다인에 의한 흡인성 폐렴

김석화¹ · 석효현¹ · 정의철² · 박지웅² · 최태현¹

¹서울대학교 의과대학 성형외과학교실, ²서울대학교병원운영 서울특별시 보라매병원 성형외과

Aspiration Pneumonia caused by Povidone-iodine (Betadine) in Cleft Palate Patient

Sukwha Kim¹, Hyo Hyun Seok¹, Eui Cheol Jeong², Ji Ung Park², Tae Hyun Choi¹

¹Department of Plastic and Reconstructive Surgery, Seoul National University College of Medicine, Seoul;

²Department of Plastic Surgery, SMG-SNU Boramae Medical Center, Seoul, Korea

Povidone-iodine (PVP-I, Betadine) has many advantages as a disinfectant solution for preoperative preparations, especially for oral surgery. It is widely used because of its low toxicity and excellent bactericidal effect. The authors report a case of pneumonia secondary due to the aspiration of PVP-I, which was used as an oral disinfectant. We present a case of aspiration pneumonia that resulted from the careless use of PVP-I during preoperative preparation. The patient was a 10-month-old female scheduled for elective surgery to correct a complete cleft of secondary palate. During the preparation of the oral cavity for that cleft palate patient, PVP-I was incidentally aspirated to the airway. The lung resistance was noted with positive pressure and pneumonic infiltration on chest radiograph was seen. The operation was postponed and the patient underwent respiratory care. Three months later, elective palatoplasty under general anesthesia was performed without complication. Based on the experiences of this case, the authors advise that throat-packing should be placed before oral preparation to prevent serious pulmonary complications.

Keywords: Aspiration pneumonia / Povidone-iodine / Cleft palate

Introduction

The use of topical disinfectant solution is common during the preoperative preparation of general surgical fields, in addition to preoperative antibiotic prophylaxis. In particular, intraoral procedures are performed after decontaminating the oral cavity of normal microbial flora [1,2]. Various agents are available for oral disinfectant, such as, saline irrigation, iodine, and other antimicrobials, the usages of which are based on surgeons' preferences. Neverthe-

less, Povidone-iodine (PVP-I, Betadine, Korea Pharma Co., Seoul, Korea) is commonly chosen because of its safety and effectiveness. Here, we present a case of aspiration pneumonia that resulted from the careless use of PVP-I during preoperative preparation.

Case Report

The patient was a 10-month-old female patient scheduled for elective surgery to correct a complete cleft of secondary palate. Her medical history was unremarkable and she had no history of allergy. On admission, she weighed 9 kg and was well-developed, and well-nourished. In addition, her vital signs and routine admission laboratory and chest radiograph findings were all within normal limits.

The patient was placed under general anesthesia. A 4.0 Ring-Adair-Elwyn endotracheal tube without a cuff was inserted, and

Correspondence: Eui Cheol Jeong
Department of Plastic Surgery, SMG-SNU Boramae Medical Center, 20 Boramae-ro 5-gil, Dongjak-gu, Seoul 156-707, Korea
Tel: +82-2-870-2331 / Fax: +82-2-831-2826 / E-mail: ejeong.md@gmail.com

*This article was presented at the 65th congress Annual Meeting of the Korean Society of Plastic and Reconstructive Surgeons on November 8-10, 2009, in Seoul, Korea.

Received March 5, 2013 / Revised March 27, 2013 / Accepted April 1, 2013

this was followed by a routine disinfectant preparation of head and neck skin and of the oral cavity with diluted PVP-I solution.

After positioning and draping, an attempt was made to insert a Dingman mouth gag, but during this attempt, the previously applied endotracheal tube slipped out. After applying suction in the oral cavity, the anesthesiologist promptly re-intubated the patient. However, SaO₂ dropped to 72% and pulmonary rales and increased lung resistance were noted with positive pressure. These events were presumed to be due to increased secretion in the (lung), and thus, the endotracheal tube was suctioned. The fluid suctioned was tinged brown and consistent with PVP-I. Aspiration was then suspected, and trachea and bronchi were lavaged with sterile saline through the endotracheal tube and suctioning was reapplied.

At this time, arterial blood gas values were; pH 7.28, PaO₂ 65 mm Hg, PaCO₂ 43 mm Hg, SaO₂ 89%, BE -6.2 mmol/L, and FiO₂ 100% and the chest radiograph revealed ill-defined increased opacities in the right upper lobe—suggestive of aspiration pneumonia (Fig. 1). Adequate O₂ supply and positive pressure mechanical ventilation were instituted and gradually her vital signs stabilized.

Surgery was postponed due to intense concerns of possible postoperative respiratory complications. On emergence from anesthesia, the patient was transferred while intubated to our intensive care unit (ICU). Pulmonary cleansing was undertaken in the

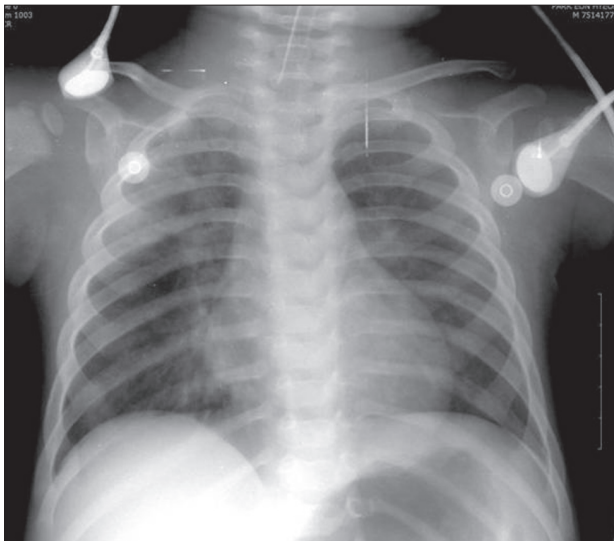


Fig. 1. Suggestive radiologic finding of aspiration pneumonia. Intraoperative chest posteroanterior view showing ill-defined infiltration in the right upper lung lobe.

ICU and included frequent suctioning and O₂ inhalation. Subsequently, her condition became more stable and serial blood gas values improved. The use of the endotracheal tube was terminated about 2 hours after emergence. However, rale sounds persisted and intermittent fever was noted. At this time, a pediatric pulmonologist was collaborating with us on the case. Additional antibiotic therapy and intermittent nebulization were administered, and a sputum culture disclosed no significant pathogens.

A week after the aborted surgery, radiographic improvements were evident and she was subsequently discharged (Fig. 2). Follow up examinations were uneventful and no further sequelae developed. Three months later, elective palatoplasty under general anesthesia was performed without complication.

Discussion

PVP-I is formed by adding free iodine to polyvinyl-pyrrolidone (PVP), a solubilizing agent, to reduce the toxicity of iodine. When iodine is liberated from PVP after application, it reacts with the membranous proteins of microorganisms. However, although PVP-I was developed with safety in mind and has proven wide-spectrum anti-

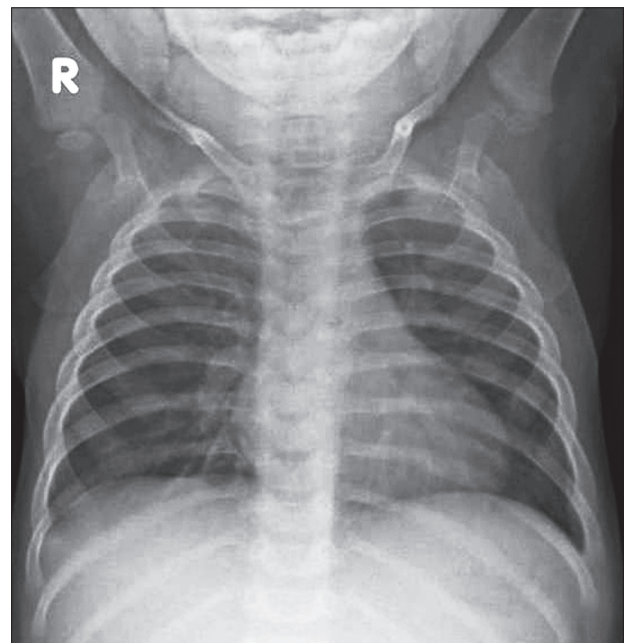


Fig. 2. Follow-up chest radiograph obtained before discharge, showing the absence of abnormal opacities.

bactericidal effects, its aspiration can lead to serious complications [1,2]. Furthermore, PVP-I is contraindicated in pregnant patients and in patients with thyroid dysfunction, because of the systemic effects of iodine. Moreover, prolonged use of PVP-I may induce bradycardia, hypertension, and detrimentally affect liver and renal function [1].

We explored the world literature on this topic through PUBMED (National Library of Medicine, revised 1st April 2001) using appropriate keywords and Boolean operators. The cases of aspiration pneumonia resulting from PVP-I aspiration perioperatively are very rare, and their reported clinical manifestations and courses were similar to those observed in this presented case [2-4]. Intuitively, PVP-I impinges on the cell membrane of organisms to cause dermatitis by the same action on skin tissue [1]. Therefore, it would also have an adverse effect on respiratory mucosa and tissue more fragile than skin. Chemical pneumonia by aspiration during the general anesthesia, well known as Mendelson's syndrome, is characterized by a bronchopulmonary reaction following aspiration of gastric contents. The main features are hypoxia, wheezing, low blood pressure, and decreased arterial oxygen tension. In serious cases, it causes acute pulmonary edema leading to sudden death. Treatments are mainly focused on the prevention, that is administering an antacid or H2-antagonist in high risk patients [2]. On the other hand, in the previous reported cases of PVP-I, symptoms improved under respiratory supportive care and management without no sequelae. The authors believe that the reason is the lower pH of gastric contents than that of PVP-I and the tendency of

larger amount of the aspirated contents in gastric aspiration cases.

But, most importantly, reported cases demonstrate that proper precautions must be taken to prevent PVP-I aspiration. In particular, young children have a short, small airway, and thus, a small diameter endotracheal tube without a cuff is often used for palatoplasty. Furthermore, it is somewhat difficult to insert a Dingman mouth gag into the oral cavity because it has several hooks and notches, if a gag is handled carelessly, tubes easily slipped out. Therefore, aspiration may occur more frequently in children during disinfectant procedures. Howe recommended that a throat-pack (Fig. 3) should be placed and that the cuff of the nasotracheal tube be adequately inflated before introducing an antiseptic solution [3]. The remaining secretion or fluid in the oral cavity should be sucked and cleaned as closely as possible before application of Dingman mouth gag. Furthermore, in a survey of oral decontamination methods among maxillofacial surgeons in the US, a throat-pack was also placed before general anesthesia to prevent antiseptic solution aspiration, and positive intrathoracic pressure was applied by the anesthesiologist during oral preparation [5]. The lesson to be learnt from experiences to date, is that every precaution, such as, throat-pack placement and application of the surgical devices, should be taken during the preparation of the oral cavity.

Conflict of Interest

No potential conflict of interest relevant to this article was reported.

References

1. Ahn MJ, Jeon Y, Chung DS. Primary irritant dermatitis to Povidone-iodine after caudal anesthesia: a case report. *Korean J Anesthesiol* 2004;46:114-8.
2. An TH, Ahn BR. Pneumonia due to aspiration of povidone iodine after induction of general anesthesia: a case report. *Korean J Anesthesiol* 2011;61:251-6.
3. Howe DJ. Aspiration pneumonia from povidone-iodine (Betadine): report of case. *J Oral Surg* 1981;39:224-5.
4. Numazawa R, Morimoto Y, Yokota S, Yamamura T, Kemmotsu O. Pneumonia due to aspiration of povidone-iodine during anesthesia: a case report. *Masui* 1992;41:846-9.
5. Summers AN, Larson DL, Edmiston CE, Gosain AK, Denny AD, Radke L. Efficacy of preoperative decontamination of the oral cavity. *Plast Reconstr Surg* 2000;106:895-900.

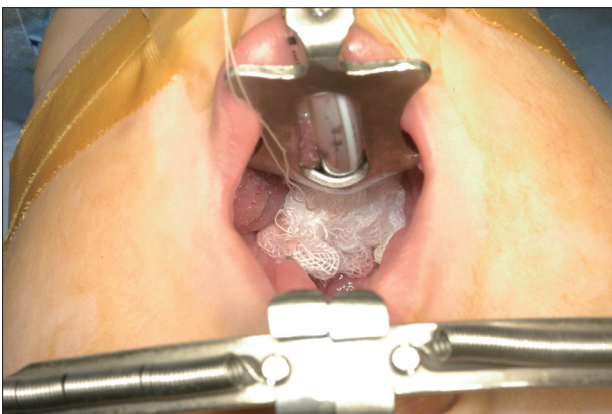

Fig. 3. A throat-pack applied before intraoral preparation. A throat-pack was placed before introducing antiseptic solution to prevent serious pulmonary complications.