

## Cardiac Resynchronization Therapy Using a Dual Chamber Pacemaker in Patients with Severe Left Ventricular Dysfunction and a Left Bundle Branch Block

Jae Jun Jung, M.D., In Sook Kim, M.D., Jae-Han Jeong, M.D., Young Tak Lee, M.D., Dong Seop Jeong, M.D.

Through the use of a dual chamber (DDD) pacemaker, we achieved a cardiac resynchronization effect in a 51-year-old female patient who was transferred to our hospital from another hospital for an operation for three-vessel coronary artery disease. Her electrocardiogram showed a left bundle branch block (LBBB) and a prolonged QRS interval of 166 milliseconds. Severe left ventricle (LV) dysfunction was diagnosed via echocardiography. Coronary artery bypass grafting (CABG) was then performed. In order to accelerate left atrial activation and reduce the conduction defect, DDD pacing using right atrial and left and right ventricular pacing wires was initiated postoperatively. The cardiac output was measured immediately, and one and twelve hours after arrival in the intensive care unit. The cardiac output changed from 2.8, 2.4, and 3.6 L/min without pacing to 3.5, 3.4, and 3.5 L/min on initiation of pacing. The biventricular synchronization using DDD pacing was turned off 18 hours after surgery. She was transferred to a general ward with a cardiac output of 3.9 L/min. In patients with coronary artery disease, severe LV dysfunction, and LBBB, cardiac resynchronization therapy can be achieved through DDD pacing after CABG.

Key words: 1. Bundle-branch block  
2. Dual chamber (DDD) pacemaker  
3. Cardiac resynchronization therapy

### CASE REPORT

A 51-year-old female with mild dyspnea of New York Heart Association (NYHA) functional class II heart failure and dysarthria due to a transient ischemic attack was diagnosed with dilated cardiomyopathy (ejection fraction 23%) through echocardiography and three-vessel disease through coronary angiography (proximal left anterior descending artery 60% stenosis, middle left anterior descending artery 60% to 70% stenosis, and distal left circumflex artery complete occlusion). The patient was transferred to our hospital for

coronary artery bypass graft (CABG) surgery.

She had a diagnosis of hypertension and a history of an intraventricular block eight years earlier that was treated with digoxin, diuretics, beta-blockers, and an angiotensin-receptor blocker. Cardiomegaly was found on a posteroanterior chest radiograph, and a left bundle branch block (LBBB) pattern and prolonged QRS interval were identified on an electrocardiogram (ECG). Echocardiography also demonstrated left ventricle (LV) distension, severe LV dysfunction with a left ventricular ejection fraction (LVEF) of 28%, and mild mitral regurgitation. Pro-B-type natriuretic peptide was 2,070 pg/mL,

Department of Thoracic and Cardiovascular Surgery, Samsung Medical Center, Sungkyunkwan University School of Medicine

Received: October 29, 2012, Revised: January 27, 2013, Accepted: March 7, 2013

Corresponding author: Young Tak Lee, Department of Thoracic and Cardiovascular Surgery, Samsung Medical Center, Sungkyunkwan University School of Medicine, 81 Irwon-ro, Gangnam-gu, Seoul 135-710, Korea  
(Tel) 82-2-3410-1278 (Fax) 82-2-3410-0089 (E-mail) [cabg@korea.com](mailto:cabg@korea.com)

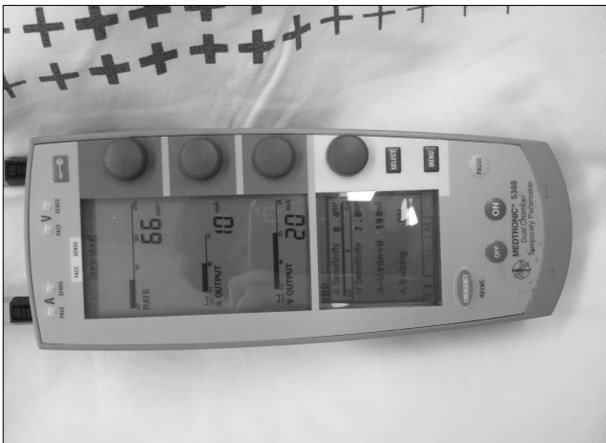© The Korean Society for Thoracic and Cardiovascular Surgery. 2013. All right reserved.

© This is an open access article distributed under the terms of the Creative Commons Attribution Non-Commercial License (<http://creativecommons.org/licenses/by-nc/3.0>) which permits unrestricted non-commercial use, distribution, and reproduction in any medium, provided the original work is properly cited.

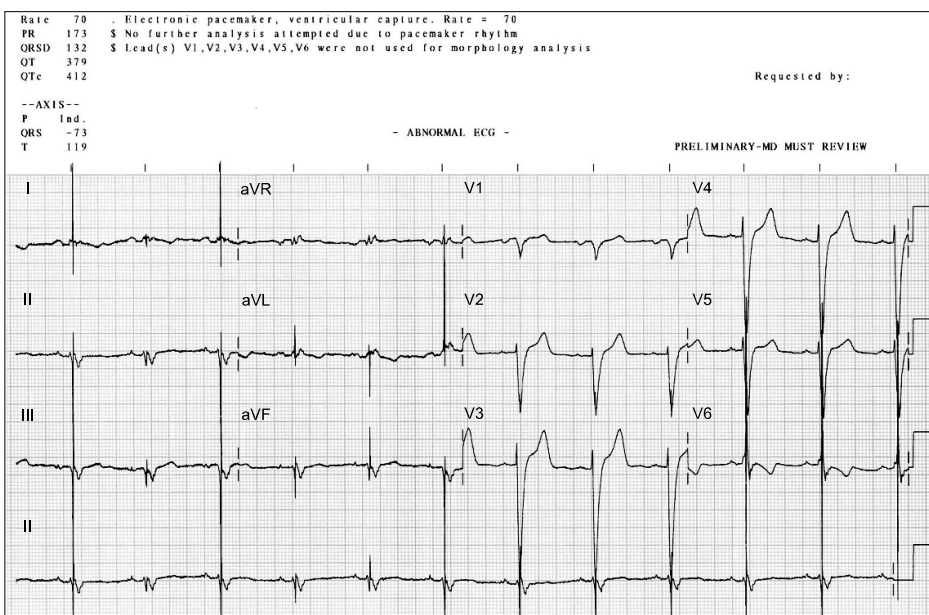
and cardiac markers were normal. On-pump CABG was performed on day two of hospitalization. The left anterior descending coronary artery and diagonal branch were connected to the left internal mammary artery *in situ*, and a saphenous vein graft was used to connect the posterior descending artery and posterolateral artery. The patient had LV incompetence. Cardiac resynchronization therapy was attempted. Two temporary, unipolar, atrial pacing wires were inserted in the right atrium wall, and two temporary, bipolar, ventricular pacing wires were inserted into the right ventricular anterior wall and

the left ventricular inferior wall. Temporary pacemakers (Medtronic 5388 Dual Chamber Temporary Pacemaker; Medtronic Inc., Minneapolis, MN, USA) were used since cardiac resynchronization therapy equipment was unavailable (Fig. 1). The rate was set to 66 ppm, and the sensitivities were set to 0.4 mV for the atria and 2.0 mV for the ventricles. The output was set to 10 mA for the atria and 20 mA for the ventricles. Wires inserted in the right atrium and left ventricular inferior wall were used, and a 196-millisecond PR interval verified from a preoperative ECG was used as a standard. QRS intervals were observed via ECG, and the PR interval was manipulated. The narrowest QRS was found using the PR interval standard, and the setting was changed (Fig. 2). Before cardiac resynchronization therapy (CRT) was initiated, intraoperative transesophageal echocardiography showed that the LVEF measured below 25%. On initiation of CRT, the LVEF increased visibly to about 40%. The cardiac output was measured immediately, and one hour and twelve hours after arrival in the intensive care unit. The cardiac output changed from 2.8, 2.4, and 3.6 L/min without pacing to 3.5, 3.4, and 3.5 L/min on initiation of pacing (Table 1).

The patient's postoperative vital status was stable on intravenous dopamine and nitroglycerin. CRT was used for 18 hours. A cardiac output of 3.8 L/min was maintained after turning the CRT off, and the cardiac output was 3.9 L/min



**Fig. 1.** The pacemaker used in this case (Medtronic 5388 Dual Chamber Temporary Pacemaker; Medtronic Inc.).



**Fig. 2.** Electrocardiogram in cardiac resynchronization therapy.

**Table 1.** Hemodynamic results of atrioventricular pacing

	Immediate		After 1 hour		After 12 hours	
	CRT off	CRT on	CRT off	CRT on	CRT off	CRT on
Cardiac output (L/min)	2.8	3.5	2.4	3.4	3.6	3.5
QRS interval (ms)	151	125	158	138	148	132

CRT, cardiac resynchronization therapy.

when the patient was transferred to the general ward.

## DISCUSSION

Patients with LBBB have abnormal heart sounds and global ventricular dysfunction caused by abnormal diastolic filling times, abnormal interventricular septal motions, and abnormal left ventricular regional ejection fractions [1].

CRT accelerates ventricular activation in patients with incompetent LVs, leading to a more ideal contraction pattern and reducing conduction defects between the atria and ventricles. When CRT is performed in moderate or severe heart failure cases due to cardiac dyssynchrony and left ventricular systolic dysfunction, cardiac dyssynchrony is reduced, left ventricular performance and perfusion pressures increase, cardiac filling pressures decrease, and left ventricular remodeling improves. Through these effects, CRT reduces symptoms, complications, and mortality. Similar results have been found in patients with both ischemic and non-ischemic heart disease [2]. Although CABG itself neither eliminates dyssynchrony nor improves systolic function, epicardial implantation of a CRT system concomitant with CABG facilitates patient management in the early postoperative period and improves LV systolic function [3].

Indications for biventricular pacing include patients with idiopathic dilated or ischemic cardiomyopathies causing symptomatic NYHA class III or IV heart failure with QRS intervals that are prolonged for more than 130 milliseconds, LV end-diastolic diameters greater than 55 mm, and ejection fractions of less than 35% [4]. In addition, atrioventricular pacing may improve quality of life and motor abilities while reducing hospitalization time when compared to biventricular pacing [5].

There is still controversy over which part of the LV should

be manipulated to maximize effects. The current literature demonstrates that manipulating the lateral wall of the LV is the most effective [6].

In this case, the patient presented with severe LV dysfunction with a LBBB pattern, a prolonged QRS interval of 166 milliseconds, and LVEF of 28%. To synchronize the LV for a more ideal contraction pattern and reduce the conduction defect between the atrium and ventricle, cardiac resynchronization was performed with a dual chamber (DDD) pacemaker. Cardiac output and QRS interval improvement were observed with postoperative testing by switching on and off the biventricular synchronization. We maintained atrioventricular and resynchronizing pacing for a relatively short period (18 hours). Future research should include comparisons with biventricular pacing and permanently maintained pacing.

## CONFLICT OF INTEREST

No potential conflict of interest relevant to this article was reported.

## REFERENCES

1. Grines CL, Bashore TM, Boudoulas H, Olson S, Shafer P, Wooley CF. *Functional abnormalities in isolated left bundle branch block: the effect of interventricular asynchrony*. Circulation 1989;79:845-53.
2. Cleland JG, Daubert JC, Erdmann E, et al. *The effect of cardiac resynchronization on morbidity and mortality in heart failure*. N Engl J Med 2005;352:1539-49.
3. Pokushalov E, Romanov A, Prohorova D, et al. *Coronary artery bypass grafting with concomitant cardiac resynchronization therapy in patients with ischaemic heart failure and left ventricular dyssynchrony*. Eur J Cardiothorac Surg 2010; 38:773-80.
4. Gregoratos G, Abrams J, Epstein AE, et al. *ACC/AHA/*

Jae Jun Jung, et al

*NASPE 2002 guideline update for implantation of cardiac pacemakers and antiarrhythmia devices: summary article: a report of the American College of Cardiology/American Heart Association Task Force on Practice Guidelines (ACC/AHA/NASPE Committee to Update the 1998 Pacemaker Guidelines).* Circulation 2002;106:2145-61.

5. Cazeau S, Leclercq C, Lavergne T, et al. *Effects of multisite*

*biventricular pacing in patients with heart failure and intraventricular conduction delay.* N Engl J Med 2001;344:873-80.

6. Butter C, Auricchio A, Stellbrink C, et al. *Should stimulation site be tailored in the individual heart failure patient?* Am J Cardiol 2000;86:144K-51K.