

Iatrogenic Perforation of the Left Ventricle during Insertion of a Chest Drain

Dongmin Kim, M.D.¹, Seong-Hoon Lim, M.D.¹, Pil Won Seo, M.D.²

Chest draining is a common procedure for treating pleural effusion. Perforation of the heart is a rare often fatal complication of chest drain insertion. We report a case of a 76-year-old female patient suffering from congestive heart failure. At presentation, unilateral opacity of the left chest observed on a chest X-ray was interpreted as massive pleural effusion, so an attempt was made to drain the left pleural space. Malposition of the chest drain was suspected because blood was draining in a pulsatile way from the catheter. Computed tomography revealed perforation of the left ventricle. Mini-thoracotomy was performed and the drain extracted successfully.

Key words: 1. Heart
2. Complications
3. Chest tubes

CASE REPORT

A 76-year-old female patient presented at the emergency department with dyspnea, a productive cough, and a fever for several days. She had experienced exacerbations of congestive heart failure for the previous 20 years and had a permanent cardiac pacemaker that had also been initially inserted about 20 years earlier due to sick sinus syndrome with atrial fibrillation. She also had dementia, and a history of multiple incidents of cerebral infarction and its complications.

At the emergency department, her blood pressure was 112/72 mmHg, pulse rate was 101/min with an irregular rhythm, and body temperature was 36.5°C. On examination, she appeared tachypneic (respiratory rate, 28/min) and her breathing sounds were reduced over the left lung field. The arterial oxygen saturation in room air was 92%. The other laboratory findings were not notable. Chest radiography re-

vealed opacification of the whole left lung field, thought by a physician of the emergency department to be unilateral pleural effusion (Fig. 1). Therefore, after local anesthesia and under sterile conditions, a 16F catheter (Prime-S; Sungwon Medical, Cheongju, Korea) was inserted into the 6th left intercostal space in the anterior axillary line without image guidance.

Shortly after insertion, blood was draining in a pulsatile way from the catheter. However, she was hemodynamically stable with a blood pressure of 132/78 mmHg and a heart rate of 98/min. After clamping the catheter, contrast-enhanced computed tomography (CT) of the chest was performed (Fig. 2) and showed that severe cardiomegaly with displacement of the heart to the left with atelectasis (originally thought to be massive pleural effusion). The catheter had been inserted anterolaterally into the sixth intercostal space on the left and was within the left ventricle, exiting the ventricle through the

Departments of ¹Internal Medicine and ²Thoracic Surgery, Dankook University College of Medicine

Received: July 25, 2012, Revised: November 9, 2012, Accepted: November 15, 2012

Corresponding author: Pil Won Seo, Department of Thoracic Surgery, Dankook University College of Medicine, 119 Dandae-ro, Dongnam-gu, Cheonan 330-997, Korea

(Tel) 82-41-550-3984 (Fax) 82-41-550-3984 (E-mail) pwseo@dankook.ac.kr

© The Korean Society for Thoracic and Cardiovascular Surgery. 2013. All right reserved.

© This is an open access article distributed under the terms of the Creative Commons Attribution Non-Commercial License (<http://creativecommons.org/licenses/by-nc/3.0>) which permits unrestricted non-commercial use, distribution, and reproduction in any medium, provided the original work is properly cited.

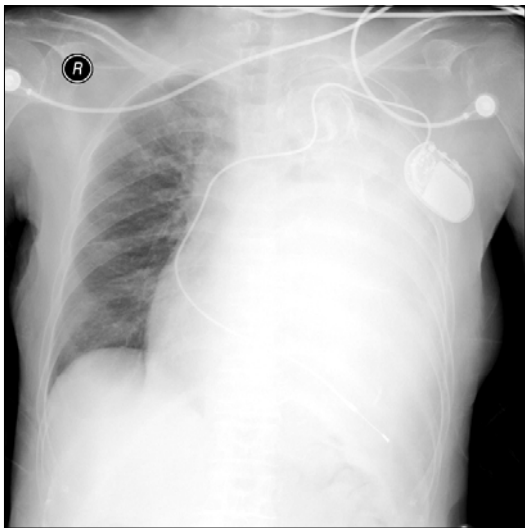


Fig. 1. Chest X-ray prior to chest drain insertion. Dense opacification of the left hemithorax without mediastinal shifting is shown. The tip of the pacemaker lead in the right ventricle was found at the far left of the hemithorax and the heart silhouette is not clearly visible.

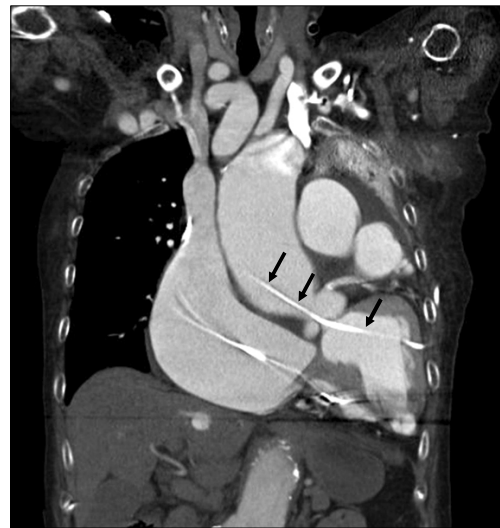

Fig. 2. Computed tomogram of the chest. Both atria and great arteries were dilated and displaced to the left hemithorax with atelectasis of the left lung. The catheter tip was placed in the ascending aorta through the aortic valve and left ventricular cavity (arrows).

aortic valve with the tip of the catheter located in the ascending aorta. Transthoracic echocardiography revealed mild aortic regurgitation with a small amount of pericardial effusion without hemodynamic significance.

Open mini-thoracotomy with chest tube insertion was performed under general anesthesia the next day. The previous catheter was carefully pulled out without myocardial repair. Although the removal of the catheter was successful and well tolerated by the patient, the hospital course was complicated by pneumonia and long-term mechanical ventilation. About a month after the complication, the patient died from pneumonia with septic shock.

DISCUSSION

Chest drain insertion is a commonly used invasive procedure for managing pneumothorax, and draining the pleural cavity is also performed for patients with pleural effusion and empyema [1]. It may be associated with certain complications such as infection, bleeding, and injury to the adjacent organs [2]. However, cardiac injury during chest drain placement is a very rare but catastrophic complication, ten cases of which have been reported to date. Although diverse types of heart

injury have been reported, to our knowledge, this particular case describes for the first time cardiac injury with the catheter tip placed in the ascending aorta through the left ventricular cavity.

Most cardiac injuries during the procedure were related to anatomic distortion such as post-pneumonectomy, extreme kyphoscoliosis, and cardiomegaly [3-6]. Similarly to these previous reports, our patient had marked cardiomegaly with atelectasis, which manifested as a dense opacity of the left hemithorax on chest X-ray. It was unfortunately misinterpreted as a massive pleural effusion in an emergency state. A chest drain was inserted in the chest cavity, eventually resulting in perforation of the left ventricle.

Accurate diagnosis and appropriate procedures are mandatory to avoid these fatal complications. The chest X-ray is the most important, widely used, and time saving means to evaluate pleural effusion. However, it is not specific, and many other conditions can mimic pleural effusion. Furthermore, interpretation of a chest X-ray in cases of suspected pleural effusion is relatively complicated, and it has been reported that the discordance rate between radiologist and emergency department physicians is relatively high and can influence clinical outcomes [7]. Therefore, emergency department

physicians should be aware of the possibility of misinterpretation. Especially in cases in which the chest X-ray is used to make clinical decisions, such as chest tube insertion as in our case, meticulous attention is needed.

This report emphasizes that delineating the locations of vital organs in the thorax must be confirmed prior to drain insertion. If anatomical orientation is hampered, ultrasound or CT should be used during or prior to chest drain placement. Although chest drainage generally has a low complication rate, the procedure can be guided with fluoroscopy, ultrasound, or CT to place the catheter accurately and to reduce the complication rate [8]. Therefore, it is recommended that image guidance be used if the effusion is very small or initial aspiration fails [1]. However, it should also be taken into consideration that imaging guidance can raise medical costs and is limited for everyday use.

In conclusion, considering the possibility of underreporting, cardiac injury from chest drain insertion might not be very infrequent with certain conditions, and if the anatomical orientation is not established before the drain insertion, more complex imaging than a chest X-ray is needed to prevent life-threatening complications and image-guided chest tube insertion can make the procedure safer.

CONFLICT OF INTEREST

No potential conflict of interest relevant to this article was

reported.

REFERENCES

1. Laws D, Neville E, Duffy J; Pleural Diseases Group, Standards of Care Committee, British Thoracic Society. *BTS guidelines for the insertion of a chest drain*. Thorax 2003;58 Suppl 2:ii53-9.
2. Collop NA, Kim S, Sahn SA. *Analysis of tube thoracostomy performed by pulmonologists at a teaching hospital*. Chest 1997;112:709-13.
3. Asopa S, Iyenger S, Lloyd CT, Brown I, Barlow CW. *Accidental perforation of the left ventricle with a Bonanno catheter*. J Thorac Cardiovasc Surg 2009;137:1023-4.
4. Goltz JP, Gorski A, Bohler J, Kickuth R, Hahn D, Ritter CO. *Iatrogenic perforation of the left heart during placement of a chest drain*. Diagn Interv Radiol 2011;17:229-31.
5. Kopec SE, Conlan AA, Irwin RS. *Perforation of the right ventricle: a complication of blind placement of a chest tube into the postpneumonectomy space*. Chest 1998;114:1213-5.
6. Meisel S, Ram Z, Priel I, Nass D, Lieberman P. *Another complication of thoracostomy: perforation of the right atrium*. Chest 1990;98:772-3.
7. Al aseri Z. *Accuracy of chest radiograph interpretation by emergency physicians*. Emerg Radiol 2009;16:111-4.
8. Klein JS, Schultz S, Heffner JE. *Interventional radiology of the chest: image-guided percutaneous drainage of pleural effusions, lung abscess, and pneumothorax*. AJR Am J Roentgenol 1995;164:581-8.