

Conduits for Coronary Bypass: Arteries Other Than the Internal Thoracic Artery's

Hendrick B Barner, M.D.

This is the third in a series on coronary artery bypass which reviews three alternative arterial conduits. The radial artery has become the most widely used of the three and accumulating experience demonstrates better patency at 10 years versus saphenous vein. Drawbacks are a long incision on the forearm, the propensity for spasm and persistent sensory disturbance in about 10%. The first is answered by endoscopic harvest which may yield a shorter conduit but reduces sensory nerve injury. Spasm is managed pharmacologically and by less harvest trauma. The gastroepiploic artery is used *in situ* and free and although the abdominal cavity is entered complications are minimal and patency compares favorably with the radial artery. Use of the inferior epigastric artery remains minimal and its similar length often requires composite use but limited patency data are supportive. Other arteries have had rare use and this is unlikely to change because the three presented here have significant advantages and acceptance.

Key words: 1. Coronary artery grafting
2. Radial artery
3. Gastroepiploic artery
4. Inferior epigastric artery

INTRODUCTION

As coronary artery bypass (CAB) was expanding in the 1970's, there were occasional instances in which the saphenous vein (SV) was unavailable and the internal thoracic artery (ITA) was not widely accepted and surgeons were exploring for other potential conduits. The radial artery (RA) was first used in Paris but patency was so poor by one year that it was abandoned [1-3]. It was resurrected concomitant with the introduction of the right gastroepiploic artery (GEA) in the late 1980's [4]. Use of the RA expanded more rapidly and widely than that of the GEA but the latter has enjoyed a late surge as harvesting technique was modified, the effects

of competitive coronary flow on patency were recognized and long term patency improved. The inferior epigastric artery (IEA) was also introduced in that era but was limited by short length and the need for an abdominal incision, even though extraperitoneal. After initial enthusiasm it has been infrequently employed.

RADIAL ARTERY

Carpentier introduced the RA and then reintroduced it on the basis that the calcium blocker, diltiazem, was necessary to treat conduit spasm which was thought to be responsible for poor patency [1-4]. Today many do not use diltiazem either

Division of Cardiothoracic Surgery, St. Louis University Hospital

Received: April 30, 2013, Revised: May 6, 2013, Accepted: May 6, 2013

Corresponding author: Hendrick B Barner, Division of Cardiothoracic Surgery, St. Louis University Hospital, 3635 Vista Ave, St. Louis, MO 63110, USA

(Tel) 1-314-577-8359 (Fax) 1-314-577-8315 (Email) hbarner@slu.edu

© The Korean Society for Thoracic and Cardiovascular Surgery. 2013. All right reserved.

© This is an open access article distributed under the terms of the Creative Commons Attribution Non-Commercial License (<http://creativecommons.org/licenses/by-nc/3.0>) which permits unrestricted non-commercial use, distribution, and reproduction in any medium, provided the original work is properly cited.

intraoperatively or long term. Initially RA spasm was managed intraoperatively by dilating the spastic graft with probes and/or hydrostatically which likely destroyed or functionally impaired the endothelium with loss of nitric oxide (NO) synthesis. In defense of these practices it must be recognized: that the role of the endothelium in vasomotion was not understood in the 1970's; that the media of the RA is more massive than that of the ITA's and the spasm more intense; and that the role of NO was not recognized until the 1980's. Surgeons gradually improved their techniques of conduit harvest, adapted pharmacologic treatment of spasm during and after harvest, and abandoned practices which were injurious to the endothelium as the importance of this organ was understood. Thus, the role of NO release at a basal level to maintain a physiologic lumen and which is modulated by shear stress to acutely increase or decrease diameter 10% to 15% and result in vessel remodeling when the change from baseline becomes chronic is now evident.

1) Radial artery harvest

There was initial concern that RA harvest could result in hand ischemia which may occur when the deep palmar arch, which links the RA with the ulnar artery, is not well developed. For this reason some surgeons will not harvest the RA from the dominant arm, a practice we have not adhered to. Allen's test was devised to assess the ability of the ulnar artery to adequately supply the hand without the RA which it fails to do in about 5%. Both arteries are compressed at the wrist using three digits to compress a long segment of distal RA which could provide a collateral branch which might provide a falsely negative test. The patient is told to make a tight fist and after 60 seconds the ulnar artery is released while the RA remains occluded. The seconds to capillary re-filling of the palm and digits, particularly the thumb which is farthest from the ulnar artery are counted. At the beginning we used five seconds as the cut off but this was quickly increased to 10 seconds and later to 12. If the result is equivocal or even 15 seconds the test is repeated and 50% of the time it will be clearly negative. In the first 1,000 patients bilateral Allen testing revealed that of those with a positive test it was bilaterally positive in one-half which precluded RA harvest. In a personal experience with 1,360 RA harvests

there has been no hand ischemia.

A long incision over the RA from the wrist crease to the brachial artery bifurcation has a small ulnar deviation in its middle third to accommodate the brachioradialis muscle and the sensory nerve of the same name which lies just superficial to the fascia. No touch technique with regard to the RA because of its propensity for spasm is important. Starting in the proximal distal third a pedicle of fatty-areolar tissue, vein and artery is developed using sharp and blunt dissection and low current (range, 15 to 20 watts) electrocautery and encircled with a tape (silastic, rubber, or cotton). Initially we utilized usual dissection with rare use of cautery because of fear of encouraging spasm and branches were controlled with clips. Later we adapted ultrasound (Harmonic Scalpel) for dissection and branch control without clipping which was expedient [5]. Subsequently coagulating forceps were tried and we learned that dissection with the nonactivating blade of the open forceps was feasible and faster and that branch bleeding became nearly extinct. With gentle traction the pedicle is developed in both directions, to the wrist crease distally and to the brachial bifurcation proximally. If maximal length is desired the ulnar artery should be identified and appropriate venous branches divided. Distally the dissection becomes more tedious and should move close to the artery to avoid other structures. A suture ligature is our preferred method for control of the proximal and distal vessel and heparin is not given prior to this. The artery is placed in room temperature, heparinized blood with papaverine, 0.5 mg/mL. Hemostasis is obtained and the incision closed with the deepest layer being the subcutaneous fascia, and not the muscle fascia. Closure of the latter may lead to forearm muscle necrosis which has been reported in a few cases of late contracture of the hand. This appears to be secondary to a compartment syndrome as this closure results in the compartment being smaller than normal and obligatory postoperative edema and/or bleeding leads to increasing pressure and ischemic muscle necrosis. About 1% of patients have required reopening of the incision after protamine but before leaving the operating room to achieve hemostasis. In the intensive care area less than another 1% have required removal of some cutaneous sutures for dermal and/or subcutaneous bleeding. After a wound bandage and a gauze wrap the forearm is wrapped with an elastic

bandage and tucked at the patients side or sometimes left on the arm board at 90 degrees or less abduction.

We frequently employ the RA as a T-graft which requires maximum length. The RA is measured *in situ* prior to excision and in the male is 20 to 24 cm and 2 cm less in the female. It is helpful for the surgeon to have this information in operative planning which when combined with experience allows prediction of adequate conduit length in most situations. Based on the aorta the RA will reach any point on the heart which is not always true of the other arterial conduits. Sequential anastomosis may require additional length depending on anatomy and disease which determine precise anastomotic sites and routing.

Endoscopic harvest has been reported by few with excellent patency [6]. However reported injury to the SV with reduced patency raises concern as does the propensity for spasm although seemingly well managed pharmacologically. Whether the full length of the RA can be readily harvested in this way has not been determined. Perhaps most important is operator competence in obtaining a conduit free of injury which has been a problem with endoscopic SV harvest [7].

2) Harvest related complications

Hand ischemia has not been recognized in our experience and less than five case reports exist. If a properly executed Allen test has been negative, this should not occur unless there is an untoward operative event. Forearm muscle necrosis has been a similar rare event and as indicated above should not occur with appropriate wound closure and appreciation that severe forearm pain is the sign of muscle ischemia and requires prompt surgical decompression.

In 10% or less there may be surgical injury of the superficial branch of the radial nerve which results in sensory impairment at the base of the thenar eminence and may also involve the dorsum of the proximal thumb. This nerve arises from the radial nerve in its middle third and has a course parallel to and toward the radial side of the RA until immediately proximal to the flexor retinaculum where it crosses in front of the RA and is most vulnerable. The tactile loss does not impair function because the palmar surfaces of the hand and digits are not involved [8]. Our incidence may be higher because of the need for maximum length to facilitate

T-grafting.

Equally common or more so is surgical trauma to the brachioradialis nerve which is sensory to the skin of the mid-dorsal forearm toward the radial side. This nerve courses from the mid radial nerve along the border of the brachioradialis muscle to a deep subcutaneous position; it can be avoided by a middle third curve in the skin incision toward the ulnar side and keeping the dissection toward the ulnar side as the brachioradialis muscle is dissected to expose the RA.

Exceedingly rare is the diminutive RA which is replaced by a large median artery lying adjacent to the median nerve which would be vulnerable to harvest related injury. The median nerve is anatomically remote to the RA and we have not recognized harvest related injury which could possibly occur as a manifestation of an acute carpal tunnel syndrome secondary to induced edema/hemorrhage if the RA is mobilized to the flexor retinaculum. Not strictly a complication of RA harvest but nevertheless seen after cardiac operations is sensory loss in the ulnar nerve distribution as a result of pressure on the nerve at the olecranon which may result from improper positioning and/or padding in the operating room or subsequently and is almost always reversible.

3) Radial artery grafting

As an aorto-coronary graft the proximal anastomosis is frequently made after the distal but some reverse this sequence. Either way the graft is filled with heparinized blood containing papaverine 0.5 mg/mL and a soft vascular bulldog placed at the end so that the drug remains in the vessel as long as possible. The length advantage of the RA over the other arterial conduits permits grafting any distal site on the heart. It is commonly combined with other arterial conduits in which case the internal thoracic arteries would be placed to the most important targets and if only the left ITA is grafted to the anterior descending artery the RA would go to the next ranking artery. The RA would be preferentially selected over the SV unless the target was the right coronary and did not have a 90% stenosis in which case competitive coronary flow would significantly diminish RA patency.

The end-to-side coronary anastomosis is made as described for the ITA with a 2.5 to 5.0 mm coronary incision at the

healthiest site and a 1.5 to 3 mm incision in the end of the RA. The suture line is initiated at the heel of the anastomosis and continued in either direction to complete the anastomosis or both sutures may be used. The unconnected aortocoronary graft is gently pressurized with heparinized blood/papaverine (0.5 mg/mL) solution to check anastomotic hemostasis and a soft bulldog clamp placed at the proximal end.

Side-to-side anastomosis can be made before or after the end anastomosis. It is optimal to fashion a parallel anastomosis but a crossing (right angle) anastomosis is feasible if the RA is 2.5 mm or larger and the surgeon is experienced with parallel anastomosis. A 1.5 to 2.5 mm longitudinal incision in the coronary is mated with a slightly shorter incision in the RA. Using parachute technique the suture begins at the coronary heel and continues bidirectionally until 60% is completed and the suture tightened before completion of the anastomosis. Adventitial-epicardial (tacking) sutures of 6-0 polypropylene are placed to prevent shifting of the graft with angulation, which might restrict flow, before it is fixed by fibrin formation. Appropriate position of the anastomoses and the graft may allow a relatively straight course between anastomoses and avoid the use of tacking sutures. This is facilitated by crossing anastomosis but even with it there may be a curve, S-curve or occasionally 180 degree loop which requires greater length to achieve and also more tacking sutures.

Composite grafting with the RA was introduced by Calafiore who used it as a Y-graft from the left ITA, usually for the lateral wall and without sequential grafting, and has reported excellent long term results [9,10]. To graft additional targets he created secondary and, if necessary, tertiary Y-grafts using the RA, IEA, GEA, or right ITA. Tector practiced T-grafting which differed from the Y-graft of Calafiore by use of the right ITA to graft multiple arteries in the lateral and inferior walls which we have adapted for the RA (Fig. 1) [11,12]. This technique requires sequential grafting whereas the Y-graft supplied multiple targets via additional Y-grafts.

Most prefer to use the RA as an aortocoronary graft and not a composite. A primary reason for this preference is concern that the composite graft may not supply adequate flow to such a large branched system and hypoperfusion could occur, particularly at times of higher flow demand. However

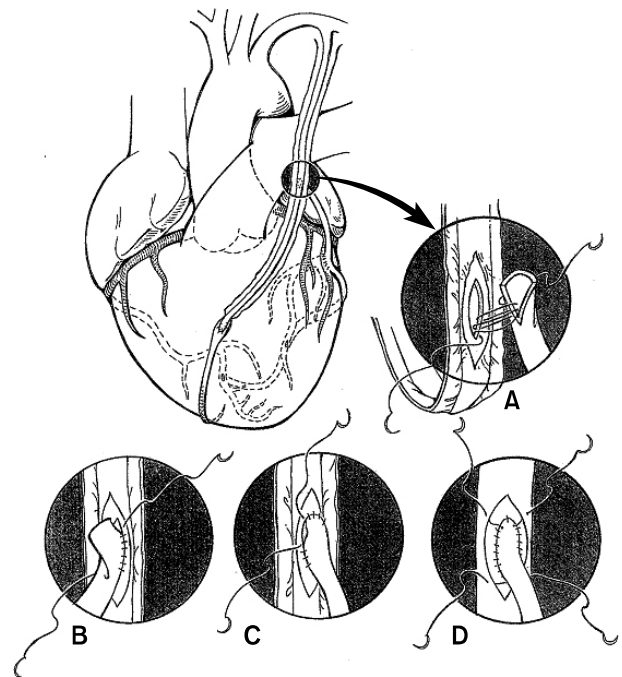


Fig. 1. The anastomosis of the radial artery (RA) to the posterior aspect (smooth side) of the left internal thoracic artery (ITA) is best accomplished before cannulation for bypass, although some wait until after completion of distal anastomosis(es), and lies at the approximate level of the left atrial appendage at the point where the ITA enters the pericardial space and is measured and marked on the pedicle. The pedicle is rotated 180 degrees and may be suspended by two sutures in the midline to avoid transmitted cardiac motion. (A) A 5 mm incision in the ITA is matched by a shorter one in the RA and suturing initiated at the heel with 7-0 polypropylene. (B) The far side of the anastomosis is completed through the toe and (C) the near side completed with one or both suture limbs. (D) Tacking sutures of the same material are placed from pedicle tissue through adventitia of the RA in a triangular fashion to relieve stress at the toe and heel where we experienced leaks in the first 50 patients but none subsequently. The proximal bull dog clamp is released, having given heparin before the anastomosis, to check hemostasis and the grafts filled with blood containing papaverine (0.5 mg/mL) and allowed to dilate with arterial pressure. After cannulation and before initiation of bypass the grafts are checked visually for dilation and by observing free flow. If these are not adequate the grafts are refilled with papaverine. The "T-anastomosis was described by Tector et al. [11] and presumably describes the configuration of the conduits when definitively positioned (Reproduced from Edmunds LH. Cardiac surgery in the adult. New York: McGraw-Hill; 1997, with permission from the McGraw-Hill Companies) [13].

there are data which support the hemodynamic adequacy of composite grafts which are presented below. Intraoperative and late postoperative hemodynamic studies suggest that the T-graft, with either ITA or RA, has resting flow and coronary flow reserve which is within the normal range which is the result of physiologic vasodilation and conduit remodeling [14-20]. The complexity of the T-graft versus a Y-graft is another reason why it is not favored.

4) Radial artery graft flows

The RA is of greater diameter, but longer, than the ITA and should have adequate flow capacity except for the issue of conduit spasm which has plagued it since its initial use when harvest induced spasm was treated with mechanical dilation using probes or hydrostatic force which damaged the endothelium. Reintroduction of the RA was associated with intraoperative use of diltiazem to treat/prevent spasm and avoid mechanical dilation which preserved functional endothelium with basal and flow stimulated elaboration of NO [14,15]. It was thought by many that diltiazem was critical to the success of the RA and it was continued long term. We believed that diltiazem was incidental to atraumatic harvest with preservation of functional endothelium and have not used it at any time but we treat harvest spasm with intraluminal papaverine diluted in blood which is done with all arterial conduits [12]. Intraoperative conduit flow is routinely measured and the RA always provides flow comparable to an ITA graft but when there are multiple targets, usually with a T-graft configuration, there is the possibility of inadequate flow which however has rarely been documented [16]. Intraoperative flow has been of appropriate magnitude (left ITA limb, 60 ± 43 mL/min and RA limb, 88 ± 49 mL/min) in the T-grafted RA and compared favorably with aortocoronary RA flow [17]. Coronary flow reserve has been measured in RA T-grafts one week and six months postoperatively and increased from 1.8 to 2.5 [18]. Similarly there was adequate flow at rest and with maximal hyperemia throughout two years of serial study [19]. Other studies of flow adequacy in composite RA grafts have not revealed evidence of myocardial ischemia at rest or with stress [20,21]. Initial physiologic vasodilation and subsequent conduit remodeling achieve

definitive flow adequacy of the RA composite graft in which the limiting link is actually the proximal left ITA which must supply both conduits and theoretically the entire myocardium if the right coronary and left main were occluded [22]. This of course has been a major consideration of the T-graft composite configuration but with 20 years of experience this potential limitation has not surfaced as a reality assuming no technical or procedural errors or mishaps.

5) RA graft patency

Patency will never compare with that of the left ITA to the left anterior descending (LAD) artery which is the best target and will almost always be grafted with the best conduit but if the RA were used I believe at this time that it would compare favorably if fractional flow criteria for revascularization (<0.8) were met. It has been common to compare RA patency with that of the SV because after the ITA's the vein and the RA are frequently the options. A meta-analysis conclusively demonstrates that intermediate and long term patency of the RA is better [23]. Patency for aortocoronary or composite RA grafts has been similar [24-26]. Numerous reports indicate that competitive coronary flow has a significant influence on arterial conduit patency, particularly for the RA and right coronary [27]. The weight of the evidence indicates that the coronary stenosis should be at least 70% for left coronary vessels and 90% for the right coronary, and probably the left main although there are not specific data for the latter [28]. If the right coronary diameter is small, that is similar to the LAD and/or circumflex branches, then grafting with a 70% to 90% stenosis may be appropriate. The apparent reason for reduced patency in the right system is the frequently greater diameter which translates into a much larger residual lumen for any per cent stenosis such that a 80% stenosis in a 5 mm vessel leaves a residual lumen of 0.88 mm² compared with a lumen of 1.76 mm² in a 1.5 mm vessel and 3.1 mm² in a 2.0 mm vessel [29]. Overall ten year patency for free or composite RA grafts is 63% to 77% [25,29,30]. When the indication for angiography was clinical presentation patency was 63% to 74% [25,29]. It is likely that our patency was reduced by grafting vessels with a stenosis of 50% or more with the RA until 2001 [25].

6) Outcomes with the radial artery

Patient satisfaction after RA harvest has been more than satisfactory [31]. Wound complications have been few and mild except for the catastrophic problem of forearm flexor muscle necrosis which I believe is a compartment syndrome created by closure of the muscle fascia and is avoided by closing only the deep subcutaneous fascia [32]. Sensory disturbance persists in 8% to 10% but usually involves the dorsum of the thumb or mid-distal forearm related to the superficial branch of the radial nerve or a branch of the brachioradialis nerve and rarely involves a motor nerve [8]. Ulnar nerve sensory disturbance is secondary to pressure near the elbow and is not specific to RA harvest. Endoscopic harvest has provided satisfactory RA performance but no advantage other than cosmetic and concerns about conduit quality remain [7].

Harvest of the RA leaves the forearm dependent on the ulnar artery for most of its blood supply and one report raised concerns about increased hemodynamic stress resulting in accelerated atherosclerosis [33]. Subsequent observations have not found evidence to support this contention but rather appropriate ulnar remodeling, resting flow increase and preservation of flow mediated vasodilation, an indicator of endothelial health [34,35].

Survival benefit with bilateral ITA grafting over left ITA grafting is accepted by most as is their superior patency although the RA grafted to the LAD or the lateral wall has patency which is non-inferior to the right ITA whether *in situ* or as a composite graft. The RA then is supplemental to the two ITA grafts and it is appropriate to consider all arterial revascularization using these three conduits.

There are few long term studies and none are randomized but one report with propensity score analysis and 15 year follow-up of bilateral ITA/RA (n=147) and left ITA/RA (n=169) had greater survival (84% and 78%, $p < 0.001$) versus left ITA/SV [36]. In multivariate analysis multiple arterial grafts remained a strong independent predictor of survival (hazard ratio, 0.79; 95% confidence interval, 0.66 to 0.94; $p = 0.007$) [37]. A retrospective, nonrandomized, propensity matched study compared left ITA/SV with left ITA/RA and found significantly improved survival at 10 years for males and fe-

males with RA use but survival benefit was greater in males [38]. Females received survival benefit from RA over SV at five years in a retrospective, propensity matched analysis [39]. Elderly patients (75±4 years) propensity matched and receiving left ITA/SV or left ITA/RA had improved survival with RA (50.5% vs. 70.9%) at 10 years [40]. Clinical outcomes and patency were nearly identical for the RA or right ITA used as a Y-graft from the left ITA to the lateral wall [10].

All arterial grafting in 400 patients (95% with RA) done off-pump and with “no-touch” aorta achieved lower rates of major adverse cardiovascular or cerebrovascular events and better survival at four years than in the synergy between percutaneous coronary intervention with taxus and cardiac surgery (SYNTAX) [41]. This important report by SYNTAX participants reflects expertise and benefit of all arterial which has proven elusive. All arterial with two conduits (left ITA/RA) has been safe with one month mortality and sternal infection rates of $< 1\%$ [42].

RIGHT GASTROEPIPLOIC ARTERY

Independently introduced in 1987, at two sites, the GEA enjoyed a gradual expansion of its popularity which has not approached that of the ITA or RA but has been greater in Asia than elsewhere [43,44]. It has been primarily used *in situ* with a recent trending toward use as a free graft based on the aorta or as a composite from another arterial graft. Using it *in situ* and combining it with two *in situ* ITA grafts provides no touch (of the aorta), all arterial revascularization. No touch can also be achieved by using it as a composite. Free grafting arguably provides better inflow than a fourth order (coeliac > hepatic > gastroduodenal > gastroepiploic) branch and avoids traversing the diaphragm which occasionally is suboptimal.

The initial 10 year patency was no better than for SV and although this may have reflected the “learning curve,” it was also the result of competitive coronary flow particularly from a large right coronary which did not have a 90% or more stenosis. As noted above for the RA these are both muscular arteries with few elastic fibers and prone to spasm. Just as the RA to the right coronary has poor patency when there is

not a high grade stenosis the GEA is equally vulnerable and for this reason demands scrutiny of the culprit lesion.

1) Gastroepiploic artery harvest

The sternotomy incision is extended 4 to 6 cm beyond the tip of the xiphoid, through the midline fascia and some would incise the diaphragm vertically which we have found unnecessary. With minimally invasive approaches to coronary bypass the GEA may be reached with an upper midline incision. The sternal spreader may be moved inferiorly and/or an abdominal retractor is placed. Traction on the stomach and omentum will expose the mid segment of the GEA and vein. Early the GEA was harvested as a bulky pedicle with mass ligatures or oversized clips but there has been a movement away from this which reached skeletonization in 1998 [45]. This technique provides a longer conduit which is easily inspected for quality and spasm and is easier to pass through the diaphragm [46]. The branches tend to be more fragile than those of the ITA and RA. Vessel loops facilitate handling of the GEA and exposure of branches and dissection has moved on from blunt, with scissors and cautery to the Harmonic Scalpel with coagulating shears which provides more secure and expeditious branch control than does the hook tip blade which is used for ITA harvest [47]. Dissection from the mid segment is continued to the pylorus with division of several pyloric branches but taking care not to violate the pancreas beyond this point.

Dissection to the left usually reaches the short gastric vessels but depends on the length needed and also the caliber of the artery. The GEA, even with gentle handling, is always in some degree of spasm so its definitive caliber, after dilation, may be significantly greater than it appears before. At this point with the artery divided it is appropriate to check free flow which again is usually diminished because of spasm. The artery is cannulated and filled with heparinized blood and papaverine 0.5 mg/mL and also wrapped in a pad wet with saline/papaverine.

2) Gastroepiploic artery grafting

Routing is usually anterior to the stomach but may also be posterior which is only slightly shorter to the left side but longer to the LAD. It usually passes anterior to the left lobe

of the liver but may be posterior and the left lobe may be mobilized from the diaphragm if necessary. A cruciate incision is made because a linear incision will narrow with diaphragmatic contraction. The opening is positioned to allow a parallel approach to the anastomosis which is over the atrio-ventricular groove and anterior to the inferior vena cava when the posterior descending artery is the target. More precise localization may be achieved by retraction of the right side of the heart to visualize the target vessel and as the heart is lowered the course of the graft visually plotted to locate the ideal point for pericardial space entry for the GEA.

A 3 to 4 mm incision is made in the healthiest segment of the target vessel and the graft shortened if excessive but leaving sufficient length to avoid angulation at the diaphragm and allow for gastric filling. The GEA is transected and spatulated for end-to-side anastomosis which is initiated at the heel and continued to the toe on the side most difficult to access before completing the second side with one or both suture limbs. When there is a second (sequential) anastomosis the proximal anastomosis may be parallel or crossing depending on the relationship of the two targets and conduit length [12]. As with the other arterial conduits it should be secured to the epicardium with 6-0 or 7-0 polypropylene suture.

Occasionally the GEA is grafted to the LAD or to circumflex branches depending on conduit availability and length. The free graft may be a better choice or the only choice for these alternative targets if the GEA were too small or too short. Preferential free grafting is increasingly utilized and if from the aorta it is best to use a vein hood or vein patch because the GEA is usually of smaller caliber and more fragile than the other arterial grafts [12].

3) Gastroepiploic artery flow

Reports of GEA graft flow are few compared to other grafts. In essence the GEA flow rates are comparable to the others and dependent on coronary size, atherosclerotic burden, amount of viable myocardium supplied, the presence of competitive flow, and hemodynamics. Vein or GEA grafts to the right coronary had similar flow rates at rest and after injection of papaverine 10 mg into the graft when coronary stenosis was greater than 75% but if the stenosis was 50% to 75% flow in the GEA was significantly less ($p=0.001$).

Comparison of flow for vein graft and *in situ* GEA revealed no difference at rest or after injection of papaverine 10 mg into the graft when the coronary stenosis was greater than 75%; if stenosis was 50% to 75% flow was significantly less in the GEA [47]. Comparison of GEA and right ITA as composite grafts from the left ITA to the lateral wall revealed similar flow patterns at rest [47]. Intraoperative assessment of graft flow in all arterial grafting revealed no significant differences between ITA and GEA grafts but with the recognized differences in flow patterns between right and left side directed grafts [48].

4) Gastroepiploic artery graft patency

The initial report of 10 year patency of 62.5% was no better than for vein [49]. A later report indicated significantly better patency [50]. This improvement was related to skeletonization of the GEA, more vigorous treatment of harvest related spasm and selection of target arteries with more severe stenosis to reduce competitive flow. Skeletonization may be associated with less conduit injury although intuitively it might seem more likely to traumatize the artery; it does provide visualization of artery damage and if necessary rejection and also appreciation of spasm and the need for vigorous pharmacologic therapy of it. It provides a longer, larger artery which facilitates anastomosis and reduces later spasm and hypoperfusion. Many surgeons have their preference for pharmacologic management and I continue to prefer intraluminal papaverine diluted in blood (0.5 mg/mL) which will buffer the pH to a physiologic level while saline, which has no buffering capacity will damage endothelium. Additionally it is useful to wrap the skeletonized artery in a gauze sponge wet with papaverine in saline (1.0 mg/mL) which will not reach the endothelium. I rarely use perioperative vasodilators although nitroglycerin is safe if the systolic blood pressure is maintained over 100 mmHg. Nitroprusside is also appropriate if needed for pressure control. Intraoperative diltiazem, touted as necessary for long term therapy but subsequently shown to be unnecessary for RA patency, may cause hypotension, atrial arrhythmia with bradycardia and hypocontractility and I have avoided it. Vigorous dilation of the conduit at harvest is adequate and healthy endothelium will elaborate NO when flow is restored. For the 1% to 2% of patients with perioperative

graft/coronary spasm intravenous nitroglycerin and a calcium blocker such as amlodipine are appropriate [51].

Concomitant with the above has been the focus on competitive flow and the obvious but over looked fact that percent stenosis is relative to vessel size and the residual lumen diameter which controls flow. Thus 90% stenosis of a 5.0 mm artery leaves a 0.88 mm lumen which carries significant flow. The other difficulty is the limitation of visual assessment of an angiographic image which is improved by quantitative angiography but this is not always available [28]. Furthermore, complexity of the lesion, compounded by linearity or several lesions, may be impossible to appreciate angiographically/visually. Fortunately a physiologic methodology, fractional flow reserve, became available in the 1990's and is proven for determining hemodynamic significance (flow restriction) of a stenosis and appropriateness of percutaneous intervention and coronary bypass [52-54].

More recent data indicate excellent patency of 95% at one year and 80% at 10 years [55,56]. One report of 57 patients with the GEA grafted to the aorta obtained 95.7% patency at a mean of 77 months (range, 35 to 100 months) [57]. Although the authors opined that anastomosis of the GEA vein to the right atrium was in part responsible for their excellent patency there was no control group and it is more likely that improved in-flow and perhaps greater coronary stenosis, although not stated, were contributory and that if skeletonization had been used the vein anastomosis would be a nonissue. With regard to the free GEA when used as a composite Y-graft to the lateral wall its patency was equal to the right ITA (97.7% vs. 96.5%, $p=0.251$) [55].

INFERIOR EPIGASTRIC ARTERY

The IEA was first used in 1987 and reported in 1990 [58]. Chronologically this was at the time of GEA introduction and rebirth of the RA when we were searching for arterial conduits to supplement the left ITA, or both ITA's, to achieve all arterial revascularization. Like the ITA this is a bilateral structure and unlike the GEA it is harvested without entering another body cavity. In our efforts to achieve all arterial revascularization we harvested bilateral ITA and IEA grafts in 17 patients two of whom developed abdominal wall necrosis

[59]. Our total experience with IEA grafting was 108 patients from 1990 to 1992 with 91 having one IEA taken and one (19%) or two (81%) ITA's [60]. No patient with bilateral ITA and single IEA mobilization developed abdominal wall ischemia. To my knowledge others have not reported this complication. I have not revisited the IEA, not because I disapprove of it, but because my interest shifted to the RA at that time which was more attractive by virtue of greater consistency in length and diameter as well as simultaneous harvest with the ITA and by a surgical assistant. Other than the experience of Puig and that in Belgium and Montreal the use of this conduit has been small [61-63].

1) Inferior epigastric artery harvesting

A midline incision below the umbilicus to symphysis pubis will access both IEA's but if only one is needed an incision centered over the rectus muscle is more convenient. The rectus sheath is opened longitudinally in its midpoint or a bit lateral and the muscle dissected from either medial or lateral with lateral preferable as the artery approaches the sheath from a posterolateral course. Usually the artery lies outside the muscle against the posterior wall of the sheath but may enter the muscle which renders dissection difficult. It may also bifurcate in which case it becomes too small to serve as a graft. Mobilization continues to the umbilicus and the artery may then be divided and proximal dissection continued as the artery leaves the sheath and enters preperitoneal fat and courses to its origin from the external iliac artery proximal to the inguinal ligament. The most proximal portion may be atherosclerotic in 20% to 25% and occasionally with calcification. The usual length is 10 to 15 cm but shortened by bifurcation or intramuscular position. The artery is filled with heparinized blood containing papaverine 0.5 mg/mL and stored in the blood or saline solution at room temperature. Topical papaverine in saline may be sprayed on the artery during harvest.

Wound hematoma has occurred so that closure is best delayed until heparin is reversed and closed suction drainage may be useful [61,63]. Wound infection is rare, hematoma may require drainage and incisional hernia has been reported [62,63]. The role of the ITA's and also IEA's as collateral to the lower extremities in patients with severe peripheral vas-

cular disease has long been recognized and precludes harvest. The contribution of the IEA's to sternal perfusion after bilateral ITA harvest has been noted [64].

2) Inferior epigastric artery grafting

Initial use of the IEA was as an aortocoronary graft. The proximal anastomosis is problematic because of the usual smaller diameter so that anastomosis via an intermediary (vein hood, vein, or pericardial patch) is useful. Use is limited by length which is adequate for the LAD, marginal, and sometimes the posterior descending artery. Thus the contribution by Calafiore is valuable as it solves the proximal anastomosis problem and also length issues by adding approximately 10 cm to the effective length of the IEA [9,65]. Another option is end-to-end anastomosis to an *in situ* ITA to reach more distal targets or two IEA's may be linked to create a longer graft.

3) Inferior epigastric artery patency

Buche et al. [65] reported 92% (44/48) patency at 8.5 months and 97% (28/29) at 25 months. Puig et al. [61] achieved 87.5% (14/16) patency at a mean of 81.2 months. Composite grafting based on the left ITA achieved 100% (25/25) patency at greater than 12 months postoperatively [66]. Flow data are lacking.

SELDOM USED ARTERIAL GRAFTS

In addition to the arteries discussed with which there is a sizable experience there are arteries from the forearm, chest wall, abdomen, and thigh which have been infrequently utilized for myocardial revascularization and often by only one group or several groups with only a few cases.

1) Splenic artery

Historically of interest because it was reported in 1973 it has been used both *in situ* and free [67,68]. Harvest is difficult with the risk of pancreatic injury and limitations of length, friability of intima and lacking follow-up [68]. It has been used in reoperations, for off-pump and as a composite [68].

2) Ulnar artery

One report of 25 cases over six years from a group with extensive experience using the RA provides a measured and mature viewpoint of the ulnar artery (UA) [69]. Although the RA may be removed in most patients without creating hand ischemia there are a few in whom this is not feasible and for them the UA is an option. Harvest is more difficult than for the RA in part because of the adjacent ulnar nerve and 1/25 patients had persistent nerve ischemia so that harvesting is best done by a surgeon [69]. Although the authors describe 25 patients having UA harvest only 15/18 of harvested UA's were satisfactory with an average length of 15 cm and employed in the same fashion as the RA [69]. The thick muscular wall requires spasmolytic therapy as for the RA. Although clinical results have been good there are neither long-term clinical data nor angiographic follow-up supporting the UA and the authors recommend its use only in the absence of other arterial conduits [69].

3) Lateral circumflex femoral artery

The descending branch of the lateral circumflex femoral artery descends posterolateral to the rectus femoris and along the anterior border of the vastus lateralis muscle and eventually anastomoses with the lateral superior genicular branch of the popliteal artery which provides collateral circulation to the leg in instances of femoropopliteal artery stenosis or occlusion and precludes its harvesting in this circumstance. It is employed as other free arterial grafts of moderate length (range, 10 to 17 cm) and is a muscular artery requiring smooth muscle relaxants. In 147 patients the one year patency was 97.5% and at three years it was 93.7% in 48 patients [70]. One confirmatory experience found 85% patency in 21 grafts early postoperatively [71].

4) Subscapular thoracodorsal artery

The primary experience with this conduit was from Mills who used it in five cases of reoperative coronary bypass via a left thoracotomy [72]. In two case reports a sternotomy was used for reoperative CAB in one and minimally invasive direct CAB for an initial operation in the other [72]. If a left thoracotomy is not used then the optimal approach to the

subscapular thoracodorsal artery (STA) is via an axillary incision [73]. Mills anastomosed the STA to the descending aorta which may require a pericardial patch; otherwise composite grafting is necessary for this short graft (range, 10 to 12 cm). Three of Mills' patient had angiographic follow-up at one week to four years with patent grafts.

5) Inferior mesenteric artery

The reported experience with this conduit comprises four cases with good clinical outcomes in all and angiography at 5 and 31 months in 2/4 revealing patent grafts [74,75]. I would have no enthusiasm for inferior mesenteric artery harvest because of fear of colonic ischemia and the need for prior angiography to assure good patency of the superior mesenteric artery as well as freedom from prior laparotomy.

6) Intercostal artery

There has not been use of this artery for coronary bypass although a few have speculated about this possibility. It has been used *in situ* to revascularize the bronchial artery in lung transplantation.

CONCLUSION

The RA has become the most common arterial conduit after the ITA's and in some instances may be preferable to the right ITA. One fairly obvious situation is the morbidly obese diabetic where the incidence of sternal infection remains elevated despite the lowered risk of infection in non-morbidly diabetics having skeletonized ITA harvest. It is also appropriate in the presence of severe peripheral vascular disease where healing of leg incisions may be compromised or there is the need to utilize the vein for vascular reconstruction. The accumulating data indicate that RA patency is better than for vein grafts but this is not true for the right coronary without a severe (90%) stenosis in which the vein is the graft of choice.

Limited data suggest that GEA patency is equal to that of the RA and perhaps even better. The RA is advantaged by concomitant harvest (with ITA) and by a surgical assistant and having more consistent length and diameter. The data support utilization of the GEA and some would select it over

the RA including greater use as a free graft. The IEA was used more often in the first decade and has little use at this time but appears to have acceptable patency from the aorta or as a composite graft. Application of the other arterial conduits is largely anecdotal but occasionally helpful.

CONFLICT OF INTEREST

No potential conflict of interest relevant to this article was reported.

REFERENCES

1. Carpentier A, Guermontprez JL, Deloche A, Frechette C, DuBost C. *The aorta-to-coronary radial artery bypass graft. A technique avoiding pathological changes in grafts.* Ann Thorac Surg 1973;16:111-21.
2. Curtis JJ, Stoney WS, Alford WC Jr, Burrus GR, Thomas CS Jr. *Intimal hyperplasia: a cause of radial artery aorto-coronary bypass graft failure.* Ann Thorac Surg 1975;20:628-35.
3. Fisk RL, Brooks CH, Callaghan JC, Dvorkin J. *Experience with the radial artery graft for coronary artery bypass.* Ann Thorac Surg 1976;21:513-8.
4. Acar C, Jebara VA, Portoghese M, et al. *Revival of the radial artery for coronary artery bypass grafting.* Ann Thorac Surg 1992;54:652-9.
5. Ronan JW, Perry LA, Barner HB, Sundt TM 3rd. *Radial artery harvest: comparison of ultrasonic dissection with standard technique.* Ann Thorac Surg 2000;69:113-4.
6. Bleiziffer S, Hettich I, Eisenhauer B, et al. *Patency rates of endoscopically harvested radial arteries one year after coronary artery bypass grafting.* J Thorac Cardiovasc Surg 2007;134:649-56.
7. Lopes RD, Hafley GE, Allen KB, et al. *Endoscopic versus open vein-graft harvesting in coronary-artery bypass surgery.* N Engl J Med 2009;361:235-44.
8. Moon MR, Barner HB, Bailey MS, et al. *Long-term neurologic hand complications after radial artery harvesting using conventional cold and harmonic scalpel techniques.* Ann Thorac Surg 2004;78:535-8.
9. Calafiore AM, Di Giammarco G, Luciani N, Maddestra N, Di Nardo E, Angelini R. *Composite arterial conduits for a wider arterial myocardial revascularization.* Ann Thorac Surg 1994;58:185-90.
10. Calafiore AM, Di Mauro M, D'Alessandro S, et al. *Revascularization of the lateral wall: long-term angiographic and clinical results of radial artery versus right internal thoracic artery grafting.* J Thorac Cardiovasc Surg 2002;123:225-31.
11. Tector AJ, Amundsen S, Schmahl TM, Kress DC, Peter M. *Total revascularization with T grafts.* Ann Thorac Surg 1994;57:33-8.
12. Barner HB, Farkas EA. *Conduits for coronary bypass: vein grafts.* Korean J Thorac Cardiovasc Surg 2012;45:275-86.
13. Barner HB. *Techniques of myocardial revascularization.* In: Edmunds LH Jr, editor. *Cardiac surgery in the adult.* New York: McGraw-Hill; 1997. p. 481-534.
14. He GW, Yang CQ. *Radial artery has higher receptor-mediated contractility but similar endothelial function compared with mammary artery.* Ann Thorac Surg 1997;63:1346-52.
15. Shapira OM, Xu A, Aldea GS, Vita JA, Shemin RJ, Keaney JF Jr. *Enhanced nitric oxide-mediated vascular relaxation in radial artery compared with internal mammary artery or saphenous vein.* Circulation 1999;100(19 Suppl):II322-7.
16. Sakaguchi G, Tadamura E, Ohnaka M, Tambara K, Nishimura K, Komeda M. *Composite arterial Y graft has less coronary flow reserve than independent grafts.* Ann Thorac Surg 2002;74:493-6.
17. Affleck DG, Barner HB, Bailey MS, et al. *Flow dynamics of the internal thoracic and radial artery T-graft.* Ann Thorac Surg 2004;78:1290-4.
18. Wendler O, Hennen B, Markwirth T, et al. *T grafts with the right internal thoracic artery to left internal thoracic artery versus the left internal thoracic artery and radial artery: flow dynamics in the internal thoracic artery main stem.* J Thorac Cardiovasc Surg 1999;118:841-8.
19. Mannacio V, Di Tommaso L, De Amicis V, Musumeci F, Stassano P. *Serial evaluation of flow in single or arterial Y-grafts to the left coronary artery.* Ann Thorac Surg 2011;92:1712-8.
20. Gatti G, Bentini C, Maffei G, et al. *Noninvasive dynamic assessment with transthoracic echocardiography of a composite arterial Y-graft achieving complete myocardial revascularization.* Ann Thorac Surg 2005;79:1217-24.
21. Onorati F, Rubino AS, Cristodoro L, et al. *In vivo functional flowmetric behavior of the radial artery graft: is the composite Y-graft configuration advantageous over conventional aorta-coronary bypass?* J Thorac Cardiovasc Surg 2010;140:292-7.e2.
22. Barner HB. *Remodeling of arterial conduits in coronary grafting.* Ann Thorac Surg 2002;73:1341-5.
23. Athanasiou T, Saso S, Rao C, et al. *Radial artery versus saphenous vein conduits for coronary artery bypass surgery: forty years of competition--which conduit offers better patency? A systematic review and meta-analysis.* Eur J Cardiothorac Surg 2011;40:208-20.
24. Maniar HS, Barner HB, Bailey MS, et al. *Radial artery patency: are aortocoronary conduits superior to composite grafting?* Ann Thorac Surg 2003;76:1498-503.
25. Barner HB, Bailey M, Guthrie TJ, et al. *Radial artery free and T graft patency as coronary artery bypass conduit over*

- a 15-year period. *Circulation* 2012;126(11 Suppl 1):S140-4.
26. Jung SH, Song H, Choo SJ, et al. *Comparison of radial artery patency according to proximal anastomosis site: direct aorta to radial artery anastomosis is superior to radial artery composite grafting.* *J Thorac Cardiovasc Surg* 2009;138:76-83.
 27. Sabik JF 3rd, Blackstone EH. *Coronary artery bypass graft patency and competitive flow.* *J Am Coll Cardiol* 2008;51:126-8.
 28. Glineur D, D'hoore W, de Kerchove L, et al. *Angiographic predictors of 3-year patency of bypass grafts implanted on the right coronary artery system: a prospective randomized comparison of gastroepiploic artery, saphenous vein, and right internal thoracic artery grafts.* *J Thorac Cardiovasc Surg* 2011;142:980-8.
 29. Tatoulis J, Buxton BF, Fuller JA, et al. *Long-term patency of 1108 radial arterial-coronary angiograms over 10 years.* *Ann Thorac Surg* 2009;88:23-9.
 30. Achouh P, Isselmou KO, Boutekadjirt R, et al. *Reappraisal of a 20-year experience with the radial artery as a conduit for coronary bypass grafting.* *Eur J Cardiothorac Surg* 2012;41:87-92.
 31. Arrigoni SC, Halbersma WB, Grandjean JG, Mariani MA. *Patients' satisfaction and wound-site complications after radial artery harvesting for coronary artery bypass.* *Interact Cardiovasc Thorac Surg* 2012;14:324-6.
 32. Denton TA, Trento L, Cohen M, et al. *Radial artery harvesting for coronary bypass operations: neurologic complications and their potential mechanisms.* *J Thorac Cardiovasc Surg* 2001;121:951-6.
 33. Gaudino M, Serricchio M, Tondi P, et al. *Chronic compensatory increase in ulnar flow and accelerated atherosclerosis after radial artery removal for coronary artery bypass.* *J Thorac Cardiovasc Surg* 2005;130:9-12.
 34. Roysse AG, Chang GS, Nicholas DM, Roysse CF. *No late ulnar artery atheroma after radial artery harvest for coronary artery bypass surgery.* *Ann Thorac Surg* 2008;85:891-4.
 35. Schena S, Crabtree TD, Baker KA, et al. *Absence of deterioration of vascular function of the donor limb at late follow-up after radial artery harvesting.* *J Thorac Cardiovasc Surg* 2011;142:298-301.
 36. Locker C, Schaff HV, Dearani JA, et al. *Multiple arterial grafts improve late survival of patients undergoing coronary artery bypass graft surgery: analysis of 8622 patients with multivessel disease.* *Circulation* 2012;126:1023-30.
 37. Tranbaugh RF, Dimitrova KR, Friedmann P, et al. *Radial artery conduits improve long-term survival after coronary artery bypass grafting.* *Ann Thorac Surg* 2010;90:1165-72.
 38. Schwann TA, Engoren M, Bonnell M, Clancy C, Habib RH. *Comparison of late coronary artery bypass graft survival effects of radial artery versus saphenous vein grafting in male and female patients.* *Ann Thorac Surg* 2012;94:1485-91.
 39. Lawton JS, Barner HB, Bailey MS, et al. *Radial artery grafts in women: utilization and results.* *Ann Thorac Surg* 2005;80:559-63.
 40. Habib RH, Schwann TA, Engoren M. *Late effects of radial artery versus saphenous vein grafting in patients aged 70 years or older.* *Ann Thorac Surg* 2012;94:1478-84.
 41. Halbersma WB, Arrigoni SC, Mecozzi G, et al. *Four-year outcome of OPCAB no-touch with total arterial Y-graft: making the best treatment a daily practice.* *Ann Thorac Surg* 2009;88:796-801.
 42. Barner HB, Sundt TM 3rd, Bailey M, Zang Y. *Midterm results of complete arterial revascularization in more than 1,000 patients using an internal thoracic artery/radial artery T graft.* *Ann Surg* 2001;234:447-52.
 43. Pym J, Brown PM, Charrette EJ, Parker JO, West RO. *Gastroepiploic-coronary anastomosis: a viable alternative bypass graft.* *J Thorac Cardiovasc Surg* 1987;94:256-9.
 44. Suma H, Fukumoto H, Takeuchi A. *Coronary artery bypass grafting by utilizing in situ right gastroepiploic artery: basic study and clinical application.* *Ann Thorac Surg* 1987;44:394-7.
 45. Gagliardotto P, Coste P, Lazreg M, Dor V. *Skeletonized right gastroepiploic artery used for coronary artery bypass grafting.* *Ann Thorac Surg* 1998;66:240-2.
 46. Asai T, Tabata S. *Skeletonization of the right gastroepiploic artery using an ultrasonic scalpel.* *Ann Thorac Surg* 2002;74:1715-7.
 47. Shimizu T, Suesada H, Cho M, Ito S, Ikeda K, Ishimaru S. *Flow capacity of gastroepiploic artery versus vein grafts for intermediate coronary artery stenosis.* *Ann Thorac Surg* 2005;80:124-30.
 48. Kim KB, Kang CH, Lim C. *Prediction of graft flow impairment by intraoperative transit time flow measurement in off-pump coronary artery bypass using arterial grafts.* *Ann Thorac Surg* 2005;80:594-8.
 49. Suma H, Isomura T, Horii T, Sato T. *Late angiographic result of using the right gastroepiploic artery as a graft.* *J Thorac Cardiovasc Surg* 2000;120:496-8.
 50. Suma H, Tanabe H, Takahashi A, et al. *Twenty years experience with the gastroepiploic artery graft for CABG.* *Circulation* 2007;116(11 Suppl):I188-91.
 51. Bai XY, Liu XC, Jing WB, Yang Q, Tang XD, He GW. *Effect of amlodipine in human internal mammary artery and clinical implications.* *Ann Thorac Surg* 2010;90:1952-7.
 52. De Bruyne B, Pijls NH, Kalesan B, et al. *Fractional flow reserve-guided PCI versus medical therapy in stable coronary disease.* *N Engl J Med* 2012;367:991-1001.
 53. Farkouh ME, Domanski M, Sleeper LA, et al. *Strategies for multivessel revascularization in patients with diabetes.* *N Engl J Med* 2012;367:2375-84.
 54. Botman CJ, Schonberger J, Koolen S, et al. *Does stenosis severity of native vessels influence bypass graft patency?: a*

- prospective fractional flow reserve-guided study. *Ann Thorac Surg* 2007;83:2093-7.
55. Cho KR, Hwang HY, Kim JS, Jeong DS, Kim KB. *Comparison of right internal thoracic artery and right gastroepiploic artery Y grafts anastomosed to the left internal thoracic artery.* *Ann Thorac Surg* 2010;90:744-50.
 56. Kim KB, Cho KR, Jeong DS. *Midterm angiographic follow-up after off-pump coronary artery bypass: serial comparison using early, 1-year, and 5-year postoperative angiograms.* *J Thorac Cardiovasc Surg* 2008;135:300-7.
 57. Eda T, Matsuura A, Miyahara K, et al. *Transplantation of the free gastroepiploic artery graft for myocardial revascularization: long-term clinical and angiographic results.* *Ann Thorac Surg* 2008;85:880-4.
 58. Puig LB, Ciongolli W, Cividanés GV, et al. *Inferior epigastric artery as a free graft for myocardial revascularization.* *J Thorac Cardiovasc Surg* 1990;99:251-5.
 59. Barner HB, Naunheim KS, Peigh PS, Willman VL, Fiore AC. *Inferior epigastric artery for myocardial revascularization.* *Eur J Cardiothorac Surg* 1993;7:478-81.
 60. Johnson DY, Johnson FE, Barner HB. *Abdominal wall necrosis after harvest of both internal thoracic and inferior epigastric arteries.* *Ann Thorac Surg* 2011;91:38-41.
 61. Puig LB, Sousa AH, Cividanés GV, et al. *Eight years experience using the inferior epigastric artery for myocardial revascularization.* *Eur J Cardiothorac Surg* 1997;11:243-7.
 62. Buche M, Dion R. *Current status of the inferior epigastric artery.* *Semin Thorac Cardiovasc Surg* 1996;8:10-4.
 63. Perrault LP, Carrier M, Hebert Y, Cartier R, Leclerc Y, Pelletier LC. *Early experience with the inferior epigastric artery in coronary artery bypass grafting: a word of caution.* *J Thorac Cardiovasc Surg* 1993;106:928-30.
 64. Carrier M, Gregoire J, Tronc F, Cartier R, Leclerc Y, Pelletier LC. *Effect of internal mammary artery dissection on sternal vascularization.* *Ann Thorac Surg* 1992;53:115-9.
 65. Buche M, Schroeder E, Gurne O, et al. *Coronary artery bypass grafting with the inferior epigastric artery. Midterm clinical and angiographic results.* *J Thorac Cardiovasc Surg* 1995;109:553-9.
 66. Calafiore AM, Di Giammarco G, Teodori G, et al. *Radial artery and inferior epigastric artery in composite grafts: improved midterm angiographic results.* *Ann Thorac Surg* 1995;60:517-23.
 67. Edwards WS, Lewis CE, Blakeley WR, Napolitano L. *Coronary artery bypass with internal mammary and splenic artery grafts.* *Ann Thorac Surg* 1973;15:35-40.
 68. Blakeman B, Pickleman J, He GW. *Splenic artery grafting.* In: He GW, editor. *Arterial grafting for coronary artery bypass surgery.* Berlin, Heidelberg, New York: Springer-Verlag; 2006. p. 215-7.
 69. Newcomb A, Oqueli E, Buxton BF. *Ulnar artery as a coronary artery bypass graft: five-year experience.* In: He GW, editor. Berlin, Heidelberg, New York: Springer-Verlag; 2006. p. 227-32.
 70. Fabbrocini M, Fattouch M, Camporini G, et al. *Descending branch of lateral circumflex femoral artery in arterial CABG: early and midterm results.* *Ann Thorac Surg* 2003;75:1836-41.
 71. Tatsumi TO, Minohara S, Kondoh K, et al. *Descending branch of the lateral circumflex femoral artery grafting.* In: He GW, editor. *Arterial grafting for coronary artery bypass grafting.* Berlin, Heidelberg, New York: Springer-Verlag; 2006. p. 233-7.
 72. He GW, Mills NL. *Use of the subscapular-thoracodorsal artery for coronary artery bypass grafting.* In: He GW, editor. *Arterial grafting for coronary artery bypass grafting.* Berlin, Heidelberg, New York: Springer-Verlag; 2006. p. 218-22.
 73. Simic O, Zambelli M, Zelis M, Pirjavec A. *Thoracodorsal artery as a free graft for coronary artery bypass grafting.* *Eur J Cardiothorac Surg* 1999;16:94-6.
 74. Shatapathy P, Aggarwal BK, Punnen J. *Inferior mesenteric artery as a free arterial conduit for myocardial revascularization.* *J Thorac Cardiovasc Surg* 1997;112:210-1.
 75. Shatapathy P, Aggarwal BK. *Inferior mesenteric artery grafting.* In: He GW, editor. *Arterial grafting for coronary artery bypass grafting.* Berlin, Heidelberg, New York: Springer-Verlag; 2006. p. 223-6.