

Total Arch Replacement with Stented Elephant Trunk in DeBakey Type I Acute Aortic Dissection

Hyung-Yoon Choi, M.D., Suk-Won Song, M.D., Ph.D., Sun-Chang Hong, M.D., Sun-Hee Lim, R.N.

A 67-year-old female patient was treated with conventional total arch replacement and insertion of a stented elephant trunk (SET) graft into the descending thoracic aorta for acute DeBakey type I aortic dissection at one time. She had been treated with right coronary artery stent insertion for acute myocardial infarct 4 days earlier, and at that time, she was diagnosed with acute DeBakey type I aortic dissection from the ascending aorta to the suprarenal artery based on trans-esophageal echocardiography and aorta computed tomography. Through a median sternotomy, we inserted the SET graft through the opened aorta to the descending aorta. We also performed anastomosis between the proximal stented graft and the distal aortic arch, and then performed total arch replacement. For acute DeBakey type I aortic dissection, we report total arch replacement with insertion of a SET graft as a combination of conventional surgery and the interventional technique.

Key words: 1. Aorta surgery
2. Aortic dissection

CASE REPORT

A 67-year-old female patient visited the hospital for acute DeBakey type I aortic dissection surgery. She had been admitted to another hospital for sudden chest pain 4 days earlier. Echocardiography showed 25% ejection fraction with a right ventricular wall motion abnormality, and the blood tests revealed creatine kinase-MB (CK-MB) at 220 mcg/L. For treatment of the acute myocardial infarct, the patient underwent emergency coronary stent insertion into the proximal right coronary artery (RCA) stenosis lesion, which revascularized after the procedure (Fig. 1A, B). At that time, the cause of the chest pain was thought to be acute myocardial infarction (MI), but echocardiography and angiography showed the aortic dilatation, which was suggestive of the membrane

of aortic dissection, and computed tomography (CT) was performed, which revealed acute DeBakey type I aortic dissection from the ascending aorta to the suprarenal artery. The MI appeared to be associated with acute DeBakey type I aortic dissection involving the proximal RCA (Fig. 1C), and the ascending aorta and the descending aorta measured 52.0 and 30.8 mm in diameter, respectively. The right renal artery originated from the true lumen, and the left renal artery originated from the false lumen (Fig. 1D-F).

The EF improved to 51% on echocardiography 2 days after coronary stent insertion. The patient was then transferred to Gangnam Severance Hospital, Yonsei University Health System. Upon admission, the patient was intubated for mechanical ventilator support and her vital signs were stable. We could not verify her consciousness level. However, there

Department of Thoracic and Cardiovascular Surgery, Gangnam Severance Hospital, Yonsei University Health System

†This manuscript was presented at the 43th Annual Symposium of Korean Society for Thoracic and Cardiovascular Surgery.

Received: February 24, 2012, Revised: October 1, 2012, Accepted: October 5, 2012

Corresponding author: Suk-Won Song, Department of Cardiovascular Surgery, Gangnam Severance Hospital, Yonsei University Health System, 211 Eonju-ro, Gangnam-gu, Seoul 135-720, Korea
(Tel) 82-2-2019-3380 (Fax) 82-2-3461-8282 (E-mail) sevrphd@yuhs.ac

© The Korean Society for Thoracic and Cardiovascular Surgery. 2013. All right reserved.

© This is an open access article distributed under the terms of the Creative Commons Attribution Non-Commercial License (<http://creativecommons.org/licenses/by-nc/3.0>) which permits unrestricted non-commercial use, distribution, and reproduction in any medium, provided the original work is properly cited.

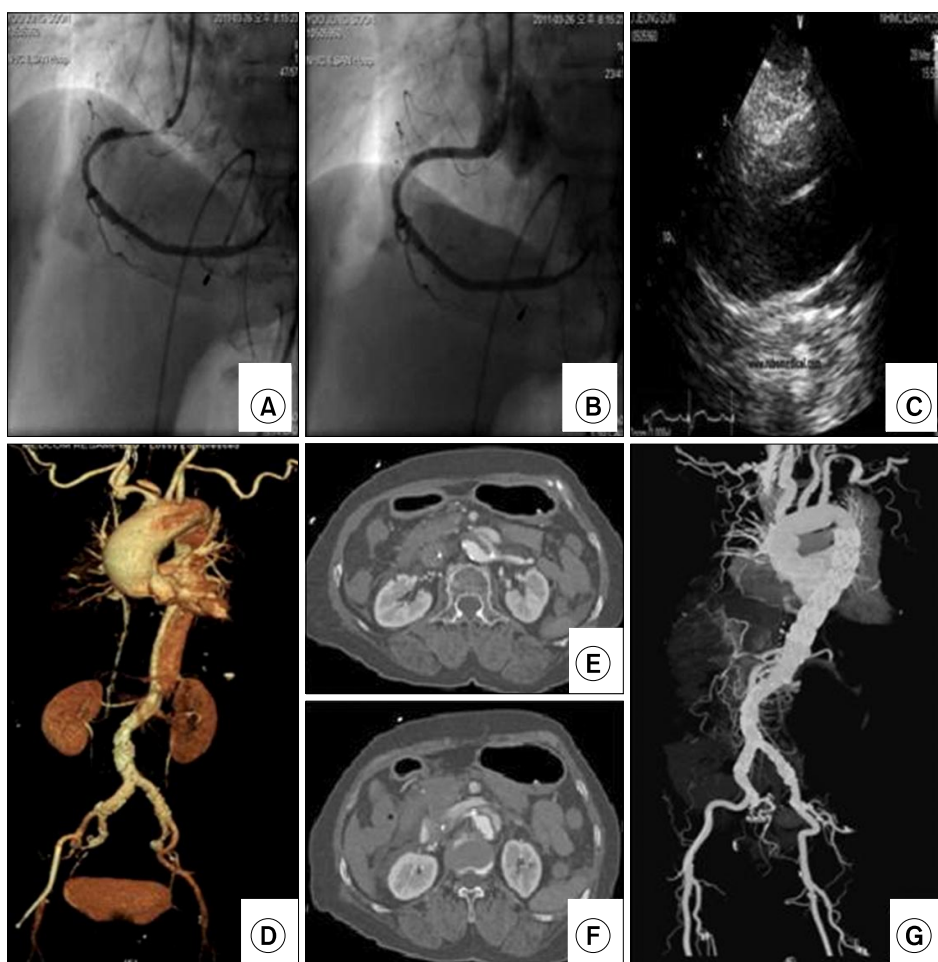


Fig. 1. Angiography, echocardiography, and computed tomography (CT). (A, B) Preoperative angiography before revascularization, after stent insertion, (C) preoperative echocardiography showing abnormal membrane, (D-F) preoperative CT, (G) postoperative CT.

was a definite pupil reflex response, and CK-MB was at 13.35 mcg/L. We decided to perform the operation. A median sternotomy was performed, and dual cannulation was performed at the left femoral artery and the right axillary artery, which was anastomosed with an 8 mm vascular graft. After venous cannulation of the right atrium, cardio-pulmonary bypass (CPB) was started. The rectal temperature decreased to 26.4°C during aortic dissection. When we open the aorta after unilateral SCP, there was a big intimal tear at the distal ascending aorta. The aortic arch and the branches of the aorta were removed with the patient in a low temperature state with antegrade selective cerebral perfusion (SCP). We inserted a SET with a 32 mm diameter, and 20 cm length (5+15; S&G Biotech Inc., Seongnam, Korea) to the descending aorta 1 to 2 cm posterior of the left subclavian artery through the introducer. During the operation, through trans-esophageal

echocardiography, the distal stented graft was traced. Total aortic arch graft replacement was then performed with a 30 mm 4-branch graft. The CPB time was 190 minutes, the aortic cross-clamping time was 69 minutes, the total cardiac arrest time was 50 minutes, and the SCP time was 20 minutes. The patient's postoperative state was stable, and she was followed up with CT. The patient regained consciousness without any neurological problems (Fig. 1G).

DISCUSSION

In DeBakey type I acute aortic dissection, emergency surgery is inevitable and the prognosis cannot be ensured. To produce better results, the role of surgical treatment is the most critical. Conventionally, in DeBakey type I acute aortic dissection, one of the following operations has been per-

formed: ascending aorta graft replacement, total arch replacement, or hemiarch replacement. However, the question remains whether the remaining dissected false lumen is safe. The ultimate goal of the operation is the complete resection of the intimal tear and the obliteration of the false lumen in order to prevent more dilatation of the remaining dissected descending aorta. Due to this, the conventional approach has limitations. The conventional (frozen) elephant trunk technique was next introduced, but complications such as kinking and flapping emerged. Extensive surgery has a high risk. The optimal treatment for acute DeBakey type I aortic dissection has not been established [1,2].

Because of the need for a safe and comprehensive treatment, the technique of total arch replacement with a stented elephant trunk (SET) graft has been introduced. A bare graft portion of an SET (S&G Biotech Inc.) and a 4-branched graft were used for total arch replacement after SET insertion using a specific introducer at 0.5 to 1 cm distal to the left subclavian artery. According to a German study in 2008, the hybrid operation of total arch replacement with an SET was found to be equivalent to the conventional operation (total arch replacement only) with respect to in-hospital mortality and morbidity. The results of other studies on the use of SET grafts were similar [1,3,4]. The SET procedure has advantages such as false lumen obliteration of the descending aorta. In primary intimal tear of descending aorta, direct insertion of the stented graft into the descending aorta which is difficult to approach using mid-sternotomy, the stented graft could cover the tear and make false lumen obliteration by thrombus formation, as a result, the blood flow improves, which makes space for the true lumen that is compressed by the false lumen. Also sealing with thrombus formation at the tearing focus can prevent progressive bleeding and dissection, and thrombus obliteration without tearing of the false lumen can prevent more dilatation of the aorta, and because of this, gradual normalization of the aorta can be expected [3]. As a result, thrombus obliteration of the residual false lumen of the descending aorta lowers the risks of later dilatation and dissection, and can lower the reoperation rate, which in turn can reduce late mortality. These results are equal to that performed by descending graft replacement. Several studies have demonstrated a high thrombus obliteration rate. Jacob et al.

found that 10% of their patient group had a high false lumen obliteration rate, which ranged between from 77% to 100% in review paper of Murzi et al. [4] and studies of Sun et al. [5].

The usual indications for total arch replacement with SET DeBakey I acute dissection are retrograde dissection involving the distal aortic arch or proximal descending thoracic aorta, and in young patients, it is critical to have a proper size and length of the stent to cover the aorta and sleeve dissection showing the detached adventitia [3]. This hybrid operation can result in spinal cord injury due to the prompt thrombosis of the intercostal arteries of the descending aorta, and can result in the potential for false lumen reentry of the distal stent part in patients with Marfan disease, who have a small true lumen, thus limiting the potential for surgery. When the true lumen aorta is too small and the tortuous aorta and aneurysmal aorta are more than 50 mm in size, staged surgery should be considered first [1,2,6]. During preoperative decision making, it is critical to have the proper size and length of the stent and to check the shape of the true lumen of the aorta to avoid the aforementioned complications. Liu et al. [2] explained that for acute cases, the diameter of the stented graft should be 10% bigger than the diameter of the native proximal descending aorta, and that the proper location of the stent should be between T7 and T8 to avoid injury to the vital intercostal arteries [1,3].

As a combination of the interventional procedure and conventional approach, total arch replacement with an SET graft is feasible for repairing intimal tears and for promoting thrombus formation in the false lumen, and this procedure is expected to reduce the rate of late mortality and morbidity. This procedure can also be an alternative treatment for patients with acute DeBakey type I aortic dissection who have an intimal tear in the aortic arch and descending aorta.

CONFLICT OF INTEREST

No potential conflict of interest relevant to this article was reported.

REFERENCES

1. Sun L, Qi R, Zhu J, Liu Y, Zheng J. *Total arch replace-*

Total Arch Replacement with Stented Elephant Trunk of the Descending Aorta

- ment combined with stented elephant trunk implantation: a new “standard” therapy for type a dissection involving repair of the aortic arch?* Circulation 2011;123:971-8.
2. Liu ZG, Sun LZ, Chang Q, et al. *Should the “elephant trunk” be skeletonized?: total arch replacement combined with stented elephant trunk implantation for Stanford type A aortic dissection.* J Thorac Cardiovasc Surg 2006;131:107-13.
 3. Chen X, Huang F, Xu M, et al. *The stented elephant trunk procedure combined total arch replacement for DeBakey I aortic dissection: operative result and follow-up.* Interact Cardiovasc Thorac Surg 2010;11:594-8.
 4. Murzi M, Tiwari KK, Farneti PA, Glauber M. *Might type A acute dissection repair with the addition of a frozen elephant trunk improve long-term survival compared to standard repair?* Interact Cardiovasc Thorac Surg 2010;11:98-102.
 5. Sun L, Qi R, Zhu J, Liu Y, Chang Q, Zheng J. *Repair of acute type A dissection: our experiences and results.* Ann Thorac Surg 2011;91:1147-52.
 6. Sun L, Li M, Zhu J, et al. *Surgery for patients with Marfan syndrome with type A dissection involving the aortic arch using total arch replacement combined with stented elephant trunk implantation: the acute versus the chronic.* J Thorac Cardiovasc Surg 2011;142:e85-91.