

## Original Article

# Does the ADC Map have Additional Clinical Significance Compared to the DWI in the Brain Infarction?

Sunseob Choi, Dong-Ho Ha, Myong-Jin Kang, Jin Hwa Lee, Seong Kuk Yoon

Department of Radiology, College of Medicine, Dong-A University, Busan, Korea

**Purpose :** To re-evaluate additional clinical significance of the apparent diffusion coefficient (ADC) map in the inference of infarction stage, authors studied the evolution patterns of the DWI and the ADC map of the brain infarction.

**Materials and Methods:** In 127 patients with cerebral infarctions, including follow-up checks, 199 studies were performed. They were classified as hourly (117 studies)-, daily (108 studies)-, weekly (62 studies)-based groups. The signal intensity (SI) was measured at the core of the infarction and contralateral area with ROI of 0.3 cm<sup>2</sup> or more on the images of the DWI and the ADC map, and calculated the ratios of SI and ADC value of the infarction area / contralateral normal area, and compared the patterns of the change according to the evolution.

**Results:** Infarction was detected as early as 1 hour after the attack, and the ratio of SI in the DWI became over than 2 after 12 hours, which showed a plateau until the 6th day. Thereafter, it decreased slowly to 1 on the 30th day, and changed to lower SI than the surrounding brain. The ratio in the ADC map became 0.46 in 24 hours after the attack, and increased slowly to 1 in the 15th day. Thereafter, it became a higher value than the surrounding brain. Overall, the ratio in the ADC map changed earlier than in the DWI, and the ratio curves showed inverse pattern each other according to the evolution of the infarction.

**Conclusion:** The evolution patterns of infarction on the ADC map showed an inverse curve of DWI curve, which means that the ADC value is accurately predictable from DWI, and the ADC map joined with the DWI seems helpful in the determination of subacute infarction between 15 to 30 days.

**Index words :** Brain MRI · Diffusion weighted imaging · ADC map · Cerebral infarction

## INTRODUCTION

Diffusion weighted image-trace map (DWI) is a basic study for the detection of early infarction (1). The

ADC map is also known as another important diffusion related parameter having additional clinical information (2-4). Acute infarction initially shows high signal intensity (SI) in DWI and evolves to low SI. On contrary, on the ADC map, low SI of the infarction changes to high SI according to the evolution. DWIs are widely used in various brain lesions including infarction. And the ADC map is considered as having a better value than the DWI in stroke, even though there are still a lot of controversies.

There is a report that the ADC map is more reliable and reproducible than the DWI in the lesion size in acute ischemic stroke for clinical studies (5). Further,

• Received; July 24, 2013 • Revised; September 10, 2013

• Accepted; September 26, 2013

This work was supported by the Dong-A University Research Fund.

Corresponding author : Sunseob Choi, M.D.

Department of Radiology, Dong-A University Medical Center, 1, 3-ga, Dongdaeshin-dong, Seo-gu, Busan 602-715, Korea.

Tel. 82-51-240-5344, Fax. 82-51-253-4931

E-mail : sschoi317@yahoo.co.kr

ischemic lesion determination by ADC was more accurate in final infarction prediction, and provided exclusive information on ischemic lesion reversibility (6). The ADC may allow the identification of tissue at risk of infarction (4, 7), and ADC value is a potential parameter for predicting clinical outcome in acute stroke patients (1).

However, the ADC map has prominent artifact, and even though infarction itself shows more low SI than normal area, normal brain also shows diffuse low SI on the ADC map, and so the areas of infarction are less perceptible on ADC map than on DWI. In addition, there is a report that ADC map had lower reliability and excessive volume values in comparison to DWI (8). Furthermore, another report says the SI ratio on the DWI was better for identifying tissues at risk and predicting the final infarction than ADC ratio (9).

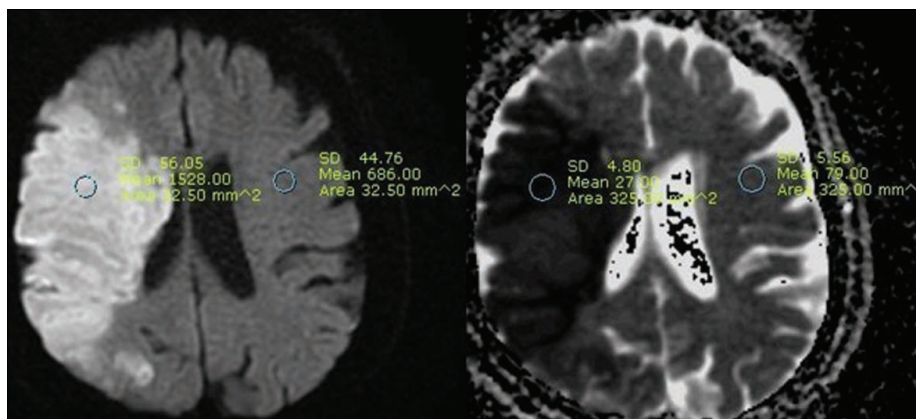
And so, this study was designed to re-evaluate the

additional clinical significance of ADC map compared to the DWI in the inference of infarction stage by the observation of the patterns of infarction evolution on the DWI and ADC map.

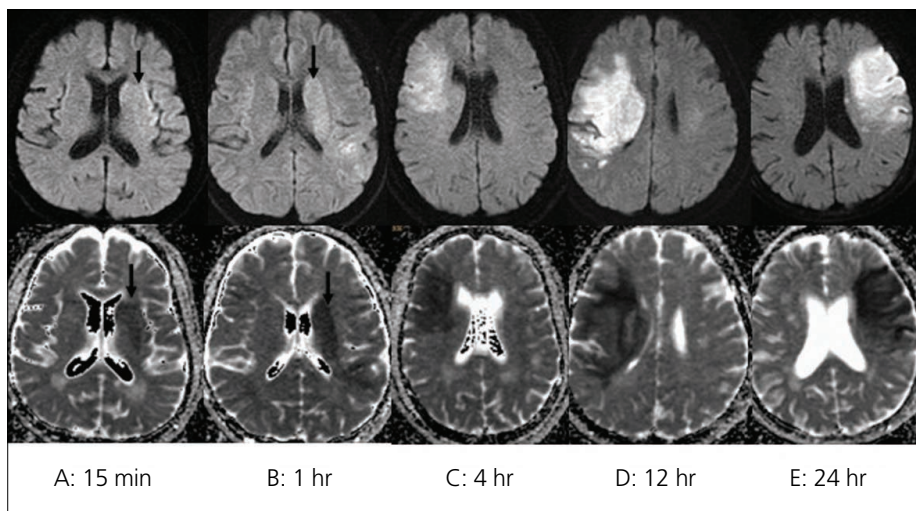
## MATERIALS AND METHODS

In 127 patients with cerebral infarction, including follow-up checks, 199 studies were performed using a 1.5 Tesla MRI system (Signa Excite, GE medical systems, Milwaukee, WI). The cases are only included in case of clear attack time of infarction and no evidence of accompanying hemorrhage.

MRI parameters were as follows: a spin echo EPI sequence with a b-value of 1000 s/mm<sup>2</sup>; 3 diffusion directions; repetition time of 3000 msec; echo time of 75 msec; matrix size of 160 × 160; 22 cm FOV; as well as 2 NEX and 5 mm slice thickness with 2 mm



**Fig. 1.** Example of ROI measurement; DWI (left) and ADC map (right) in a 68-year-old woman examined 46 hours after stroke onset. Note the ROIs placed on the lesion and contralateral normal-appearing hemisphere.

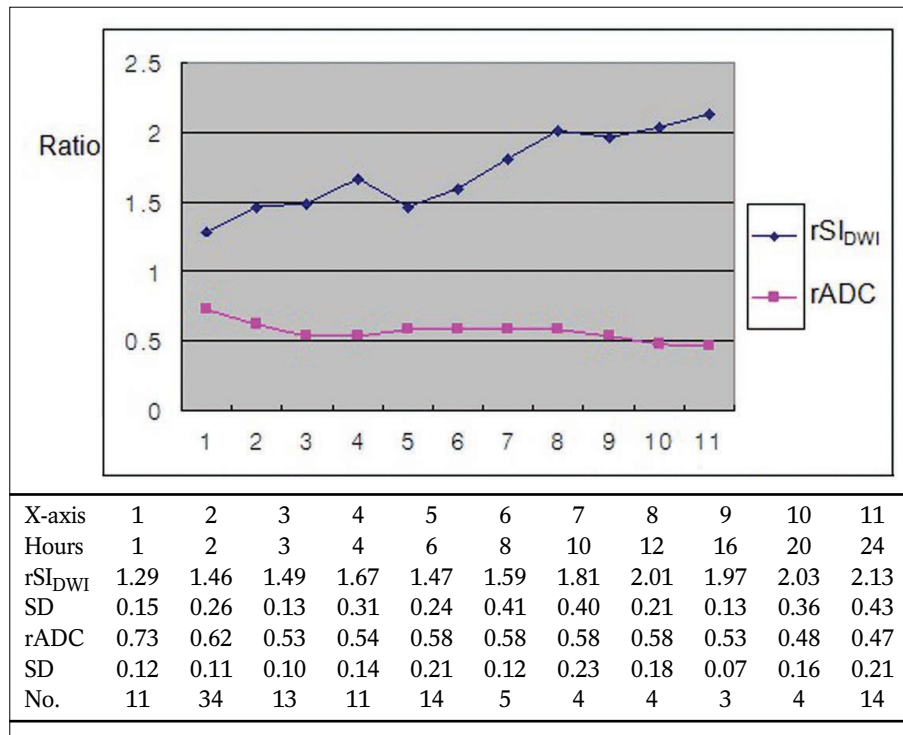


**Fig. 2.** Examples of the representative cases of different stroke onset; Infarction areas show high signal intensities on the DWI (upper row) and show low signal intensities on the ADC map (lower row) even less than an hour (arrows), and become peculiar up to 24 hours (A, B, C, D, E; different cases of time onset).

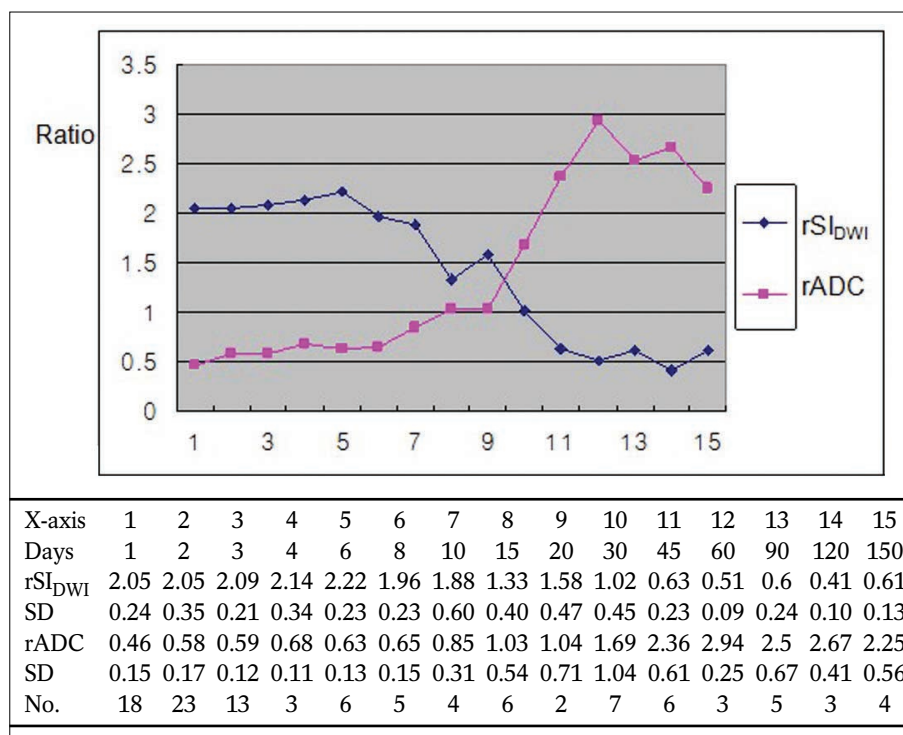
gap. They were classified as hourly (up to 24 hours of onset, 117 studies)-, daily (included only studies of more than 12 hours of onset, 108 studies)-, weekly (included only studies of more than 4 days of onset,

62 studies)-based groups.

The SIs were measured at the core of the infarction and corresponding regions in the contralateral normal appearing area with region-of-interest (ROI) of 0.3 cm<sup>2</sup>



**Fig. 3.** The evolution curves of average rSI<sub>DWI</sub> and rADC by hourly-based analysis; Curves show the SI on the DWI is increasing and the SI on the ADC map is decreasing continuously during first 24 hours.

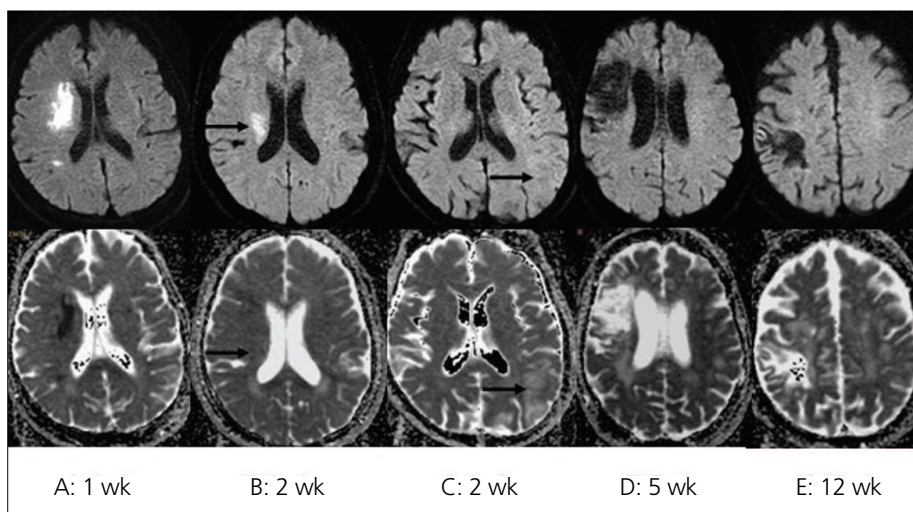


**Fig. 4.** The evolution curves of average rSI<sub>DWI</sub> and rADC by daily-based analysis; Curves show the SI on the DWI is decreasing after peak value on the 6th day and the SI on the ADC map is increasing after the lowest value on the first day.

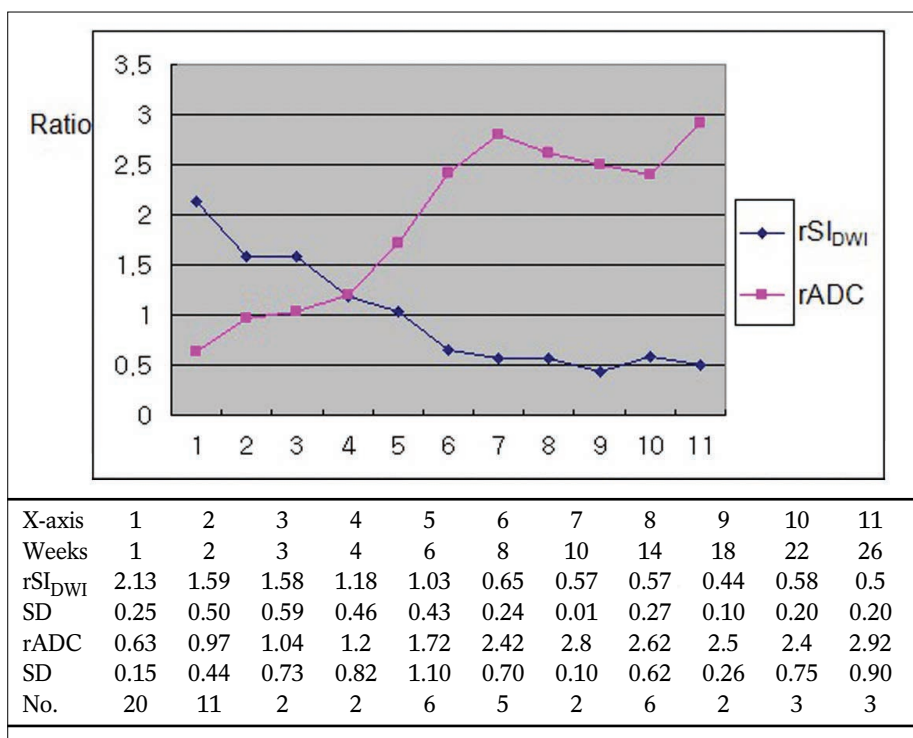
or more on the images of DWI and ADC map. Relative DWI SI ratio ( $rSI_{DWI}$ ) was calculated by the SI of the infarction area / contralateral normal area on the DWI, and relative ADC ratio ( $rADC$ ) was also calculated by the ADC value of the infarction area / contralateral normal area on the ADC map (Fig. 1). And, the mean values were calculated and compared the changing patterns of the ratios in each group according to the evolution of the lesions by the time course.

## RESULTS

In the hourly-based analysis, the  $rSI_{DWI}$  increased to 1.29 within one hour, and continuously increased to 2.13 at 24 hours, and the  $rADC$  decreased to 0.73 within one hour, and continuously decreased to 0.47 at 24 hours after stroke onset (Figs. 2, 3). In the daily-based analysis, the  $rSI_{DWI}$  was 2.05 within the first day, and peaked to 2.22 in the 6th day, and decreased to 1.02 in the 30th day, which means contrast lost, and



**Fig. 5.** Examples of the representative cases of different stroke onset; Note pseudonormalization (arrows) of the infarction on the ADC map in the case B, and on the DWI in the case of C (A, B, C, D, E; different cases of time onset).



**Fig. 6.** The evolution curves of average  $rSI_{DWI}$  and  $rADC$  by weekly-based analysis; Curves show the SI on the DWI is decreasing and the SI on the ADC map is increasing continuously after the first week.

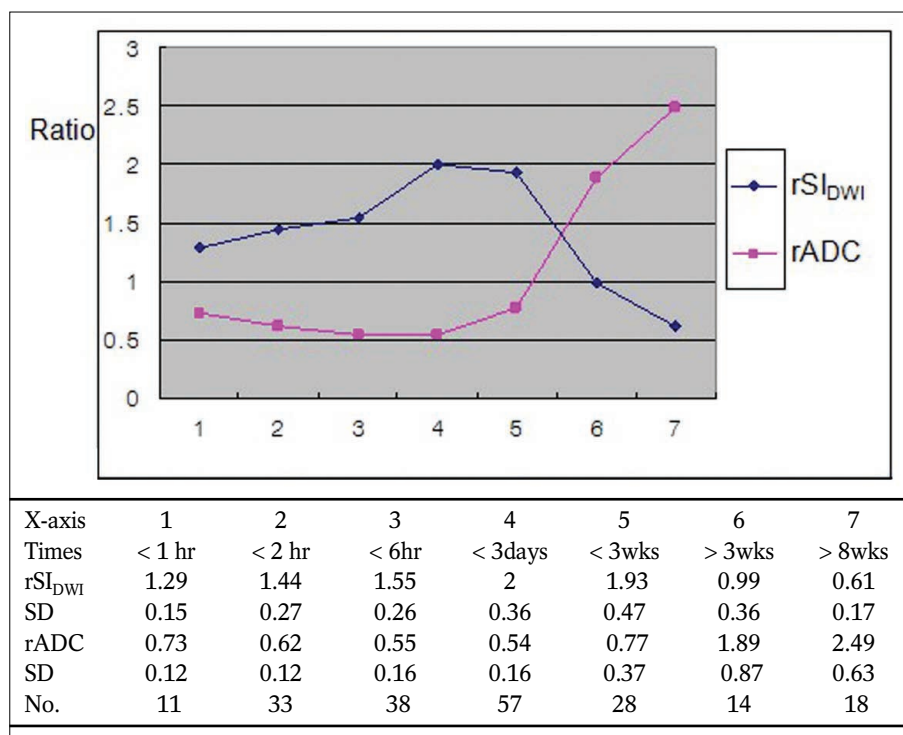
continuously decreased to the lowest value of 0.41 at the 120th day after stroke onset. The rADC showed the lowest value of 0.46 within the first day, and increased to 1.03 in the 15th day, which means contrast lost, and continuously increased to the highest value of 2.94 at the 60th day after stroke onset (Fig. 4). In the weekly-based analysis, the rSI<sub>DWI</sub> was 2.13 in the first week, and decreased to 1.03 in the 6th week, which means contrast lost, and continuously decreased to the lowest value of 0.44 at the 18th week. The rADC showed the lowest value of 0.63 in the first week, and increased to 1.04 in the third week, which means contrast lost, and continuously increased to the highest value of 2.92 at the 26th week after stroke onset (Figs. 5, 6). In the all case, the rSI<sub>DWI</sub> increased in an hour in the brain infarction, and continuously increased to the highest value of 2.0 in the third day, and decreased to low value of 0.99 after the third week. The rADC decreased in an hour, and continuously decreased to the lowest value of 0.54 in the third day, and increased to high value of 1.89 after the third week (Fig. 7). The change patterns of the rSI<sub>DWI</sub> and rADC showed as a linear function in chronologic order. And, though there was a trend of earlier transition on the ADC map than on the DWI according to the evolution of the infarction, the rADC

curve showed inverse pattern to rSI<sub>DWI</sub> with no other information.

## DISCUSSION

The DWI is a basic study and a better imaging method than the conventional MRI for the detection of early ischemic lesions (1), and the ADC map is also known as another important diffusion tensor imaging parameter, having additional clinical information like as the age, size, reversibility and outcome of the infarction (2–7). However, to have additional clinical significance on the ADC, the ADC map must have different evolution pattern compared to the DWI. If the evolution pattern in the ADC is same with the DWI, additional significance of the ADC would not present. And also, previous reports have some weak points like as not enough observation time courses in detail, not enough time duration and not many study case numbers. This study was designed to know the pattern of evolutions of the DWI and the ADC map of the infarction to know the additional clinical significance of the ADC map compared to the DWI in detail.

In this study, objects are not homogeneous in terms of infarction location and infarction size, collateral



**Fig. 7.** The evolution curves of average rSI<sub>DWI</sub> and rADC with all case; Curves show the evolution pattern of SI according to the time course on the ADC map is inversely correlated with DWI.

circulations and in time groups. Such many factors could contribute in the SI during the evolution of the infarction, and the SI itself is expressed by overall effect of those complex factors. And, thrombolysis cases, hemorrhagic infarction cases and reversible infarctions, which showed normalized SI on the follow up DWI during the first 3 days, were not included. Until now, infarction area is defined by increased signal on the DWI, and infarction itself usually has inhomogeneous SI with ill defined border. Because of inhomogeneous SI of infarction, the ROI is applied at the core of infarction as a representative portion showing the highest SI on the DWI, which is considered as typically damaged portion within the lesion of having heterogeneous SI. The ADC value is different by investigators, and considered it could be affected by the machine and the program used. There seems no report on the ADC value change in detail according to the time course in the infarction. Though the ADC value itself is an absolute value, to compare with  $rSI_{DWI}$ , the rADC was calculated by the ADC value of the infarction area / contralateral normal area.

The SI on the DWI and the value of the ADC are continuously changing according to the evolution of infarction. In the ADC map, infarction area shows lower SI than normal area, but less peculiar than in the DWI because of low SI brain parenchyma in the ADC map. The ADC values are different according to the studies, and were reported as from  $0.74$  to  $0.88 \times 10^{-3} \text{ mm}^2/\text{sec}$  (2, 8) in the normal brain parenchyma. The ADC values of tissue at risk of infarction was  $0.75$  (7), and the ADC values of infarction areas were from  $0.46$  (10) to  $0.66$  (7). In this study, the mean ADC value in all normal parenchymal ROIs was  $0.85 \times 10^{-3} \text{ mm}^2/\text{sec}$ , and  $0.40 \times 10^{-3} \text{ mm}^2/\text{sec}$  in the infarction at 24 hours.

There are some reports on the ADC map as follows; Lesion size measured on the DWI and ADC values are potential parameters in the prediction of clinical outcome in acute stroke patients (1). The ADC map may be useful for estimating the lesion age (2). Relative ADC is less than normal during a day of stroke onset, then increased to pseudonormal levels at 15 days, and later increased than normal levels (5). In the daily-based analysis of this study, the rADC also increased to 1.03 in the 15th day, which means contrast lost. Ischemic lesion determined by the ADC

was more accurate in the final infarct prediction, and provided exclusive information on ischemic lesion reversibility (6). The ADC and ratio of ischemic/control ADC values are more reliable and reproducible than DWI for the estimation of the lesion size in acute ischemic stroke (5). The rADC may help to predict infarct growth and final infarction size (7). Intermediate ADC values are present in the ischemic penumbra, and are indicative of tissue at risk of infarction (4). Heterogeneity in ADC and diffusion anisotropy evolution was observed not only between patients but also within individual lesions (11). The differences of ADC progression were depending on the patient's age and infarct etiology (12). Furthermore, the SI changes of the infarction area according to the time course could depend on the amount of previous blood flow and collateral flows. The ADC values within contrast-enhancing regions of CNS lymphoma may provide noninvasive insight into clinical outcome (3).

Abnormal SI was present on the DWI in patients within 24 hours of acute infarction, and in up to 94% of patients during the first 2 weeks after the attack. The percentage of abnormal findings declined with time, and no SI abnormality was seen in stroke patients of more than 2 weeks after onset (13). The SI of infarction on the DWI normalized at 57 days, which is substantially later than that of the previous suggestion (10). In the daily-based analysis of this study,  $rSI_{DWI}$  decreased to 1.02 in the 30th day, which means contrast lost. The ADC map had lower reliability or excessive volume values in comparison to the DWI, and the DWI was the most reliable sequence for final infarction volume quantification (8). Pixel-based thresholds applied to the ADC maps or DWI SI were not accurate prognostic measures of tissue at risk. Quantitative DWI or ADC maps may provide added information, not obtained by visual inspection of the qualitative DWI. The SI ratio was better for identifying tissue at risk and predicting final infarction than ADC or ADC ratio (9).

In the hourly-based analysis, the evolution curve is increasing on the DWI and is decreasing on the ADC map continuously with inversed contrast (Fig. 3). In the daily-based analysis, the evolution curve is decreasing after peak value on the 6th day on the DWI and is increasing after the lowest value on the

first day on the ADC map (Fig. 4). In the weekly-based analysis, the evolution curve is decreasing on the DWI and is increasing continuously on the ADC map after the first week (Fig. 6). The evolution curve of the ADC map according to the time course showed inversed pattern of the DWI by all cases (Fig. 7). Actually ADC map itself was same image with inverse contrast to the DWI according to the evolution curves, and so the analysis for the additional clinical significance seems have no meaning.

In summary, the  $rSI_{DWI}$  was peaked with 2.22 in the 6th day, decreased to 1.02 in the 30th day, and the  $rADC$  showed the lowest value with 0.46 in 24 hours after stroke onset, and increased to 1.03 which means isointense SI or pseudonormalization in the 15th day, and the evolution pattern of SI on the ADC map is inversely correlated with the DWI.

## CONCLUSION

The pattern of evolution of the infarction on the ADC map showed inverse curve compared to the DWI, which means the ADC SI is predictable by the DWI itself. And, the ADC map joined with the DWI seems helpful in the determination of subacute infarction between 15 to 30 days.

## References

1. van Everdingen KJ, van der Grond J, Kappelle LJ, Ramos LMP, Mali WPTM. Diffusion-weighted magnetic resonance imaging in acute stroke. *Stroke* 1998;29:1783-1790
2. Lansberg MG, Thijs VN, O'Brien MW, et al. Evolution of apparent diffusion coefficient, diffusion-weighted, and T2-weighted signal intensity of acute stroke. *AJNR Am J Neuroradiol* 2001;22:637-644
3. Barajas RF, Rubenstein JL, Chang JS, Hwang J, Cha S. Diffusion-weighted MR imaging derived apparent diffusion coefficient is predictive of clinical outcome in primary central nervous system lymphoma. *AJNR Am J Neuroradiol* 2010; 131:60-66
4. Desmond PM, Lovell AC, Rawlinson AA, et al. The value of apparent diffusion coefficient maps in early cerebral ischemia. *AJNR Am J Neuroradiol* 2001; 22: 1260-1267
5. Rana AK, Wardlaw JM, Armitage PA, Bastin ME. Apparent diffusion coefficient (ADC) measurements may be more reliable and reproducible than lesion volume on diffusion-weighted images from patients with acute ischemic stroke; implications for study design. *J Magn Reson Imaging* 2003;21:617-624
6. Bratane BT, Bastan B, Fisher M, Bouley J, Henninger N. Ischemic lesion volume determination on diffusion weighted images vs. apparent diffusion coefficient maps. *Brain Research* 2009;1279:182-188
7. Oppenheim C, Grandin C, Samson Y, et al. Is there an apparent diffusion coefficient threshold in predicting tissue viability in hyperacute stroke? *Stroke* 2001;32:2486-2491
8. Sibon I, Menegon P, Orgogozo JM, et al. Inter- and intraobserver reliability of five MRI sequences in the evaluation of the final volume of cerebral infarct. *J Magn Reson Imaging* 2009; 29:1280-1284
9. Na DK, Thijs VN, Albers GW, Moseley ME, Marks MP. Diffusion-weighted MR imaging in acute ischemia: Value of apparent diffusion coefficient and signal intensity thresholds in predicting tissue at risk and final infarct size. *AJNR Am J Neuroradiol* 2004;25:1331-1336
10. Eastwood JD, Engelter ST, MacFall JF, DeLong DM, Provenzale JM. Quantitative assessment of the time course of infarct signal intensity on diffusion-weighted images. *AJNR Am J Neuroradiol* 2003;24:680-687
11. Yang Q, Tress BM, Barber PA, et al. Serial study of apparent diffusion coefficient and anisotropy in patients with acute stroke. *Stroke* 1999;30:2382-2390
12. Copen WA, Schwamm LH, Gonzalez RG, et al. Ischemic stroke: effects of etiology and patient age on the time course of the core apparent diffusion coefficient. *Neuroradiology* 2001;221:27-34
13. Burdette JH, Ricci PE, Petitti N, Elster AD. Cerebral infarction: time course of signal intensity changes on diffusion-weighted MR images. *AJR Am J Roentgenol* 1998;171:791-795

## 뇌경색에서 확산강조영상과 비교하여 현성확산계수 지도의 부가적인 임상적 중요성이 있는가?

동아대학교 의과대학 영상의학교실

최순섭 · 하동호 · 강명진 · 이진화 · 윤성국

**목적:** 뇌경색의 시기판단에 있어서 현성확산계수 지도의 부가적인 임상적 중요성을 다시 평가하기 위하여, 확산 강조 영상과 현성확산계수 지도에서 뇌경색의 시간경과에 따른 변화 양상의 차이가 있는지 알고자 한다.

**대상과 방법:** 뇌경색 환자 127명의 199회 자기공명영상 검사를 대상으로 하였으며, 시간을 기준으로(117 검사), 날짜를 기준으로 (108 검사), 주수를 기준으로 (62 검사) 그룹을 나누었다. 확산 강조영상과 현성확산계수 지도에서 뇌경색의 중심부와 대측부위를 관심영역 0.3 cm<sup>2</sup> 이상으로 하여 신호 강도를 측정하여, 경색부위/대측정상부위의 비 (ratio)를 구하여 각 그룹에서 시간 경과에 따른 변화양상을 비교관찰하였다.

**결과:** 뇌경색은 발생 1시간 이내부터 영상에서 관찰되었으며, 확산강조영상에서 신호강도비는 12시간 이후에 2 이상으로 되어 6일까지 유지되다가 점차 감소하여 발생 30일경에 1로 감소 하였다. 현성확산계수비는 발생 24시간에 0.46 이었으며, 15일경에 1로 증가하였다. 뇌경색의 시간 경과에 따른 비의 곡선은 서로 역의 관계인 대칭적인 양상을 보였다.

**결론:** 확산강조영상과 현성확산계수 지도에서 뇌경색의 시간경과에 따른 변화양상은 역의 관계로서 현성확산계수 값은 확산강조영상으로부터 예측 가능하며, 현성확산계수 지도는 확산강조영상과 함께 판단하면 15-30일 사이의 아급성기 뇌경색의 진단에 도움이 될 수 있을 것이다.

통신저자 : 최순섭, (602-715) 부산시 서구 동대신동 3가 1, 동아대학교 의과대학 영상의학과  
Tel. (051) 240-5344 Fax. (051) 253-4931 E-mail: sschoi317@yahoo.co.kr