RESEARCH ARTICLE

Salivary Gland Tumors: A Clinicopathologic Study of 366 Cases in Southern Iran

Zohreh Jaafari-Ashkavandi[1]*, Mohammad-Javad Ashraf[2]*, Maryam Moshaverinia[3]

Abstract

Background: Salivary gland tumors (SGT) are one of the most complex human neoplasms, demonstrating variations in their clinicopathological profile related to racial and geographic differences. Few studies with large samples have been reported in Iran. We here investigated a large group of patients in southern Iran. Materials and Methods: In this retrospective study, all cases of primary epithelial salivary gland tumors, which had been recorded in a 5 years period from 2005-2009, were enrolled. Clinical data such as histopathologic type and site of the lesion as well as patients' age and gender were analyzed. Results: Data of 366 cases of SGTs were recorded. Pleomorphic adenoma (80.2%) and adenoid cystic carcinoma (46.6%) were the most common benign and malignant neoplasms. Male to female ratio (M/F) and the mean age of patients were 1:1.05 and 37.7 for benign tumors while they were 1.2:1 and 50.6 for malignant tumors, respectively. Parotid and minor salivary glands were involved more frequently. Conclusions: Although the salivary gland tumours encountered were similar in most of their characteristics to those reported in other countries, some differences such as relative frequency and age and gender prevalence were discovered. These findings should help surgeons and pathologists for more accurate diagnosis, management and treatment.

Keywords: Salivary gland neoplasms - minor salivary glands - benign tumors - malignant tumors - incidence - Iran

Asian Pacific J Cancer Prev, **14 (1)**, 27-30

Introduction

Salivary gland tumors (SGTs) are a heterogeneous group of neoplasms in the maxillofacial area with complex morphologic appearance and different clinical behavior. These tumors are relatively uncommon, comprising 3-6% of all head and neck neoplasms in various reports (Ansari, 2007; Jones et al., 2008). However, they are an important issue in the science of head and neck pathology, due to their difficult diagnosis, management and unpredictable clinical course of disease. Etiologic factors of this group of neoplasms have not been recognized exactly however; Ionizing radiation, sunlight, chemotherapy, smoking and vitamin A deficiency have been pointed out in the literature (Licitra et al., 2003; Hashemi et al., 2007). These tumors have inconsistent characteristics in different countries and it seems that geographic location and ethnic factors may affect clinicopathologic profile of these tumors (Kayembe et al., 2002; Shishegar et al., 2011). Clinical data such as patient's age and gender, site of involvement and the relative incidence are imperative for accurate diagnosis and management. We found only limited number of reports of large group of cases in Iranian population. This research analyzes a large group of patients in southern Iran pertaining to clinicopathologic data of tumors.

Materials and Methods

This retrospective study engaged every case of primary epithelial SGTs which had been recorded in pathology department of Kalili hospital, the major referral ENT center, in southern Iran during 5 year period from April 2005 to May 2009. Recurrent, metastatic and non-epithelial tumors were excluded, as were the samples with doubtful diagnosis. We surveyed all cases regarding patient's age and gender as well as site of involvement and final histopathologic diagnosis according to the patient's medical records. We classified the neoplasms according to the 2005 World Health Organization (WHO). The minor salivary gland tumors included all of the neoplasms which were located in the lips, oral cavity, nasal fossa, paranasal sinuses, as well as maxillary and mandible. Data were analyzed using SPSS 11 software.

Results

Among 13,300 records, 366 cases were diagnosed as SGTs. 185 (50.5%) were male and 181 (49.4%) were

*[1]Department of Oral and Maxillofacial Pathology, [3]Department of Oral Medicine, School of Dentistry, [2]Department of Pathology, School of Medicine, Shiraz University of Medical Sciences, Shiraz, Iran *For correspondence: jaafariz@sums.ac.ir*

female (M/F 1.02:1). The age range was from 5-83 years with mean age of 41.8±16.7. Out of all SGTs, 249 were benign and 109were malignant. Pleomorphic adenoma (PA) was the most common tumor comprising 54.3% all SGTs followed by adenoid cystic carcinoma (ACC) (15%) and mucoepidermoid carcinoma (MEC) (9.2%).

Benign tumors

These neoplasms constituted 248 (67.8%) of all tumors and involved 121 males and 127 females (M/F: 1:1.05). The mean age of patients was 37.7±14.9. Table 1 shows details of this group. PA and Warthin's tumor were the first and the second most common benign tumor, respectively. These neoplasms tend to involve parotid and submandibular glands more frequently.

Malignant tumors

Out of all samples, 118 (32.2%) neoplasms were malignant (Table 2). M/F was 1.2:1 in this group. ACC with 55 cases (46.6%) and MEC with 35 cases (29.6%) were the first and the second most common type respectively (Table 2). Parotid and minor salivary glands showed the most frequent involvement with this tumor.

Anatomic variations

Parotid gland: 57.5% (n=210) of all SGTs located in this location. Benign to malignant ratio was 4:1. PA and MEC were the most common tumors in this area.

Submandibular gland: 48 cases (13.1%) located in these glands that 73% were benign. PA and ACC achieved the first place in benign and malignant groups.

Sublingual gland: Only 3 cases of ACC were found in this area.

Minor salivary glands: These glands were involved by 28.5%(n=105) of all SGTs and most of these neoplasms were malignant (56%). PA and ACC were the most common benign and malignant entities. Palate was the most frequent site of involvement. 5.2% of tumors involved intra-osseous glands in maxilla and mandible (Figure1).

Figure 2 shows the relative frequency of benign and malignant tumors in various anatomic locations.

Table 1. Distribution of Benign Salivary Gland Tumors According to Tumor Type, Age and Gender

Tumor	Female/Male	No (%)	SD± Mean age
Pleomorphic adenoma	111/88	199 (80.2)	36.0±13.3
Myoepithelioma	6/11	17 (6.9)	38.5±16.9
Warthin's tumor	6/20	26 (10.5)	50.8±19.4
Monomorphic adenoma	4/2	6 (2.4)	75.2±21.6
Total	127/121	248 (100)	37.7±14.9

Table 2. Distribution of Malignant Salivary Gland Tumors According to Tumor Type, Age and Gender

Tumor	Female/Male	No. (%)	SD±Meanage
Mucoepidermoid carcinoma	19/16	36 (29.7)	16.6±49.50
Acinic cell carcinoma	1/3	4 (3.4)	17.0±36.25
Adenoid cystic carcinoma	26/29	55 (46.6)	2.2±48.70
Basal cell adenocarcinoma	-/2	2 (1.7)	5.65±35.00
Salivary duct carcinoma	2/1	3 (2.5)	8.5±51.00
Myoepithelial carcinoma	2/2	4 (3.4)	5.5±74.30
Carcinoma ex-pleomorphic adenoma	1/2	3 (2.5)	12.7±58
Polymorphous low grade adenocarcinoma	2/1	3 (2.5)	3.5±48.50
Squamous cell carcinoma	1/7	8 (6.8)	17.3 ±63.75
Adenocarcinoma not otherwise specified	-/1	1 (0.9)	65.00
Total	48/64	118 (100)	18.9±50.60

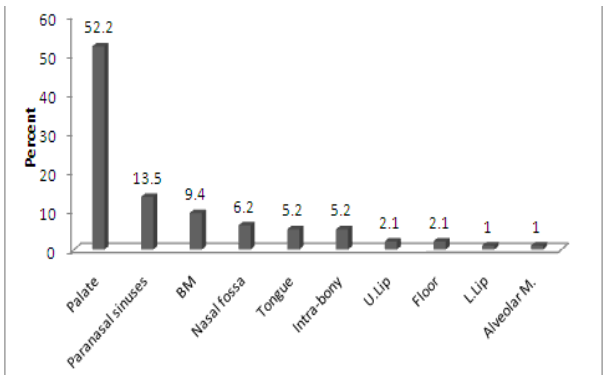

Figure 1. Incidence of Benign and Malignant Tumors in Various Anatomic Locations

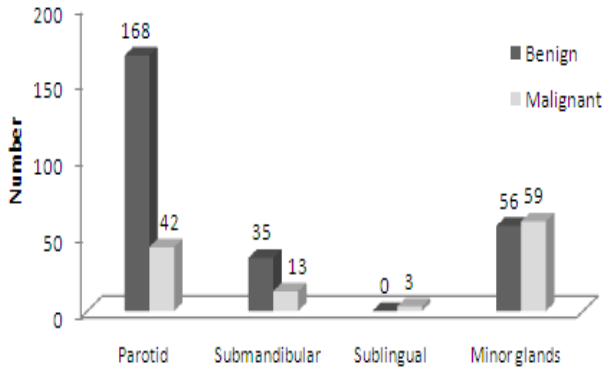

Figure 2. Distribution of Salivary Gland Tumors in Minor Salivary Glands

Discussion

SGTs probably are the most complex human neoplasia (Dardick et al., 1992), accounting for 3-10% of all head and neck tumors (Ansari, 2007; Jones et al., 2008). During 2005-2009, we discovered that 2.7% of all biopsied materials and 39% of oral and maxillofacial tumors were SGTs. This high rate of reported cases attributes to the nature of study situation (Khalili hospital) that is the largest referral center for the maxillofacial tumors in southern Iran. Although increasing sun- exposure might be a cause. The benign/ malignant ratio was 2.1:1 with prominent involvement of major glands. This ratio varies from 1.1:1 in Africa to 5.6:1 in European reports (Ma`aita et al., 1999; Satko et al., 2000; Vuhahula, 2004; Ito et al, 2005; Lima et al., 2005; Li et al., 2008; Subhashraj, 2008). Ansari has reported this ratio 2.2:1 in western Iran (Ansari, 2007). All these reports have confirmed greater involvement of major glands with parotid gland being the greatest. The majority of tumors in parotid glands were benign and there was a reverse relation between size of the major glands and the rate of malignancy.

The minor salivary glands were the second common site of involvement, engaged in 28.5% of all tumors. In minor salivary glands, palatal area was the region with more involvement. Other studies in Iran and other countries also reported that 9-23% of all SGTs arise from minor glands, majority of them in the palate (Spiro, 1986; Rahrotaban et al., 1995; Valizadeh and Mohagheghi, 1995; Ansari, 2007; Atarbashi-Moghadam et al., 2010; Vaidya et al., 2012). The tumors arising from minor glands had a tendency to become malignant. This finding also was seen in the large series of minor SGTs in Tehran,Iran center (Daneshvar et al., 2011). However data from Pennsylvania, USA and California have shown predominance of benign tumors (Yih et al., 2005; Buchner et al., 2007; Pires et al., 2007). These different results are attributable to the racial factors, as well the place where cancer had been registered, whether hospital or dental school.

PA undoubtedly is the most common SGTs. As, similar to the present study, all researchers from other parts of Iran and worldwide have noticed that this neoplasm stands for 40.4-89.9% of all SGTs (Valizadeh and Mohagheghi, 1995; Ma`aita et al., 1999; Satko et al., 2000; Vargas et al., 2002; Vuhahula, 2004; Ito et al, 2005; Lima et al., 2005; Otoh et al., 2005; Ansari, 2007; Li et al., 2008; Subhashraj, 2008; Atarbashi-Moghadam et al., 2010). Warthin's tumor was the second common benign tumor denoted 10.5% of all cases with Male to Female ratio of 10: 3. Other studies in Denmark and Pennsylvania reported a high incidence of this tumor (about 30% of parotid tumors), however some populations such as Africans were affected rarely (Poulsen et al., 1987; Monk and Church, 1992; Vuhahula, 2004). Male/ female is decreasing during recent years. As smoking is a risk factor for development of this neoplasm, most probably increasing female smokers is the cause (Monk and Church, 1992).

ACC was the most common malignant tumor followed by MEC. This finding is consistent with researches in Brazil, India, Africa and Bratislava (Satko et al., 2000; Vuhahula, 2004; Lima et al., 2005; Subhashraj, 2008). Also, authors have reported ACC being the most common malignancy in a large group of patients in Iran center (Khalili and Salamat, 2009).

However, most of the studies on Brazilian, Libyan and Chinese populations and also those enrolled in western and center Iran have shown that MEC occurs with more frequency (Ma`aita et al., 1999; Vargas et al., 2002; Ito et al, 2005; Otoh et al., 2005; Ansari, 2007; Li et al., 2008; Daneshvar et al., 2011). Attarbashi et al in south of Iran, have demonstrated that MEC and ACC were the most common malignant tumors arising from major and minor salivary glands, respectively (Atarbashi-Moghadam et al., 2010). These data indicate a racial and geographic variation in relative incidence of SGTs.

The mean age of patients in benign neoplasms was 37.7 years. This result is similar to the other studies which have reported a range from 33.5-47.7 (Rahrotaban et al., 1995; Satko et al., 2000; Vargas et al., 2002; Vuhahula, 2004; Ansari, 2007; Li et al., 2008). Malignant tumors showed a mean age of 50.7 years which was 13 years higher than benign tumors. The difference between mean age of patients with benign and malignant tumors have been reported from 3 years in Chinese to 10 years in African population (Luukkaa et al., 2005; Li et al., 2008), but Vargas et al. have found an almost equal average of age in malignant and benign neoplasms in Brazil (Vargas et al., 2002). This difference that was noticeable in our study is related to the lower age of our patients with benign tumors. Also, earlier studies in China and Sri Lanka have shown a lower age range in malignant group in comparison with our results (Li et al., 2008; Tilakaratne et al., 2009).

The malignant tumors occurred in males 1.2 times more than females. Also, overall male predominance was observed. This result is consistent with Li's et al study in China (Li et al., 2008). Malignant tumors also had a tendency to males in Brazil, Fanland, India and other studies in Iran (Rahrotaban et al., 1995; Luukkaa et al., 2005; Hashemi et al., 2007; Li et al., 2008; Subhashraj, 2008; Atarbashi-Moghadam et al., 2010; Daneshvar et al., 2011) while Some studies have indicated opposite results (Al-Khateeb and Ababneh, 2007; Tilakaratne et al., 2009; Atarbashi-Moghadam et al., 2010). Moreover, Licitro et al stated an equal gender involvement (Licitra et al., 2003). With a comprehensive review of large series of SGTs in various reports from Iran and worldwide, it seems that benign tumors occurs more commonly in females, but malignant entities have a propensity to involve male patients.

In conclusion, although SGTs, in this study, demonstrated many similarities in clinical course to the other parts of the world and other parts of Iran, our study has come to a few individual results: Overall incidence was higher than earlier studies. A slightly tendency to males was seen, although benign tumors affected female patients with more frequency. ACC was more observable in southern Iran and malignant neoplasms were detected at least one decade later than benign ones. These data exhibited a special clinical profile of SGTs in southern Iran in comparison with reports from other countries and other parts of Iran. Authors hope that this silhouette could help physician, surgeons and pathologists for more accurate diagnosis, management and early treatment.

Acknowledgements

This study is funded by the office of vice chancellor for research of Shiraz University of Medical Sciences. This article is partly relevant thesis of Dr. Nasibeh Afandak. The authors thank Dr. Shahram Hamedani from the Dental Research Development Center for help with the English in the manuscript. Also, authors thank Dr. Marzieh Hamzavi for help in data collection.

References

Al-Khateeb TH, Ababneh KT(2007). Salivary tumors in north Jordanians: a descriptive study. *Oral Surg Oral Med Oral Pathol Oral Radiol Endod*, **103**, 53-9.

Ansari M (2007). Salivary gland tumors in an Iranian population: a retrospective study of 130 cases. *J Oral Maxillofac Surg*, **65**, 2187-94.

Atarbashi-Moghadam S, Atarbashi-Moghadam F, Dadfar M (2010). Epithelial salivary gland tumors in Ahvaz, Southwest

of Iran. *J Dent Res Dent Clin Dent Prospect*, **4**, 120-3.

Buchner A, Merrell PW, Carpenter WM (2007). Relative frequency of intra-oral minor salivary gland tumors: a study of 380 cases from northern California and comparison to reports from other parts of the world. *J Oral Pathol Med*, **36**, 207-14.

Daneshvar S, I Moshref M, Eshghyar N, et al (2011). Intra-oral minor salivary gland tumors: a Clinicopathological Study of 412 cases. 89th General Session and Exhibition of the IADR, San Diego Convention Center, California, USA, March 17.

Dardick I, Burford-Mason AP, Garlick DS, et al (1992). The pathobiology of salivary gland.II. Morphological evaluation of acinic cell carcinomas in the parotid gland of male transgenic (MMTV/v-Ha-ras) mice as a model for human tumors. *Virch Arch A Pathol Anat*, **421**, 105-13.

Hashemi P, Zarei MR, Chamani G, et al (2007). Malignant salivary glands tumors in Kerman province: a retrospective study. *Dent Re J*, **4**, 4-10.

Ito FA, Ito K, Vargas PA, et al (2005). Salivary gland tumors in Brazillian population: a retrospective study of 496 cases. *Int J Oral Maxillofac Surg*, **34**, 533-6

Jones AV, Craig GT, Speight PM, et al (2008). The range and demographics of salivary gland tumors diagnosed in a UK population. *Oral Oncol*, **44**, 407-17.

Kayembe MK, Kalengayi MM (2002). Salivary gland tumours in Congo (Zaire). *Odontostomatol Trop*, **25**, 19-22.

Khalili M, Salamat F (2009). A 20-year retrospective study of salivary gland adenoid cystic carcinoma in a sample of Iranian patients. *J Dent of Tehran Univ of Med Sci*, **6**, 1-5.

Li LJ, Li Y, Wen YM, et al (2008). Clinical analysis of salivary gland tumor in West China in past 50 years. *Oral Oncol*, **44**, 187-92

Licitra L, Grandi C, Prott FJ, et al (2003). Major and minor salivary glands tumours. *Crit Rev Oncol Hematol*, **45**, 215-25.

Lima SS, Soares AF, de Amoriom RF, et al (2005). Epidemiologic profile of Salivary gland tumors: analysis of 245 cases. *Braz J Otorrinolaringol*, **71**, 335-40.

Luukkaa H, Klemi P, Leivo I, et al (2005). Salivary gland cancer in Finland 1991-96: an evaluation of 237 cases. *Acta Otolaryngol*, **125**, 207-14.

Ma`aita JK, Al-Kaisi N, Al-Tamimi, et al (1999). A. Salivary gland tumors in Jordan: a retrospective study of 221 patients. *Croat Med J*, **40**, 539-42.

Monk JS Jr, Church JS (1992). Warthin's tumor: a high incidence and no sex predominance in Central Pennsylvania. *Arch Otolaryngol Head Neck Surg*, **118**, 477-88.

Otoh EC, Johnson NW, Olasoji H, et al (2005). Salivary gland neoplasm's in Maiduguri, north-eastern Nigeria. *Oral Dis*, **11**, 386-91

Pires FR, Pringle GA, de Almeida OP, et al (2007). Intra-oral minor salivary gland tumors: a clinicopathological study of 546 cases. *Oral Oncol*, **43**, 463-70.

Poulsen P, Jorgensen K, Grontved A (1987). Benign and malignant neoplasms of the parotid gland: incidence and histology in the Danish county of Funen. *Laryngoscope*, **97**, 102-4.

Rahrotaban S, Masoomi P, Moradi M, et al (2009). Frequency of salivary gland tumors in two referral center of Qazvin university of Medical sciences from 1999-2009. *J Res Dent Sci*, **2**, 27-31.

Satko I, Stanko P, Longauerova I (2000). Salivary gland tumors treated in the stomatological clinics in Bratislava. *J Craniomaxillofac Surg*, **28**, 56-61.

Shishegar M, Ashraf MJ, Azarpira N, et al (2011). Salivary gland tumors in maxillofacial region: a retrospective study of 130 cases in a southern Iranian population. *Patholog Res Int*, **50**, 1-5.

Spiro RH (1986). Salivary neoplasms: overview of a 35-year experience with 2807 patients. *Head Neck Surg*, **8**, 177-84.

Subhashraj K (2008). Salivary gland tumors: a single institution experience in India. *Br J Oral and Maxillofac Surg*, **46**, 635-8.

Tilakaratne WM, Jayasooriya PR, Tennakoon TM, et al (2009). Epithelial salivary tumors in Sri Lanka: a retrospective study of 713 cases. *Oral Surg Oral Med Oral Pathol Oral Radiol Endod*, **108**, 90-8.

Vaidya AD, Pantvaidya GH, Metgudmath R, et al (2012). Salivary gland tumors of the oral cavity: a case series with review of literature. *Cancer Res Ther*, **8**, 111-5.

Valizadeh Y, Mohagheghi MA (1995). Review of 103 cases of minor salivary gland tumors. *Acta Medica Iranica*, **33**, 22-6.

Vargas PA, Gerhard R, Aranjo Filho VJ, et al (2002). Salivary gland tumors in Brazilian population: a retrospective study of 124 cases. *Rev Hosp Clin Fac Sao Paulo*, **57**, 271-6.

Vuhahula EA (2004). Salivary gland tumors in Uganda: clinical pathological study. *Afr Health Sci*, **4**, 15-23.

Yih WY, Kratochvil FJ, Stewart JC (2005). Intraoral minor salivary gland neoplasms: review of 213 cases. *J Oral Maxillofac Surg*, **63**, 805-10.