

Tracheal Stenosis after Tracheostomy Treated Successfully with Papillotome Electrocautery

Sun Hee Oh, M.D.¹, Seong Ju Lee, M.D.¹, Dae Sung Kim, M.D.¹, Moon Jun Na, M.D.¹, Eugene Choi, M.D.¹, Sun Jung Kwon, M.D.¹, Hyun Min Cho, M.D.² and Ji Woong Son, M.D.¹

Departments of ¹Internal Medicine and ²Cardiovascular Surgery, Konyang University Hospital, Konyang University College of Medicine, Daejeon, Korea

A 39-year-old woman presented with symptoms of dyspnea. Ten years previously, she had received a tracheostomy because of the decision to not continue taking an anticonvulsant drug. Presently, chest computed tomography showed diffuse stenosis and focal web at the cervical trachea. We performed bronchoscopy and found a two-thirds reduction of the upper trachea due to the web-like fibrotic stenosis. Papillotome electrocautery removed the stenotic lesion. Endobronchial electrocautery is a valuable tool with potential for therapy of an endobronchial obstructing airway lesion. We report this case to introduce the successful treatment with papillotome electrocautery.

Keywords: Bronchoscopy; Electrocoagulation; Tracheal Stenosis

Introduction

Central airway stenosis is seriously impaired by severe dyspnea, which produces a sense of suffocation or even respiratory failure. The most common etiology for acquired benign tracheal stenosis is tracheal intubation or tracheostomy^{1,2}. Other causes of tracheal stenosis are trauma; chronic inflam-

matory diseases including amyloidosis, sarcoidosis, relapsing polychondritis; chronic granulomas; benign or malignant neoplasm; and collagen vascular diseases including tracheopathia osteoplastica and Wegener granulomatosis. Idiopathic tracheal stenosis is a rare disease characterized by an inflammatory cicatricial stenosis at the level of the cricoid and upper trachea³. In Korea, the most common etiology for tracheal stenosis is endotracheal intubation. Other causes are obstructive fibrinous tracheal pseudomembrane, secondary to burn inhalation injury, obstruction by malignant tumor, tuberculosis and foreign body within the trachea⁴.

Trachea stenosis is divided into simple and complex types. The simple type in turn constitutes web-like stenosis and granulation. In the complex type, the most important issue is the destruction of tracheal cartilage. Intra-tracheal clean-up will not solve the problem⁵.

The management of benign tracheal stenosis varies with the type and extent of the disease and depends upon the age and co-morbidities of the patient⁶. The treatment of tracheal stenosis involves surgery or bronchoscopy. Endoscopy is popular to treat obstructive lesions in stenosis of the central airway⁷.

We present a case of tracheal stenosis that was successfully treated with flexible bronchoscopy with papillotome electrocautery.

Address for correspondence: Ji Woong Son, M.D.

Department of Internal Medicine, Konyang University Hospital, Konyang University College of Medicine, 158 Gwanjeodong-ro, Seo-gu, Daejeon 302-718, Korea

Phone: 82-42-600-8817, Fax: 82-42-600-9090

E-mail: sk1609@hanmail.net

Address for co-correspondence: Hyun Min Cho, M.D.

Department of Cardiovascular Surgery, Konyang University Hospital, Konyang University College of Medicine, 158 Gwanjeodong-ro, Seo-gu, Daejeon 302-718, Korea

Phone: 82-42-600-6927, Fax: 82-42-600-9090

E-mail: csking1@kyuh.ac.kr

Received: Mar. 12, 2013

Revised: Apr. 25, 2013

Accepted: May 18, 2013

©It is identical to the Creative Commons Attribution Non-Commercial License (<http://creativecommons.org/licenses/by-nc/3.0/>).

Copyright © 2013

The Korean Academy of Tuberculosis and Respiratory Diseases.

All rights reserved.

Case Report

A 39-year-old woman was admitted to our Department of Cardiothoracic Surgery because of dyspnea. Twenty years previously, she underwent surgery for a diagnosed brain lesion. Since then she had taken anticonvulsant medication.

The seizure attack developed after she stopped taking the anticonvulsant drug due to pregnancy. A tracheostomy was performed. Since then, dyspnea had persisted. She had no relevant family history. Physical examination revealed stridor and a wheezing sound on both lung fields. Laboratory tests were within normal range, except for decreased hemoglobin

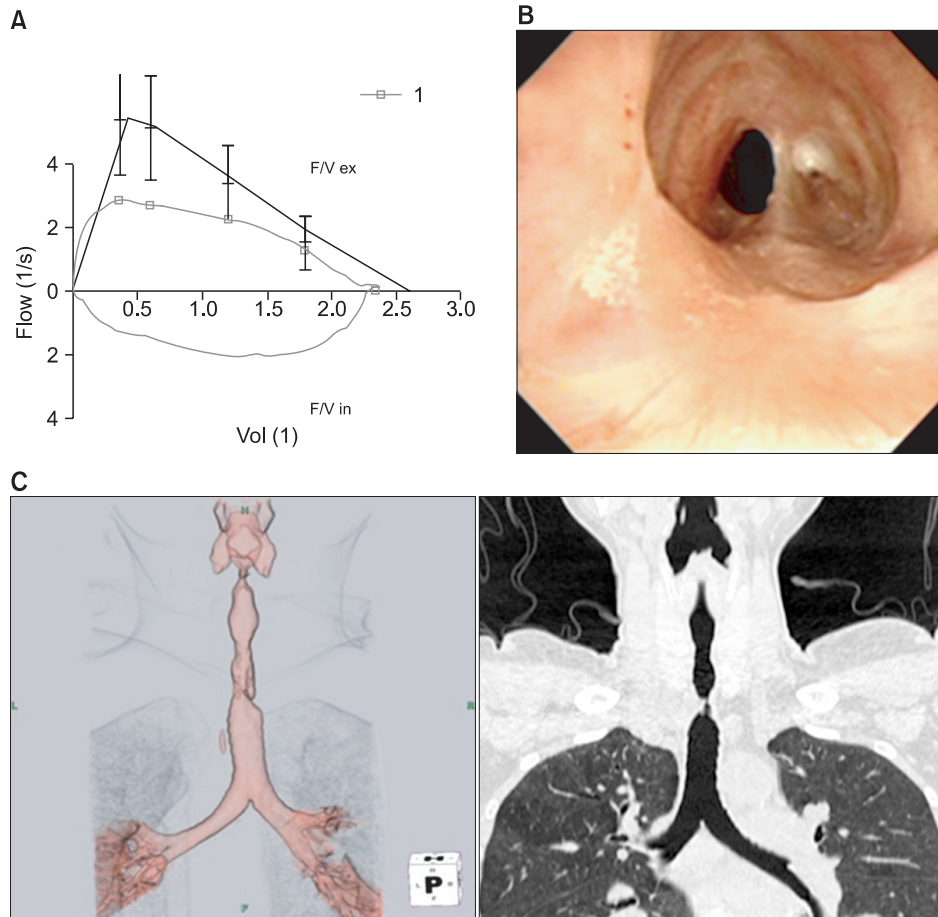


Figure 1. Initial pulmonary function test, bronchoscopy and chest computed tomography (CT) image. (A) Flow volume curve showed fixed obstructed pattern (forced expiratory volume in one second [FEV₁], 89.7%; FEV₁/forced vital capacity, 86.47%). (B) Bronchoscopy revealed two-thirds narrowing of upper trachea due to web-like fibrotic stenosis. (C) Chest CT showed diffuse stenosis and focal web at the cervical trachea.

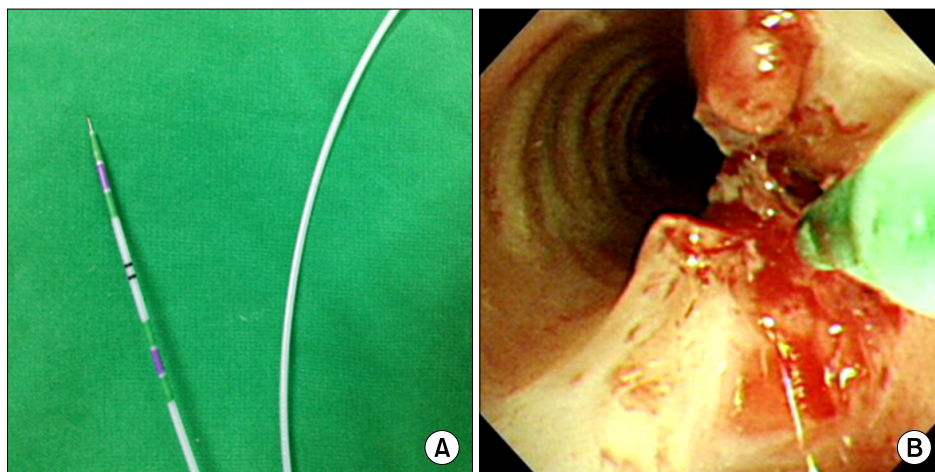


Figure 2. Treatment of stenosis by needle knife (A) and papillotome electrocautery (B).

level (9.9 g/dL). Pulmonary function test indicate fixed obstructed pattern (Figure 1A). Flexible bronchoscopy was performed, which revealed the two-third narrowing of the upper trachea due to web-like fibrotic stenosis (Figure 1B). A chest computed tomography (CT) revealed diffuse stenosis and focal web at the cervical trachea (Figure 1C). We tried to treat the stenosis with papillotome electrocautery. The patient was discharged and followed-up in the outpatient department. After 2 weeks, we performed bronchoscopy and pulmonary function tests for follow-up. Follow-up bronchoscopy revealed persistence of mild web type stenosis. Follow-up pulmonary function test still indicated fixed obstructed pattern. So, the stenosis was again treated with the needle knife approach (Figure 2).

After 2 months, a flow volume curve showed a normal pattern (Figure 3A). Bronchoscopy revealed ulcerative lesion, but improved stenosis (Figure 3B). CT showed the long stenosis of the cervical trachea was decreased (Figure 3C). The patient has been followed-up regularly on an outpatient basis.

Discussion

Tracheal stenosis is defined as the cicatricial narrowing of

the endotracheal lumen. Surgical resection and end-to-end anastomosis is still considered to be the optimal treatment for a young patient presenting with symptomatic tracheal stenosis. To minimize complications, curative surgery is proposed only for selected patients in good neurological, cardiovascular, and respiratory condition. Accurate preoperative work-up of coexisting conditions and anatomical features of the stenosis is essential. To prepare the patients for surgery, repeated mechanical dilatation and/or laser resection is often necessary⁸.

Immediate postoperative complications include inflammatory edema at the anastomosis site, respiratory distress by laryngeal paralysis, and mediastinal emphysema. Early complications include dyspnea by unilateral recurrent palsy, swallowing disorders by lowering of the larynx, suture line disruption by local infection, and brachiocephalic artery trunk rupture by suture irritation. Late complications include granulation tissue formation with obstruction⁹.

For elderly subjects or for patients with significant underlying co-morbidities, endoscopic treatment should be considered³. Neodymium:yttrium-aluminium-garnet (Nd:YAG) laser can provide palliative relief in symptomatic patients with tracheal stenosis. Lasers use light energy that is transformed into heat as it reacts with tissue, allowing for tissue carbonization or cutting as well as for hemostasis. Though laser gives the

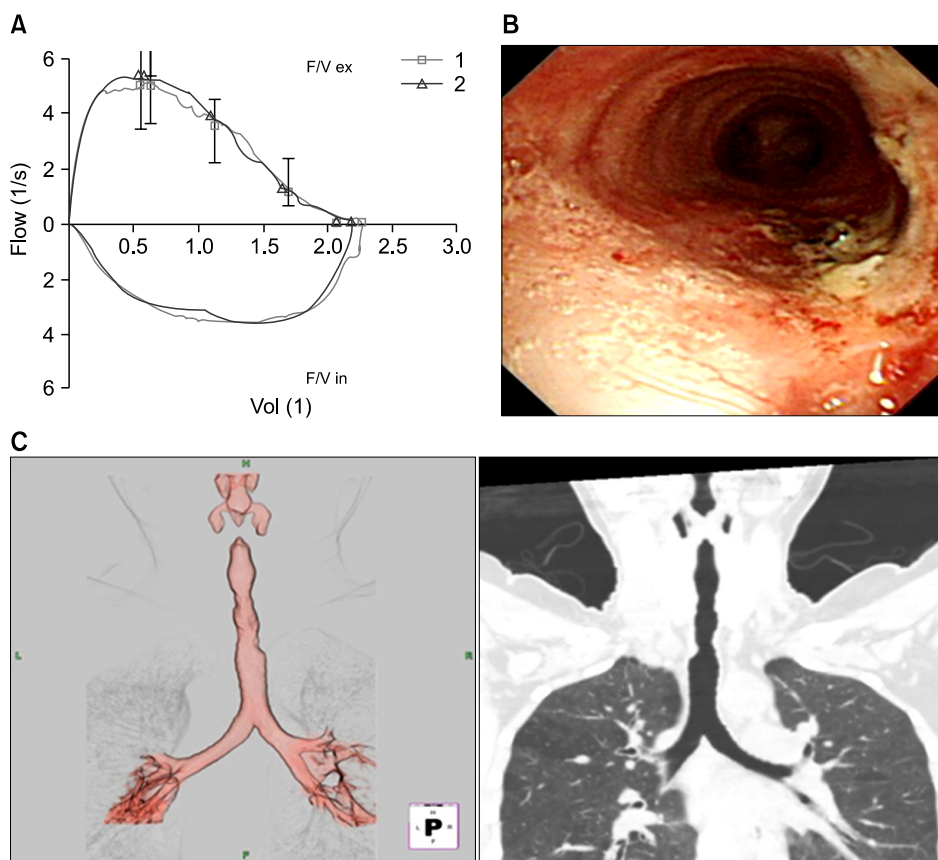


Figure 3. Two-month post-operative findings. (A) Flow volume curve showed normal pattern. (B) Bronchoscopy revealed the improvement of tracheal stenosis. (C) Chest computed tomography showed the tracheal obstruction was completely removed.

best results in lesions of short length located in the trachea, mainstem or proximal lower lobe bronchi which are easily accessible to the rigid bronchoscope, the use of flexible bronchoscope has expanded the reach to more distal lesions¹⁰.

Nd:YAG laser can be used, not only in obstructing malignant lesions, but also for benign tumors, tracheal stenosis and even for removal of granulation tissue. Large case studies by Toty et al.¹¹ and Dumon et al.¹² demonstrated good results with minimal complications and further confirmed the role of Nd:YAG laser in interventional bronchoscopy. Adequate visualization of the target and adjacent structures is imperative for successful treatment with minimal complications. The advantages of Nd:YAG laser application are hemostasis, high precision, reduced instrumentation at the treatment site, minimization of the risk of infection, and minimal trauma of the surrounding tissue. But the Nd:YAG laser is very expensive, so the special facilities necessary for safe laser application are not available in every hospital.

Electrocautery is also used for obstructing tracheal lesions. Electrocautery uses high frequency alternating current to produce heat. As the tissue temperature rises, cellular water evaporates and cellular constituents break down chemically, followed by cell or tissue vaporization. Depending on the power setting, this may result in coagulation, cutting, or vaporization.

One study confirmed that compared with the Nd:YAG laser, electrocautery seems equally effective for debulking intraluminal tumors¹³. Electrocautery is common in surgery and gastroenterology. Electrocautery equipment differs in effectiveness and generating power, so we cannot accurately predict their cautery effect. Electrocautery can cause perforation more than Nd:YAG laser treatment and the treatment time is longer. Other reported complications include endobronchial fires, hemoptysis, hemorrhage, and aspiration pneumonia¹⁴. Electrosurgery is contraindicated in a case when compression is caused by extrinsic force or in patients with pacemaker¹⁵. But electrocautery equipment is less expensive, the application technique is simple, and it is more easily accessible for emergency use in most hospitals. Coulter and Mehta¹⁶ reported endobronchial electrosurgery can be performed safely in the outpatient setting and is an effective procedure in polypoid morphology and the lesion attached airway by a stalk. The successful rate was 89% (42/47). No major complications were encountered.

In conclusion, electrocautery seems more cost effective than the Nd:YAG laser for palliative bronchoscopic intervention to tracheal stenosis. Based on this case, papillotome electrocautery via flexible bronchoscopy could be considered as first option for the treatment of web type tracheal stenosis.

References

1. Grillo HC, Donahue DM. Post intubation tracheal stenosis. *Semin Thorac Cardiovasc Surg* 1996;8:370-80.
2. Wain JC. Postintubation tracheal stenosis. *Chest Surg Clin N Am* 2003;13:231-46.
3. Rahman NA, Fruchter O, Shitrit D, Fox BD, Kramer MR. Flexible bronchoscopic management of benign tracheal stenosis: long term follow-up of 115 patients. *J Cardiothorac Surg* 2010;5:2.
4. Kim HJ, Kim SW, Lee HY, Kang HH, Kang JY, Kim JS, et al. Clinical experience of rigid bronchoscopy in single center. *Tuberc Respir Dis* 2012;72:486-92.
5. Jabbarjarani H, Kiani A, Sheikhi N. Argon plasma coagulation in treatment of post intubation tracheal stenosis. *J Lasers Med Sci* 2011;2:49-53.
6. Bricchet A, Verkindre C, Dupont J, Carlier ML, Darras J, Wurtz A, et al. Multidisciplinary approach to management of postintubation tracheal stenoses. *Eur Respir J* 1999;13:888-93.
7. Seijo LM, Serman DH. Interventional pulmonology. *N Engl J Med* 2001;344:740-9.
8. Bisson A, Bonnette P, el Kadi NB, Leroy M, Colchen A, Personne C, et al. Tracheal sleeve resection for iatrogenic stenoses (subglottic laryngeal and tracheal). *J Thorac Cardiovasc Surg* 1992;104:882-7.
9. Hadi U, Hamdan AL. Diagnosis and management of tracheal stenosis. *J Med Liban* 2004;52:131-5.
10. Mohan A, Guleria R, Mohan C, Sharma R. Laser bronchoscopy: current status. *J Assoc Physicians India* 2004;52:915-20.
11. Toty L, Personne C, Colchen A, Vourc'h G. Bronchoscopic management of tracheal lesions using the neodymium yttrium aluminium garnet laser. *Thorax* 1981;36:175-8.
12. Dumon JF, Reboud E, Garbe L, Aucomte F, Meric B. Treatment of tracheobronchial lesions by laser photoresection. *Chest* 1982;81:278-84.
13. Boxem T, Muller M, Venmans B, Postmus P, Sutedja T. Nd-YAG laser vs bronchoscopic electrocautery for palliation of symptomatic airway obstruction: a cost-effectiveness study. *Chest* 1999;116:1108-12.
14. Sheski FD, Mathur PN. Endoscopic treatment of early-stage lung cancer. *Cancer Control* 2000;7:35-44.
15. Ernst A, Silvestri GA, Johnstone D; American College of Chest Physicians. Interventional pulmonary procedures: guidelines from the American College of Chest Physicians. *Chest* 2003;123:1693-717.
16. Coulter TD, Mehta AC. The heat is on: impact of endobronchial electrosurgery on the need for Nd-YAG laser photoresection. *Chest* 2000;118:516-21.