

A Case of the Laryngopharyngeal Burn Caused by A Microwave-Heated Egg Bite

Seong Jun Won, MD¹ and Seung Hoon Woo, MD^{1,2}

¹Department of Otolaryngology; ²Institute of Health Sciences, Gyeongsang National University, Jinju, Korea

= Abstract =

Nowadays, microwave ovens are commonly used for cooking. However, the cooking certain food in microwave ovens can be hazardous. It has been reported that the heating eggs in a microwave oven can cause an explosion and injuries. The exploding eggs can cause burn injury of face, neck, eyelid, pharynx and larynx. Direct thermal damage to the larynx after swallowing microwave-heated eggs is rare. The authors report a larynx thermal injury due to microwave-heated eggs and review the cause and the prevention methods of exploding eggs.

KEY WORDS : Microwave · Egg · Pharynx · Larynx · Burn.

Introduction

A microwave oven is one of the most widely used cooking appliances. However, the cooking food in a microwave sometimes cause an explosion. There are several types of injuries caused by a microwaved food. According to the investigation on burn injuries related to microwave cooking in 1986, 4 cases among 41 cases were caused by microwave-heated eggs.¹⁾ Microwave-heated eggs can be explosive owing to 1) the difference in the temperature and 2) the pressure between the inside and the outside of eggs.²⁾ Although microwave oven manufacturers warn about the risk and explain that several holes must be made on eggs when heating eggs in a microwave oven in the user's manual, few customers attentively read and follow this instruction. The authors have experienced a case of the larynx burn caused by microwave-heated eggs, thus, report the case with a literature review.

Case Report

A 51 year old female attended to the emergency department due to throat pain and swallowing difficulty. The symptoms started after a microwave-heated egg was burst into her oral

cavity when she tried to bite it. The patient was unable to swallow any drinks and foods including water due to severe throat pain and also complained of breathing difficulty. She didn't have any specific medical history or was taking any medications on admission. A laryngoscopy showed injection, swelling and ulcerative lesions of palate and oropharynx (Fig. 1A). Although the mucosa of bilateral arytenoid cartilages and vocal cord were edematous, the vocal cord was in the normal action (Fig. 1B). There weren't any signs of the tracheal stenosis and her vital signs were also within the normal range.

Intravenous antibiotics and steroid were administered and the pain was controlled with prescribed analgesia and mouthwash. After several days' treatment, the symptoms were improved and the patient was discharged after 10 days of hospitalization (Fig. 1C). She was followed up in the outpatient department after the discharge 2 month later and the burn was completely healed without any complications (Fig. 1D).

Discussion

As the use of microwave ovens become more common, the burn injuries caused by microwave-heated food also become more prevalent. It is reported that these burn injuries are often occurred on skin, facial area and around eyes.^{1,2)} However, the larynx burn due to hot foods and drinks is rarely occurred.³⁾ The most of reported burn cases are occurred in pediatric patients.^{4,5)} When a burn injury occurs, the mucosa of larynx become edematous. In particular, edema can easily occur in the mucosa of hypopharynx, epiglottis and arytenoid cartilag-

Received: August 7, 2013 / Accepted: November 13, 2013

Address for correspondence: Seung Hoon Woo, MD, Department of Otolaryngology, Gyeongsang National University, 79 Gangnam-ro, Jinju 660-702, Korea

Tel: 055-750-8173, Fax: 055-759-0613

E-mail: lesaby@hanmail.net

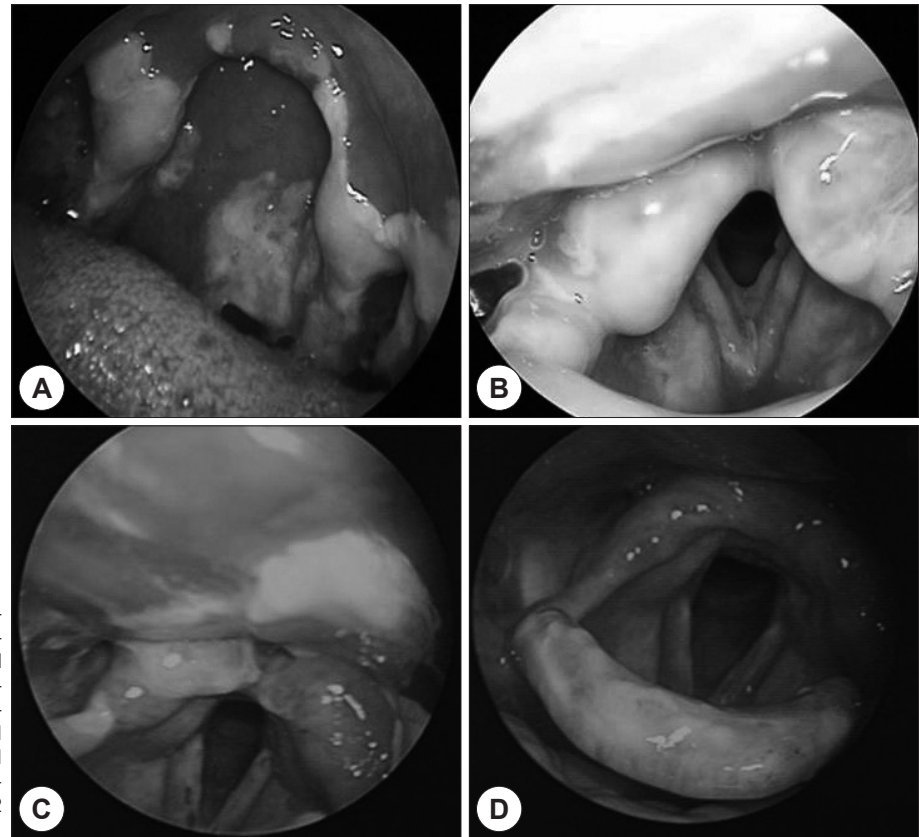


Fig. 1. Larynx burn due to a microwave-heated egg. A : The photograph showing Injection, swelling and ulcerative lesions of palate, oropharynx due to thermal injury. B : The swelling of both arytenoids and vocal cord due to thermal injury. C : The healed larynx after 10 days later. D : The larynx was nearly normalized after 2 month later.

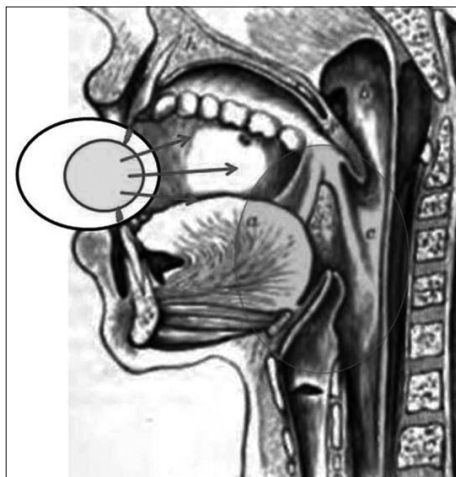


Fig. 2. A microwave-heated egg had a high pressure. The heated egg was exploded when it bite. The burning injury can occur in oral cavity, pharynx and larynx.

es because the mucosa of these areas is covered with loose connective tissues.⁶⁾ Therefore, the subsequent symptoms or radiological findings can be similar to acute epiglottitis.^{7,8)} Therefore, a careful history taking is crucial in order to differentiate between two diagnoses. And the accompanied burn injuries on the face, lips and oral cavity will help to differentiate the di-

agnoses.³⁾

A microwave oven creates heat by vibrating molecules of foods and the heat created by a microwave oven is affected by the water content in foods, the conductivity and the frequency.²⁾ In this case, it was estimated that the egg was became explosive when the patient tried to bite it because the internal temperature of the egg was higher than the external temperature. Moreover, the burn risk of a soft-boiled egg becomes higher because its yolk is in an extremely hot liquid status (Fig. 2).

Heating foods in a microwave oven is quick and convenient but it carries a potential risk of the burn to digestive organs such as the oral cavity, the laryngeal area and the esophagus due to the poor distribution of temperature.⁹⁾ Burn injuries caused by the microwave-heated foods is usually a minor burn, therefore, active early treatments can cure the damage without any complications.²⁾ Although the majority of the burn injury is a minor burn, it is important to be aware of the warnings before using a microwave oven. Especially, it is important to prevent an explosion by piercing hole on eggs prior to cooking.

The authors reported a rare case of burn injury caused by a microwave-heated egg which diagnosed and cured at the early stage.

REFERENCES

- 1) Exploding eggs. *N Engl J Med* 1991;325:1749.
- 2) Wolf Y, Adler N, Hauben DJ. Exploding microwaved eggs--revisited. *Burns* 2001;27:853-5.
- 3) Ford GR, Horrocks CL. Hazards of microwave cooking: direct thermal damage to the pharynx and larynx. *J Laryngol Otol* 1994;108:509-10.
- 4) Dye DJ, Milling MA, Emmanuel ER, Craddock KV. Toddlers, tea-pots, and kettles: beware intraoral scalds. *BMJ* 1990;300:597-8.
- 5) Garland JS, Rice TB, Kelly KJ. Airway burns in an infant following aspiration of microwave-heated tea. *Chest* 1986;90:621-2.
- 6) Miller RP, Gray SD, Cotton RT, Myer CM 3rd. Airway reconstruction following laryngotracheal thermal trauma. *Laryngoscope* 1988;98:826-9.
- 7) Kulick RM, Selbst SM, Baker MD, Woodward GA. Thermal epiglottitis after swallowing hot beverages. *Pediatrics* 1988;81:441-4.
- 8) Harjacek M, Kornberg AE, Yates EW, Montgomery P. Thermal epiglottitis after swallowing hot tea. *Pediatr Emerg Care* 1992;8:342-4.
- 9) Lieberman DA, Keefe EB. Esophageal burn and the microwave oven. *Ann Intern Med* 1982;97:137.