

## RESEARCH ARTICLE

# Roles of mTOR and p-mTOR in Gastrointestinal Stromal Tumors

Jun-Chuan Li, Hong-Yu Zhu\*, Ting-Xuan Chen, Lan-Ying Zou, Xiao-Yan Wang, Hui-Chuan Zhao, Jun Xu

### Abstract

**Objective:** This study aimed to examine the relationship between expression of mammalian target of rapamycin (mTOR) and phosphorylation of mTOR (p-mTOR) protein in the PI3K/Akt/mTOR signaling pathways in gastrointestinal stromal tumors and relationships with clinical factors. **Methods:** Immunohistochemistry was used to detect the expression of the associated proteins mTOR, p-mTOR, and phosphorylation of the tumor suppressor genes PTEN, P27, VEGF, and EGFR in 40 cases of gastrointestinal stromal tumors, with division into a very low and low risk group as well as a moderate and high risk group. **Results:** The positive rate of mTOR and p-mTOR was significantly increased in the moderate and high risk group compared with the very low and low risk group. The difference was statistically significant ( $P < 0.05$ ). When grouped according to size, the positive mTOR expression rate exhibited a statistical difference ( $P < 0.05$ ), which was significantly increased in the group of tumors larger than 5 cm. The difference in the positive mTOR and p-mTOR expression rate exhibited no statistical significance among the PTEN, P27, VEGF, and EGFR expression subgroups ( $P > 0.05$ ). **Conclusion:** The different expressions of mTOR and p-mTOR in the signal transduction pathway of gastrointestinal stromal tumor in the different degree-of-risk groups suggested that the mTOR and p-mTOR of the signal transduction pathway serve an important function in the occurrence and development of gastrointestinal stromal tumors.

**Keywords:** mTOR - p-mTOR - gastrointestinal stromal tumor - signal transduction pathways

*Asian Pac J Cancer Prev*, 14 (10), 5925-5928

### Introduction

The cell proliferation-related signal-transduction pathway of PI3K/Akt/mTOR is involved in the regulation of a variety of cell proliferation and apoptosis functions, thus serving an important function in the occurrence, development, treatment, and outcome of malignant tumors, in which the regulation of the mammalian target of rapamycin (mTOR), phosphorylation of mammalian target of rapamycin (p-mTOR), and phosphorylation of the tumor suppressor gene (PTEN) have very important roles (Grabinski et al., 2012). Activated by the phosphorylation of PI3K/Akt/mTOR, mTOR can affect the cell cycle and regulate apoptosis by mediating the downstream important signal, which is of great significance in the exploration of the signaling pathway and in tumor-targeting therapy (Foster and Fingar, 2010). The mTOR signal pathway is overexpressed in gastric cancer, which might serve an important function in the chemo-resistance of gastric cancer (Al-Batran et al., 2012). The gradually increasing incidence rate of gastrointestinal stromal tumors (GISTs) can be attributed to the difficulty in predicting biological behavior, lack of auxiliary treatment, and higher the recurrence rate after operation (Eisenberg and Pipas, 2012). Reports on mTOR in GIST are rare, such that the

relationship between signal transduction pathways of multiple molecules in GIST remains unclear.

This study discusses the role of p-mTOR, mTOR, and PTEN of the PI3K/Akt/mTOR signaling pathway in the occurrence and development of GIST and attempts to explore the relationship between the mTOR expression and the multiple-molecule factor in GIST.

### Materials and Methods

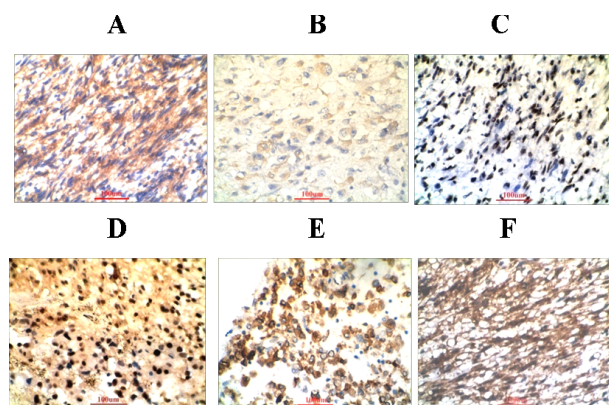
#### *Specimen*

From November 2007 to December 2010, 40 cases of resection specimens in the Department of General Surgery Operation in the First Affiliated Hospital of Yangtze University were reviewed using HE and immunohistochemical sections, and more than two experienced pathologists confirmed the gastrointestinal stromal tumor according to the standards of pathological diagnosis.

#### *GIST Diagnosis Criteria*

Conventional morphology is consistent with GIST diagnosis with the positive immunohistochemistry of CD117, CD34, or Dog-1. If the above three indexes are negative but multiple antibodies are positive, including

Department of Pathology, The First Affiliated Hospital of Yangtze University, Jingzhou, China <sup>†</sup>Equal contributors \*For correspondence: hongyuzhucn@163.com



**Figure 1. Immunohistochemical Expression of mTOR, p-mTOR, EGFR, VEGF, PTEN and P27.** A: mTOR positive in cytoplasm (×200); B: p-mTOR positive in cytoplasm (×200); C: PTEN positive in cytoplasm (×200); D: P27 positive in nucleus (×200); E: EGFR positive in cytoplasm (×200); F: VEGF positive in cytoplasm (×200)

smooth muscle actin (SMA), desmin, neural crest cell antigen protein (S-100), NSE, and CD56, among others, or if both are negative, except for SMA and neurogenic tumor, then the conventional morphology is consistent with GIST diagnosis.

**Grouping**

Clinical data were obtained from medical records, and all specimens in paraffin sections were stained with HE and observed using a microscope. According to The Improved Consensus on Evaluation in the United States National Institutes of Health GIST Risk Degree in 2001 and 2008 (Joensuu, 2008; Grover et al., 2012), 40 cases GIST were graded and then divided into two groups: the very low and low risk group as well as the moderate and high risk group.

**Immunohistochemical analysis**

Using the Envision two-step method, a phosphate buffer instead of the first antibody was taken as the negative control, and known positive pictures were taken as the positive control. In all cases, the expression of mTOR, p-mTOR, PTEN, P27, VEGF, and EGFR were determined through immunohistochemical detection. Mouse anti-human mTOR monoclonal antibody (clone No. 7C10) and p-mTOR (clone 49F9) monoclonal antibody were purchased from Cell Signaling Technology, whereas PTEN (clone 1B4), P27 (clone 28H6), VEGF (clone SP28), EGFR (clone 31G7), and general PV6000 two-step immunohistochemical detection kit were purchased from Beijing Zhongshan Jinqiao Biotech Corp (Guangwainanbinhe Road, Xicheng District, Beijing, China).

For the positive cells, the cytoplasm or nucleus showed brown particles or yellow granules, as evaluated by two pathologists.

**Statistical analysis**

Using SPSS 13 statistical software, the difference in the rates of each group were compared using a Chi-square test, and  $P < 0.05$  was considered statistically significant.

**Table 1. The Relationship Between MTOR and p-mTOR and Other Clinical and Pathological Parameters of Gastrointestinal Stromal Tumors**

| Pathological parameters    | N  | N                            | mTOR | $\chi^2$ | P     |
|----------------------------|----|------------------------------|------|----------|-------|
|                            |    | Positive expression rate (%) |      |          |       |
| Gender                     |    |                              |      |          |       |
| Male                       | 21 | 12                           | 57.1 | 0.382    | 0.536 |
| Female                     | 19 | 9                            | 47.4 |          |       |
| Age (years old)            |    |                              |      |          |       |
| >60                        | 19 | 9                            | 47.4 | 0.382    | 0.536 |
| ≤60                        | 21 | 12                           | 57.1 |          |       |
| Tumor size (cm)            |    |                              |      |          |       |
| >5                         | 19 | 16                           | 68.4 | 14.593   | 0     |
| ≤5                         | 21 | 5                            | 23.8 |          |       |
| NIH grade                  |    |                              |      |          |       |
| The very low and low risk  | 17 | 5                            | 29.4 | 6.32     | 0.012 |
| The moderate and high risk | 23 | 16                           | 64   |          |       |
| Tumor site                 |    |                              |      |          |       |
| Stomach                    | 20 | 12                           | 60   | 0.902    | 0.342 |
| Non stomach                | 20 | 9                            | 45   |          |       |
| PTEN                       |    |                              |      |          |       |
| +                          | 18 | 11                           | 61.1 | 0.973    | 0.324 |
| -                          | 22 | 10                           | 45.5 |          |       |
| EGFR                       |    |                              |      |          |       |
| +                          | 25 | 13                           | 52   | 0.007    | 0.935 |
| -                          | 15 | 8                            | 53.3 |          |       |
| P27                        |    |                              |      |          |       |
| +                          | 28 | 13                           | 46.4 | 1.38     | 0.24  |
| -                          | 12 | 8                            | 66.7 |          |       |
| VEGF                       |    |                              |      |          |       |
| +                          | 31 | 18                           | 58.1 | 1.711    | 0.191 |
| -                          | 9  | 3                            | 33.3 |          |       |

**Results**

**General information**

Among the 40 cases, 21 were males, and 19 were females. The oldest was 81 years old, whereas the youngest was 19 years old, with the average being 54.1 years old. The average age for males was 60.7 years old, whereas that for females was 46.8 years. The largest tumor was 18 cm in diameter, whereas the smallest was 0.5 cm in diameter, with an average diameter of 5.3 cm. Twenty cases of stromal tumors localized in the stomach; the largest tumor is 14 cm in diameter, the smallest is 1 cm in diameter, and the mean diameter is 6.3 cm. Twenty cases stromal tumors occurred in areas other than the stomach (non-gastric site); the maximum diameter is 18 cm, the smallest diameter is 0.5 cm, and the mean diameter is 4.3 cm.

**Immunohistochemistry**

The mTOR, p-mTOR, EGFR, and VEGF proteins were localized in the cytoplasm. The expression of PTEN and P27 was in the nucleus. Positive expression was indicated by brown granules or yellow granules in the cytoplasm or nucleus with diffused distribution, as shown in Figure 1.

**Expression of mTOR and p-mTOR**

Comparing the expression of mTOR and p-mTOR in the gastrointestinal stromal tumor of different groups in terms of gender, age, tumor site, and other clinical

**Table 2. The Relationship Between MTOR and p-mTOR and Other Clinical and Pathological Parameters of Gastrointestinal Stromal Tumors (continues)**

| Pathological parameters    | N  | N  | p-mTOR<br>Positive expression<br>rate (%) | $\chi^2$ | P     |
|----------------------------|----|----|---|----------|-------|
| Gender                     |    |    |   |          |       |
| Male                       | 21 | 10 | 47.6                                      | 1.069    | 0.301 |
| Female                     | 19 | 6  | 31.6                                      |          |       |
| Age (years old)            |    |    |   |          |       |
| >60                        | 19 | 8  | 21.1                                      | 0.067    | 0.796 |
| ≤60                        | 21 | 8  | 38.1                                      |          |       |
| Tumor size (cm)            |    |    |   |          |       |
| >5                         | 19 | 10 | 42.1                                      | 2.406    | 0.121 |
| ≤5                         | 21 | 6  | 28.6                                      |          |       |
| NIH grade                  |    |    |   |          |       |
| The very low and low risk  | 17 | 3  | 17.6                                      | 6.155    | 0.013 |
| The moderate and high risk | 23 | 13 | 56.5                                      |          |       |
| Tumor site                 |    |    |   |          |       |
| Stomach                    | 20 | 10 | 50  | 1.667    | 0.197 |
| Non stomach                | 20 | 6  | 30  |          |       |
| PTEN                       |    |    |   |          |       |
| +                          | 18 | 8  | 44.4                                      | 2.269    | 0.604 |
| -                          | 22 | 8  | 36.4                                      |          |       |
| EGFR                       |    |    |   |          |       |
| +                          | 25 | 10 | 76.9                                      | 0        | 1     |
| -                          | 15 | 6  | 40  |          |       |
| P27                        |    |    |   |          |       |
| +                          | 28 | 10 | 35.7                                      | 0.243    | 0.622 |
| -                          | 12 | 6  | 50  |          |       |
| VEGF                       |    |    |   |          |       |
| +                          | 31 | 14 | 45.2                                      | 1.529    | 0.216 |
| -                          | 9  | 2  | 22.2                                      |          |       |

indicators as well as that in the PTEN, EGFR, P27, and VEGF groups, the difference was not statistically significant ( $P>0.05$ ). Moreover, the expression of p-mTOR in different tumor size groups exhibited no significant difference ( $P>0.05$ ). The difference of the expression of mTOR and p-mTOR between the very low and low risk group and the moderate and high risk group was statistically significant ( $P<0.05$ , Table 1). Moreover, the difference of the expression of mTOR in different tumor size groups was statistically significant ( $P<0.05$ , Table 2).

## Discussion

GIST is the most common stromal tumor to occur in the gastrointestinal, the biological behavior of which is difficult to predict. Some cases of GIST exhibit a clear invasion. However, the majority of cases do not present invasion or tumor rupture, based on which the invasion risk degree and clinical intervention plan can be determined through pathological examination to prevent recurrence (Kee and Zalcborg, 2012).

In the PI3K /Akt /mTOR signal transduction pathway, the activation of mTOR serves an important function in cell proliferation, growth, and differentiation as a central control point. In the middle of the mTOR molecular carboxyl end, a protein kinase domain exists, the structure of which is similar to the PI3K kinase catalytic domain. In the tumor-generation process, the signal transduction

pathway completes the cascade effect through the PI3K product. An important target in the downstream of Akt is mTOR. p-mTOR can activate the downstream end of the 4EBP1 and terminate the inhibition of translation initiation to mediate the progression of the G1 phase (Xu et al., 2012). The high expression of mTOR in tumor tissues in such cases as ovarian cancer, breast cancer, pancreatic cancer, renal cancer, lung cancer, prostate cancer, liver cancer, carcinoma of parotid gland, bile duct cancer, and leukemia (Zhang et al., 2007) may excessively activate the signal transduction pathways, which ultimately causes tumors through different mechanisms (Gnant, 2012). This study investigates whether mTOR and p-mTOR exhibit abnormal expression in GIST and determines their relationship with other clinical factors.

This study shows that the expression of mTOR and p-mTOR is not significantly different in each subgroup according to gender, age, and tumor size, which indicates that such expression has no clear relationship with the aforementioned clinical factors. The difference of expression of mTOR and p-mTOR between the very low and low risk group and the moderate and high risk group was statistically significant ( $P<0.05$ ). Expression was significantly higher in the moderate and high risk group than in the very low and low risk group, and the difference of the expression of mTOR in different tumor size groups was statistically significant ( $P<0.05$ ). Positive expression was high in tumors more than 5 cm in diameter than in smaller tumors, which indicates that tumor size is related to the risk degree classification. We believe that the abnormal expression of mTOR and p-mTOR is related to GIST risk level, which can be used to predict the prognosis of GIST. In the development of GIST, the important function of the PI3K and Akt signaling pathways of mTOR abnormalities is reflected by the expression of mTOR and p-mTOR.

PTEN blockades the activity of Akt and its downstream kinase activity, which can cause apoptosis, and its positive expression rate is closely related to tumor metastasis. The deletion of PTEN protein has the close relationship with the occurrence and development of GIST (Tamguney and Stokoe, 2007; Carracedo and Pandolfi, 2008). P27 can block transitions of the G1/S phase in the cell cycle and can inhibit cell proliferation; thus, the deletion or reduction of P27 protein expression can result in the occurrence of tumor (Shirin et al., 2007; Wang et al., 2010). mTOR can enhance the expression of hypoxia inducible factor HIF-1 $\alpha$  and promote the expression of VEGF, which is closely related to tumor proliferation and metastasis (Benjamin et al., 2011). VEGF has the specific function of promoting endothelial cell proliferation and increasing vascular permeability activity, which is closely related to the proliferation and metastasis of tumor cells, thus serving an important function in tumor growth and metastasis (George et al., 2009).

EGFR promotes DNA synthesis and cell differentiation and proliferation, which serves an important function in the growth, proliferation, and differentiation of cellular physiological processes (Jiang et al., 2012). EGFR is overexpressed in head and neck squamous cell carcinoma, breast cancer, and liver cancer and indicates poor

prognosis, tumor metastasis, and high recurrence rate. EGFR mutation has high frequency in many cancers, and the signal transduction pathway triggered by its excessive activation has a close relationship with tumor pathology and prognosis (Padilla et al., 2008; van der Meel et al., 2012). In sum, in addition to the two important factors mTOR and p-mTOR, the activation of the PI3K/Akt/mTOR signaling pathway is also associated with PTEN, P27, VEGF, and EGFR, among others.

This study found that mTOR and p-mTOR expression was not statistically different in the PTEN, P27, EGFR, and VEGF expression groups, which suggests that in the signaling pathway of GIST, the expression of mTOR and p-mTOR has no clear correlation with the expression of the PTEN, P27, EGFR, and VEGF. Moreover, in the genesis and development of GIST, the abnormal expression of mTOR and p-mTOR in the PI3K/Akt/mTOR signal conduction pathway can be used as an independent factor that serves a certain function. However, the synergistic effect of mTOR and p-mTOR with such factors as PTEN, P27, EGFR, and VEGF remains unclear. Thus, mTOR and p-mTOR expression in GIST serve a certain function in the development of the disease. The result of this study is consistent with those of studies on some malignant tumors (Daniels et al., 2011). Whether the difference between the result of our study from that in the literature may be attributed to the insufficiency of samples has yet to be confirmed.

mTOR and p-mTOR are very important in the signal conduction pathway, and multiple genes promote the progression of GIST. Based on the study of molecular targets in signal transduction pathways, clinical application and individualized treatment may improve the prognosis of GIST. mTOR and p-mTOR may aid in the GIST diagnosis and treatment of targeted genes.

## Acknowledgements

This study were supported by Hubei Provincial Department of education scientific research project (2009 381); scientific research project, the health department of Hubei Province (2009-2010, JX4C15).

## References

- Al-Batran SE, Ducreux M, Ohtsu A (2012). mTOR as a therapeutic target in patients with gastric cancer. *Int J Cancer*, **130**, 491-6.
- Benjamin RS, Schöffski P, Hartmann JT, et al (2011). Efficacy and safety of motesanib, an oral inhibitor of VEGF, PDGF, and Kit receptors, in patients with imatinib-resistant gastrointestinal stromal tumors. *Cancer Chemother Pharmacol*, **68**, 69-77.
- Carracedo A, Pandolfi PP (2008). The PTEN-PI3K pathway of feedbacks and cross-talks. *Oncogene*, **27**, 5527-41.
- Daniels M, Lurkin I, Pauli R, et al (2011). Spectrum of KIT/PDGFR $\alpha$ /BRAF mutations and Phosphatidylinositol-3-Kinase pathway gene alterations in gastrointestinal stromal tumors (GIST). *Cancer Lett*, **312**, 43-54.
- Eisenberg BL, Pipas JM (2012). Gastrointestinal stromal tumor-background, pathology, treatment. *Hematol Oncol Clin North Am*, **26**, 1239-59.
- Foster KG, Fingar DC (2010). Mammalian target of rapamycin (mTOR): conducting the cellular signaling symphony. *J Biol Chem*, **285**, 14071-7.
- George S, Blay JY, Casali PG, et al (2009). Clinical evaluation of continuous daily dosing of sunitinib malate in patients with advanced gastrointestinal stromal tumour after imatinib failure. *Eur J Cancer*, **45**, 1959-68.
- Gnant M (2012). Overcoming endocrine resistance in breast cancer: importance of mTOR inhibition. *Expert Rev Anticancer Ther*, **12**, 1579-89.
- Grabinski N, Ewald F, Hofmann BT, et al (2012). Combined targeting of AKT and mTOR synergistically inhibits proliferation of hepatocellular carcinoma cells. *Mol Cancer*, **11**, 85.
- Grover S, Ashley SW, Raut CP (2012). Small intestine gastrointestinal stromal tumors. *Curr Opin Gastroenterol*, **228**, 113-23.
- Jiang J, Jin MS, Suo J, et al (2012). Evaluation of malignancy using Ki-67, p53, EGFR and COX-2 expressions in gastrointestinal stromal tumors. *World J Gastroenterol*, **18**, 2569-75.
- Joensuu H (2008). Risk stratification of patients diagnosed with gastrointestinal stromal tumor. *Hum Pathol*, **39**, 1411-9.
- Kee D, Zalberg JR (2012). Current and emerging strategies for the management of imatinib-refractory advanced gastrointestinal stromal tumors. *Ther Adv Med Oncol*, **4**, 255-70.
- Padilla D, Menéndez P, García M, et al (2008). Immunohistochemical expression of epidermal growth factor and its prognostic value for gastrointestinal stromal tumors. *Rev Esp Enferm Dig*, **100**, 752-7.
- Shirin H, Kravtsov V, Shahmurov M, et al (2007). The cyclin-dependent kinase inhibitor, p27, has no correlation with the malignant potential of GIST. *Digestion*, **75**, 4-9.
- Tamguney T, Stokoe D (2007). New insights into PTEN. *J Cell Sci*, **120**, 4071-9.
- Van der Meel R, Oliveira S, Altintas I, et al (2012). Tumor-targeted Nanobullets: Anti-EGFR nanobody-liposomes loaded with anti-IGF-1R kinase inhibitor for cancer treatment. *J Control Release*, **159**, 281-9.
- Wang CD, Huang JG, Gao X, et al (2010). Fangchinoline induced G1/S arrest by modulating expression of p27, PCNA, and cyclin D in human prostate carcinoma cancer PC3 cells and tumor xenograft. *Biosci Biotech Bioch*, **74**, 488-93.
- Xu JL, Wang ZW, Hu LM, et al (2012). Genetic variants in the PI3K/PTEN/AKT/mTOR pathway predict platinum-based chemotherapy response of advanced non-small cell lung cancers in a Chinese population. *Asian Pac J Cancer Prev*, **13**, 2157-62.
- Zhang H, Bajrazewski N, Wu E, et al (2007). PDGFRs are critical for PI3K/Akt activation and negatively regulated by mTOR. *J CLIN INVEST*, **117**, 730-8.